



# Graduate Neuroanatomy

## Laboratory Guide Fall 2012

**Offered and Coordinated by the Department of Neurobiology and Anatomy  
The University of Texas Health Science Center at Houston. This course guide was  
adapted from the Medical Neuroscience Laboratory Guide. Nachum Dafny, Ph.D.,  
Course Director; Vahn Lewis, Ph.D., Laboratory Coordinator.**

Online teaching materials are available at

<https://oac22.hsc.uth.tmc.edu/courses/neuroanatomy/>

Other course information available at

<http://openwetware.org/wiki/Beauchamp:GraduateNeuroanatomy>

## Table of Contents

Overview of the Nervous System .....	2
Laboratory Exercise #1: External Anatomy of the Brain .....	18
Laboratory Exercise #2: Internal Organization of the Brain .....	34
Laboratory Exercise #3: Ventricles, Blood Vessels, and External Surface of the Brain Stem .....	41
Laboratory Exercise #4: Spinal Cord: External and Internal Anatomy and Introduction to Somatosensory Pathways .....	49
Laboratory Exercise #5: Somatosensory, Viscerosensory and Spinocerebellar Pathways .....	59
Laboratory Exercise #6: Auditory, Vestibular, Gustatory and Olfactory Systems .....	76
Laboratory Exercise #7: Visual System and Oculomotor Control .....	86
Laboratory Exercise #8: Higher Motor Function.....	101
Laboratory Exercise #9: Descending Pathways to the Spinal Cord.....	116
Laboratory Exercise #10: Cranial Nerve Nuclei and Brainstem Circulation .....	124
Laboratory Exercise #11 Part A: The Limbic System .....	152
Laboratory Exercise #11 Part B: The Hypothalamus .....	157

# Overview of the Nervous System

Nachum Dafny, Ph.D.

The human nervous system is divided into the central nervous system (CNS) and the peripheral nervous system (PNS). The CNS, in turn, is divided into the brain and the spinal cord, which lie in the cranial cavity of the skull and the vertebral canal, respectively. The CNS and the PNS, acting in concert, integrate sensory information and control motor and cognitive functions.

## The Central Nervous System (CNS)

The adult human brain weighs between 1200 to 1500g and contains about one trillion cells. It occupies a volume of about 1400cc - approximately 2% of the total body weight, and receives 20% of the blood, oxygen, and calories supplied to the body. The adult spinal cord is approximately 40 to 50cm long and occupies about 150cc. The brain and the spinal cord arise in early development from the neural tube, which expands in the front of the embryo to form the main three primary brain divisions: the prosencephalon (forebrain), mesencephalon (midbrain), and rhombencephalon (hindbrain) (Figure 1A). These three vesicles further differentiate into five subdivisions: telencephalon, diencephalon, mesencephalon, metencephalon, and the myelencephalon (Figure 1B). The mesencephalon, metencephalon, and the myelencephalon comprise the brain stem.

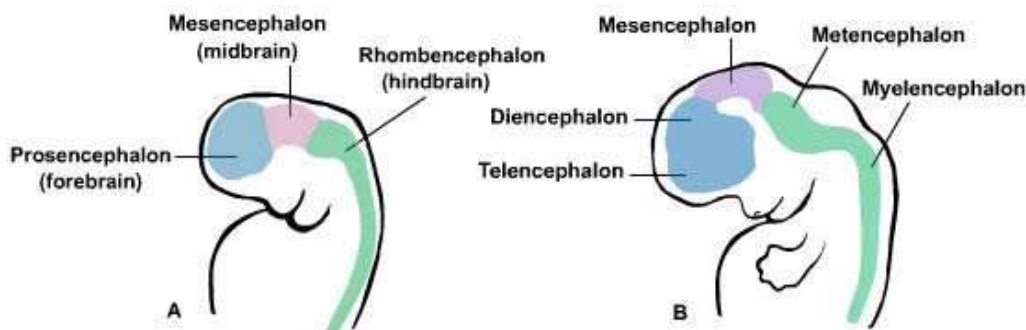


Figure 1. (Click to enlarge) Schematic lateral view drawing of human embryo at the beginning of the 3rd (A) and 5th (B) week of gestation.

### Telencephalon

The telencephalon includes the cerebral cortex (cortex is the outer layer of the brain) which represents the highest level of neuronal organization and function (Figures 2A and 2B). The cerebral cortex consists of various types of cortices (such as the olfactory bulbs, Figure 1.2B) as well as closely related subcortical structures such as the caudate nucleus, putamen, globus, amygdala and the hippocampal formation (Figure 2C).

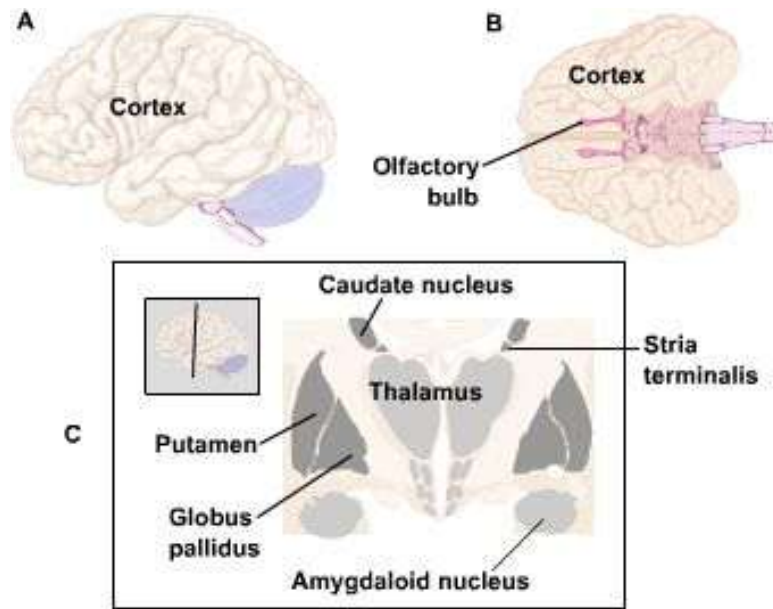


Figure 2. (Click to enlarge) Lateral (A) and ventral (B) schematic drawing of the cerebral cortex. In C, drawing of subcortical structures.

### Diencephalon

The diencephalon consists of a complex collection of nuclei lying symmetrically on either side of the midline. The diencephalon includes the thalamus, hypothalamus, epithalamus and subthalamus (Figure 3).

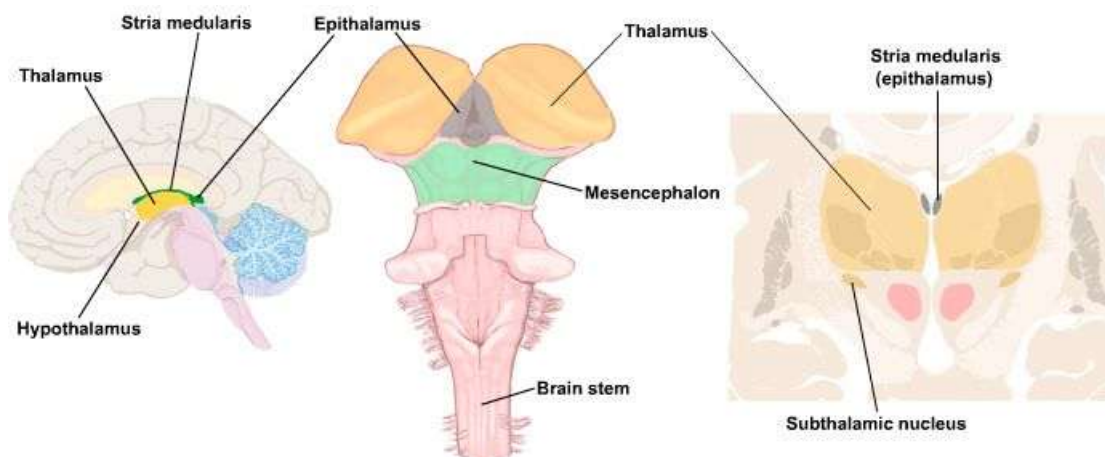


Figure 3. (Click to enlarge) Shows the main diencephalon nuclei.

### Mesencephalon

The mesencephalon (or midbrain) consists of several structures around the cerebral aqueduct such as the periaqueductal gray (or central gray), the mesencephalic reticular formation, the substantia nigra, the red nucleus (Figure 4), the superior and inferior colliculi, the cerebral peduncles, some cranial nerve nuclei, and the projection of sensory and motor pathways.

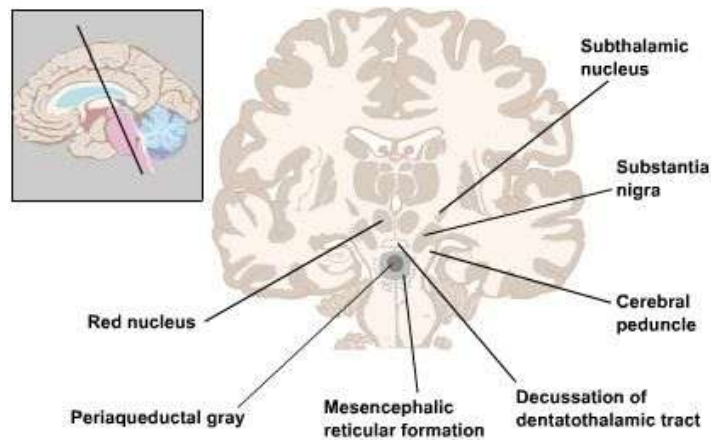


Figure 4. (Click to enlarge) Schematic drawing of subcortical diencephalic and mesencephalic structures.

### Metencephalon

The metencephalon includes the pons and the cerebellum. The myelencephalon (spinal cord-like) includes the open and closed medulla, sensory and motor nuclei, projection of sensory and motor pathways, and some cranial nerve nuclei.

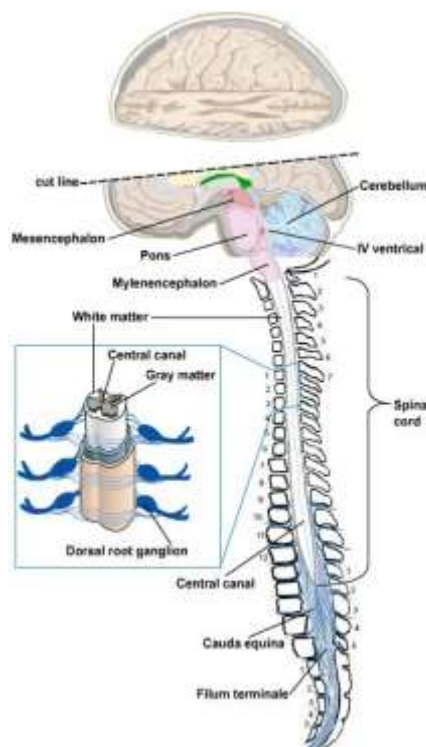

Figure 5. (Click to enlarge) Schematic lateral view of the metencephalon and a spinal cord section with ventral and dorsal root fibers, and dorsal root ganglions.

The caudal end of the myelencephalon develops into the spinal cord. The spinal cord is an elongated cylindrical structure lying within the vertebral canal, which includes the central canal and the surrounding gray matter. The gray matter is composed of neurons and their supporting cells and is enclosed by the white matter that is composed of a dense layer of ascending and descending nerve fibers. The spinal cord is an essential link between the peripheral nervous system and the brain; it

conveys sensory information originating from different external and internal sites via 31 pairs of spinal nerves (Figure 5). These nerves make synaptic connections in the spinal cord or in the medulla oblongata and ascend to subcortical nuclei.

The central nervous system, which includes the spinal cord and the brain, is the most protected organ in the human body. It is protected from the external environment by three barriers: skull, meninges, and CSF.

The meninges are composed by three fibrous connective tissues (Figure.6). The most external is a dense collagenous connective tissue envelope known as the dura mater (Latin for “hard mother”). The second, or the intermediated membrane, is a delicate non-vascular membrane of fine collagenous layer of reticular fibers forming a web-like membrane, known as the arachnoid (Greek for “spider”). It is separated from the inner pia layer by subarachnoid space, which is filled with cerebrospinal fluid. The inner most delicate connective tissue membrane of collagenous is the pia mater, a thin translucent elastic membrane adherent to the surface of the brain and the spinal cord. Blood vessels located on the surface of the brain and the spinal cord are found on top of the pia matter. The meninges are subject to viral and bacterial infection known as meningitis, a life-threatening condition that requires immediate medical treatment.

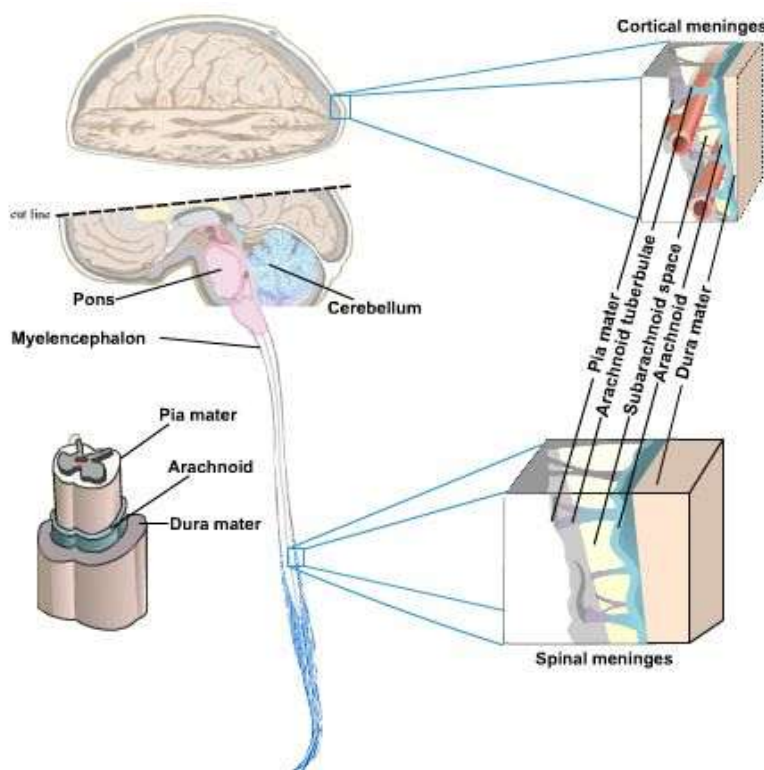


Figure 6. (Click to enlarge) Schematic drawing of the brain and spinal cord meninges.

The space between the skull and the dura is known as the epidural space. The space between the dura and the arachnoid is known as the subdural space. The space between the arachnoid and the pia is known as the subarachnoid space. In this space, there is a clear liquid known as the cerebrospinal fluid (CSF). The CSF serves to support the CNS, and to cushion as well as protect it from physical shocks and trauma. The CSF is produced by the choroid plexus which is composed of a specialized secretory ependymal layer located in the ventricular system.



The **ventricular system** is a derivative of the primitive embryonic neural canal. This system is an interconnected series of spaces within the brain containing the CSF (Figure 7).

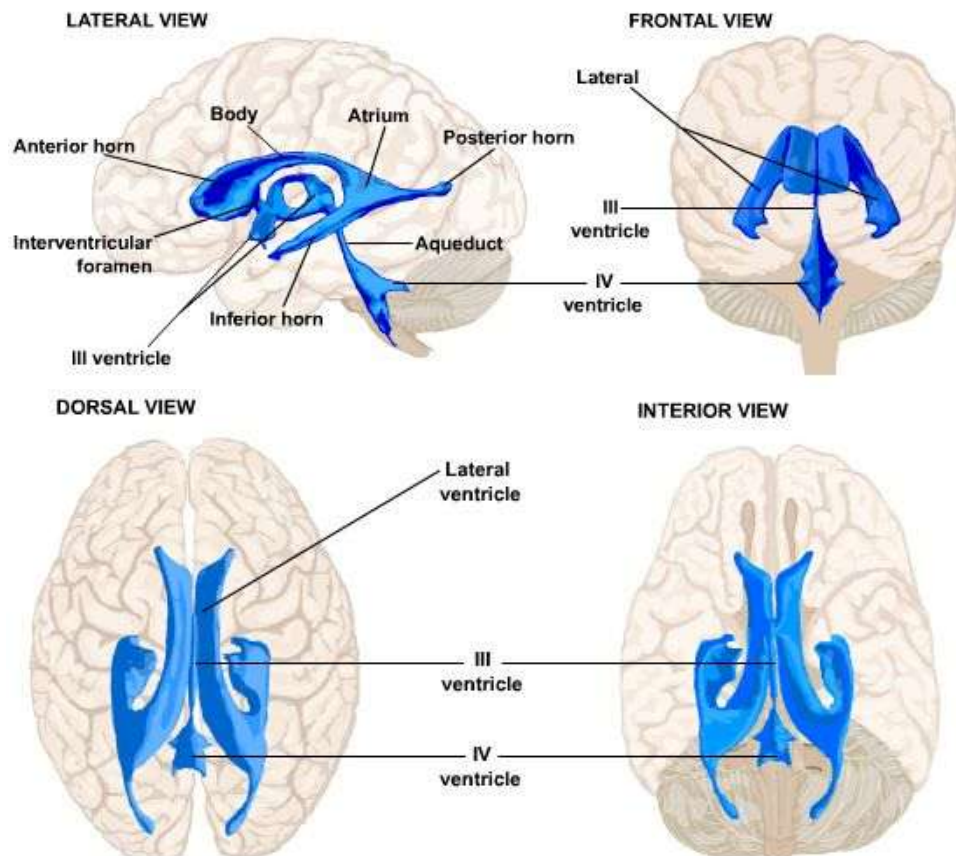


Figure 7. (Click to enlarge) Schematic drawing of ventricular system in four different angles.

In general, the CNS can be divided into three main functional components: the sensory system, the motor system, and homeostasis and higher brain functions. The sensory system consists of the somatosensory, viscerosensory, auditory, vestibular, olfactory, gustatory, and visual systems. The motor system consists of motor units, and the somatic (skeletal muscle) system, the spinal reflexes, the visceral (autonomic) system, the cerebellum, several subcortical and cortical sites, as well as the brain stem ocular motor control system. The homeostasis and higher functional system includes the hypothalamus, cortical areas involved in motivation, insight, personality, language, imagination, creativity, thinking, judgment, mental processing, and subcortical areas involved in learning, thought, consciousness, memory, attention, emotional state, sleep and arousal cycles.

## The Cerebral Hemispheres

The telencephalon is the largest and most obvious parts of the human brain are the cerebral hemispheres. The cerebrum has an outer layer - the cortex, which is composed of neurons and their supporting cells, and in fresh brain, has a gray color thus called the gray matter. Under the gray matter there is the white matter, which is composed of myelinated ascending and descending nerve fibers, and in fresh brain have a white color. Embedded deep within the white matter are aggregation of neurons exhibiting gray color and known as subcortical nuclei. The cerebral hemispheres are partially separate from each other along the midline by the interhemispheric fissure (deep groove) the falx cerebri (Figure 8A); posteriorly, there is a transverse fissure that separates the cerebral hemisphere from the cerebellum, and contains the tentorium cerebellum. The hemispheres are connected by a large C-shaped fiber bundle, the corpus callosum, which carries information between the two hemispheres.

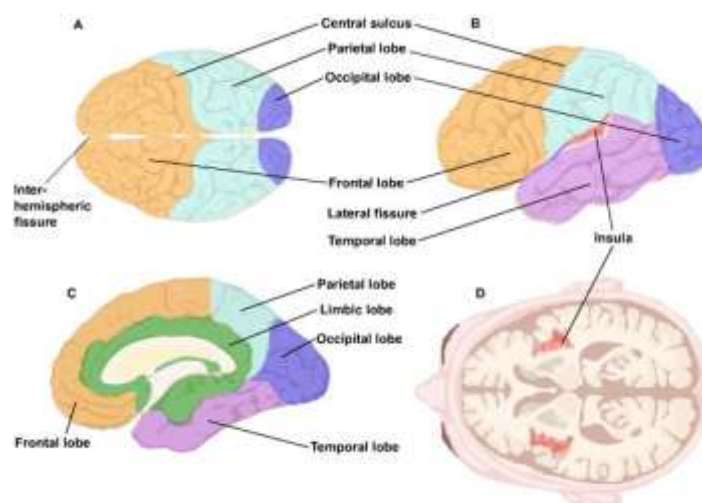


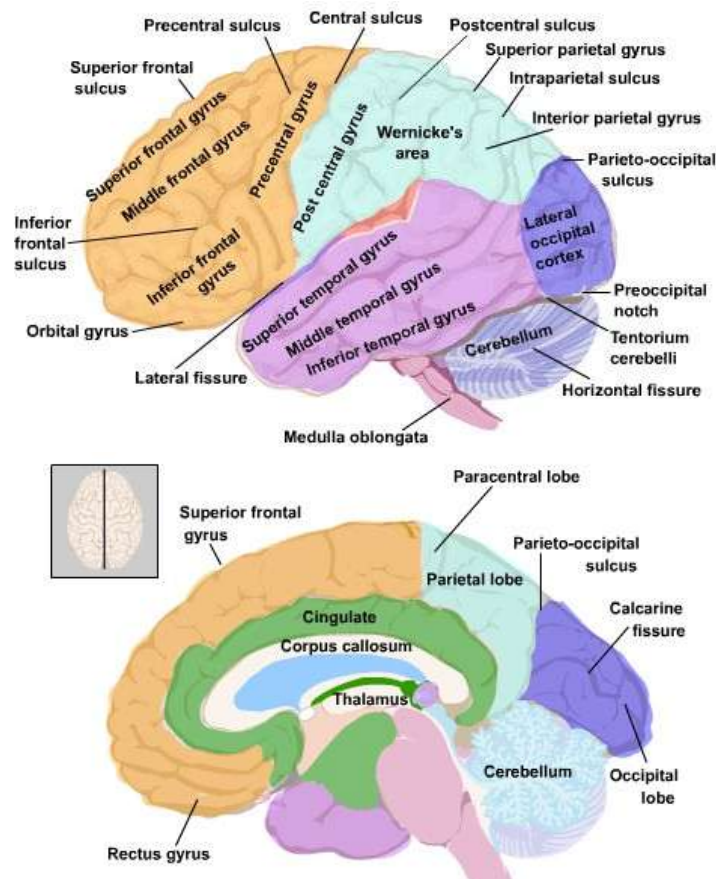
Figure 8. (Click to enlarge) Schematic drawing of six cortical lobes: Dorsal view (A), Lateral view (B), Mid-sagittal section showing the limbic lobe (in green) (C), and Horizontal section showing the insular cortex (D).

For descriptive purposes each cerebral hemisphere can be divided into six lobes. Four of these lobes are named according to the overlying bones of the skull as follows: frontal, parietal, occipital and temporal (Figures 8A and 8B), the fifth one is located internally to the lateral sulcus – the insular lobes (Figure 8B and 8D), and the sixth lobe is the limbic lobe (Figure 8C) which contains the limbic system nuclei. Neither the insular lobe nor the limbic lobe is a true lobe. Although the boundaries of the various lobes are somewhat arbitrary, the cortical areas in each lobe are histologically distinctive.

The surface of the cerebral cortex is highly convoluted with folds (gyri), separate from each other by elongate grooves (sulci). These convolutions allow for the expansion of the cortical surface area without increasing the size of the brain. On the lateral surface of the cerebral hemisphere there are two major deep grooves-sulci (or fissure), the lateral fissure (of Sylvian) and the central sulci (of Rolando), these sulci provide landmarks for topographical orientation (Figure 9A). The central sulcus separates the frontal lobe from the parietal lobe and runs from the superior margin of the hemisphere near its midpoint obliquely downward and forward until it nearly meets the lateral fissure (Figures 8A and 8B). The lateral fissure, separating the frontal and parietal lobes from the temporal lobe, begins inferiorly in the basal surface of the brain and extends laterally posteriorly and upward, separating the frontal and parietal lobes from the temporal lobe (Figure 9A). The frontal lobe is the portion which is rostral to the



central sulcus and above the lateral fissure, and it occupies the anterior one third of the hemispheres (Figures 8 and 9). The boundaries of the parietal lobe are not precise, except for its rostral border – the central sulcus. The occipital lobe is the portion which is caudal to the parietal lobe (Figures 8 and 9). Along the lateral surface of the hemisphere, an imaginary line connecting the tip of the parietal-occipital sulcus and the preoccipital notch (Figure 9A); separate the parietal lobe from the occipital lobe. On the medial surface of the hemisphere (Figure 9B), parieto-occipital sulcus forms the rostral boundary of the parietal lobe. The temporal lobe lies ventral to the lateral sulcus, and on its lateral surface, it displays three diagonal oriented convolutions-the superior, middle, and inferior temporal gyri (Figure 9A). The insula lies in the depths of the lateral sulcus. It has a triangular cortical area with gyri and sulci (Figures 8B & 2D, and Figure 9A). The limbic lobe consists of several cortical and subcortical areas (Figure 9B).



Figures 9A and 9B. (Click to enlarge) Lateral schematic drawing of the different cortices, sulci and gyri (A) and mid-sagittal drawing emphasizes the limbic lobe (in green) (B).

The cerebral cortex is a functionally organized organ. A functional organized system is a set of neurons linked together to convey a specific type(s) of information to accomplish a particular task(s). It is possible to identify on the cerebral cortex primary sensory areas, secondary sensory areas, primary motor area, premotor area, supplementary motor area and association areas, which are devoted to the integration of motor and sensory information, intellectual activity, thinking and comprehension, execution of language, memory storage and recall.

The frontal lobe is the largest of all the brain lobes and is comprised of four gyri, precentral gyrus that parallels to the central sulcus, and three horizontal gyri: the superior, middle, and inferior frontal gyri. The inferior frontal gyrus is comprised of three parts: the orbital, the triangular and opercular. The term opercular refers to the “lips of the lateral fissure. Finally, the straight gyrus (gyrus rectus) and the orbital gyri form the base of the frontal lobe (Figure 9B). Four general functional areas are in the frontal lobe. They are the primary motor cortex, where all parts of the body are represented, the premotor and supplementary motor areas. A region concerned with the motor mechanisms of speech formulation comprised of the opercular and triangular parts of the inferior frontal gyrus are known as Broca’s speech area, and the remainder of the prefrontal cortex is involved in mental activity, personality insight, foresight, and reward. The orbital portion of the prefrontal cortex is important in the appropriate switching between mental sets and the regulations of emotion.

The parietal lobe is comprised of three gyri: postcentral gyrus, superior and inferior parietal gyri (Figure 9A). The postcentral gyrus is immediately behind the central sulcus which forms its anterior boundary. The postcentral gyrus comprises the primary somatosensory cortex which is concerned with somatosensory reception, integration and processing sensory information from the surface of the body and from the viscera, and is important for the formulation of perception. Caudal to the postcentral gyrus is the inferior parietal gyrus. The intraparietal sulcus separates the posterior parietal gyrus from the inferior parietal gyrus. The inferior parietal gyrus represents the cortical association area which integrates and processes sensory information from multiple modalities such as auditory and visual information. The inferior parietal gyrus, which is known as Wernicke’s area, is also important for language and reading skills, whereas the superior parietal gyrus is concerned with body image and spatial orientations.

The temporal lobe is formed by three obliquely oriented gyri: the superior, middle, and inferior temporal gyri (Figure 9A). Inferomedial to the inferior temporal gyrus are the occipitotemporal and the parahippocampal gyri, which are separated by the collateral sulcus. The upper surface of the superior temporal gyrus, which extends into the lateral fissure, is called the transverse temporal gyrus (of Heschl) and is the primary auditory cortex. The caudal part of the superior temporal gyrus, which extends up to the parietal cortex, forms part of Wernicke’s area. Wernicke’s area is concerned, in part, with processing the auditory information and is important in the comprehension of language. The inferior part of the temporal lobe (i.e., the occipitotemporal gyri) is involved in visual and cognitive processing.

More medially is the parahippocampal gyrus, which is involved in learning and memory. Portions of the frontal, parietal, and temporal lobes, which are adjacent to the lateral sulcus and overlie the insular cortex, are known as the operculum. The inferomedial surface of the temporal lobe is made up of the uncus and the parahippocampal gyrus medially. The inferior surface of the temporal lobe rests on the tentorium cerebelli.

The occipital lobe is the most caudal part of the brain, lies on the tentorium cerebelli (Figure 9A) and is comprised of several irregular lateral gyri. On its medial surface, there is a prominent fissure – the calcarine fissure and parieto-occipital sulcus. The calcarine fissure (sulcus) and the parieto-occipital sulcus also define a cortical region known as the cuneus. The cuneus sulcus divides the occipital lobe into the cuneus dorsally and ventrally into the lingual gyrus. The occipital lobe contains the primary and higher-order visual cortex.

The insula lobe is located deep inside the lateral fissure and can be seen only when the temporal and the frontal lobes are separated. The insula is characterized by several long gyri and sulci, the gyri breves and gyri longi. There is some evidence that the insular cortical areas are involved in nociception and regulation of autonomic function (Figures 8B and 8D).

The limbic lobe is not a true lobe and is comprised of several cortical regions such as the cingulate and parahippocampal gyri, some subcortical areas like the hippocampus, amygdala, septum, and other areas with their respective ascending and descending connections (Figures 8C and 9B). The limbic lobe is involved in memory and learning, drive related behavior, and emotional function.

There are subcortical areas in the telencephalon like the basal ganglia and the amygdaloid nucleus complex. The corpus callosum is a collection of nerve fibers which connect the two hemispheres. The corpus callosum is divided into rostrum (head), body, the most rostrally part is the genu (knee) with connecting the rostrum and the body, and the splenium at the caudal extremity (Figure 10). Behavioral studies have shown that the corpus callosum play an important role in transferring information from one hemisphere to the other.

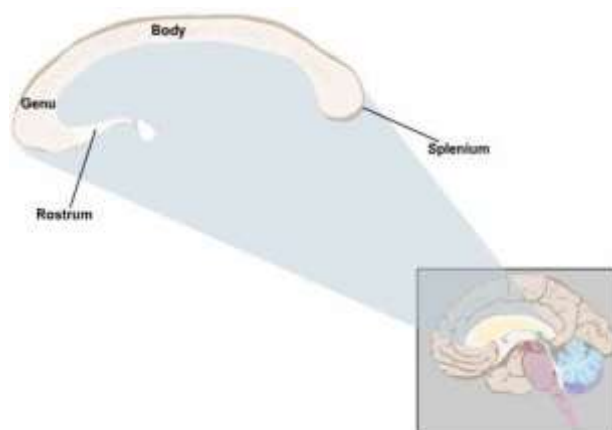


Figure 10. (Click to enlarge) The corpus callosum and its different parts.

## The Diencephalon

---

The second major derivative of the prosencephalon is the diencephalon. The diencephalon is the most rostral structure of the brain stem; it is embedded in the inferior aspect of the cerebrum. The posterior commissure is the junctional landmark between the diencephalon and the mesencephalon. Caudally, the diencephalon is continuous with the tegmentum of the midbrain. During development the diencephalon differentiates into four regions: thalamus, hypothalamus, subthalamus and epithalamus (Figure 11). The epithalamus comprises the stria medullaris habenular trigone, pineal gland and the posterior commissure (Figure 11).

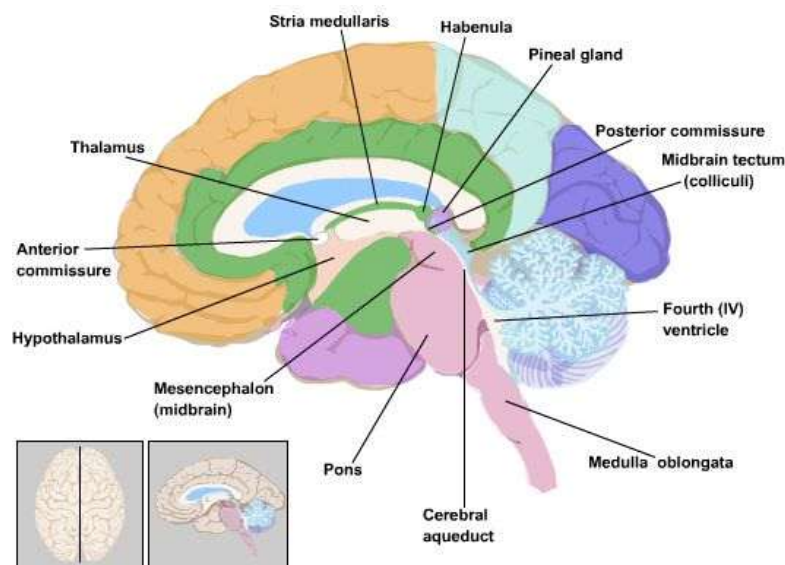


Figure 11. (Click to enlarge) Midsagittal drawing showing the main structures of the diencephalon.

## The Brain Stem

The brain stem consists of mesencephalon (midbrain), metencephalon, and myelencephalon. The metencephalon and myelencephalon together compose the rhombencephalon (hindbrain), which divides into pons, and medulla oblongata (Figure 12).

### Mesencephalon

Mesencephalon (midbrain) is continuous with the diencephalons rostrally and with the pons caudally. The midbrain is the smallest part of the brain stem, being about 2 cm in length. It consists of a tectum posteriorly, a tegmentum inferiorly, and a base anteriorly. The tectum forms the roof of the cerebral aqueduct, which connects the third ventricle with the fourth ventricle and the tegmentum its floor. The base of the midbrain consists of the cerebral peduncle, which contain nerve fibers descending from the cerebral cortex. The nuclei of the 3rd (oculomotor), the 4th (trochlear) and part of the 5th (trigeminal) are located in the midbrain tegmentum. The red nucleus and the substantia nigra, two prominent nuclei, are also found in the midbrain tegmentum. The midbrain tectum is formed by two pairs of rounded structures: the superior and inferior colliculi. The superior and inferior colliculi (Figure 12) are involved in visual and auditory functions respectively.

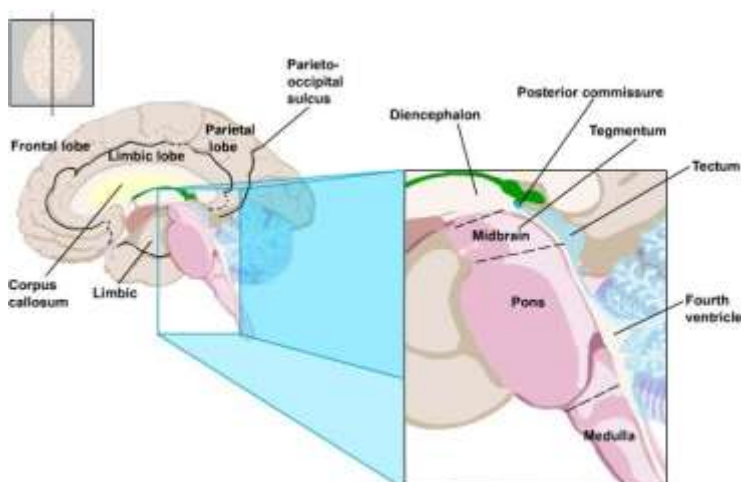


Figure 12. (Click to enlarge) Midsagittal drawing of the brain stem.

### Pons

The pons is continuous with the midbrain and is composed of two parts, the pontine tegmentum (located internally) and the basilar pons. At the level of the pons, the cerebral aqueduct has expanded to form the fourth ventricle (Figure 12). The cerebellum is situated posterior to the pons and forms part of the roof (tectum) of the fourth ventricle. The pons contains nuclei that receive axons from various cortical areas. Projections from the axons of these pontine neurons form large transverse fiber bundles which traverse the pons and ascend to the contralateral cerebellum via the middle cerebellar peduncles. Also, within the pons base and tegmentum are longitudinally ascending and descending fibers. The nuclei of the 5th (trigeminal), 6th (abducens), 7th (facial) and the 8th (vestibulocochlear) nerves are located in the pons tegmentum.

### Medulla Oblongata

Medulla Oblongata (myelencephalon is also known as the medulla). The medulla lies between the pons rostrally and the spinal cord caudally. It is continuous with the spinal cord just above to foramen magnum and the first spinal nerve. The posterior surface of the medulla forms the caudal half of the fourth ventricle floor and the cerebellum, its roof (Figure 12). The base of the medulla is formed by the pyramidal-descending fibers from the cerebral cortex. The medulla tegmentum contains ascending and descending fibers and nuclei from the 9th (glossopharyngeal), 10th (vagus), 11th (accessory) and the 12th (hypoglossal) nerves. The corticospinal fibers (pyramid) are alongside the anterior median fissure, and decussate (cross the midline) to the contralateral side on their way to the spinal cord. Other prominent structures in the medulla are the inferior olive, and the inferior cerebellar peduncle. The medulla contains nuclei which regulate respiration, swallowing, sweating, gastric secretion, cardiac, and vasomotor activity.

### Arterial Blood Supply

The arterial blood supply to the brain is derived from two arterial systems: the carotid system and the vertebrobasilar system. A series of anastomotic channels lying at the base of the brain, known as the circle of Willis, permits communication between these two systems (Figure 13).

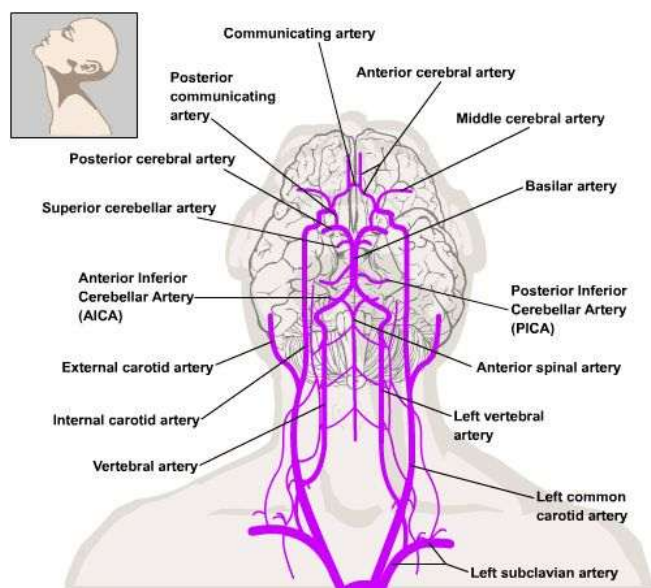


Figure 13. (Click to enlarge) Schematic drawing showing the main arterial blood supplies to the brain.

The arterial blood supply to the spinal cord is derived from two branches of vertebral artery, the anterior and two posterior spinal arteries which run the length of the spinal cord and form an irregular plexus around it (Figure 14).

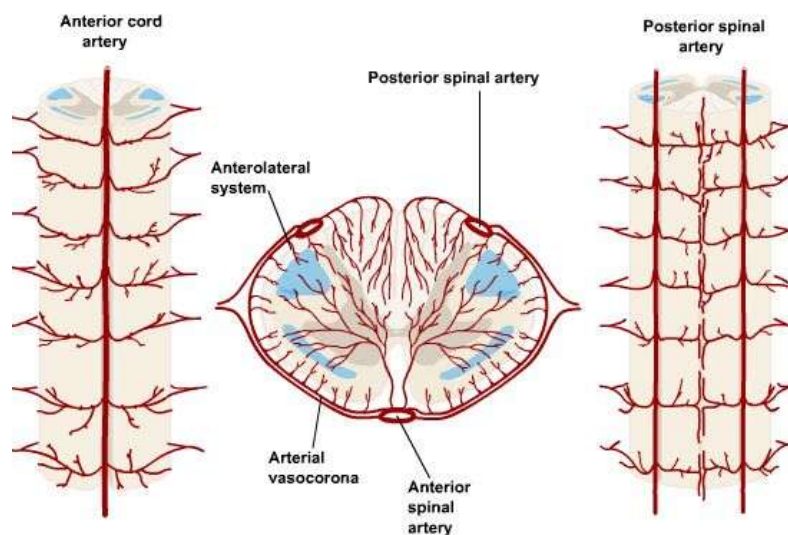


Figure 14. (Click to enlarge) Schematic drawing of the spinal cord arterial blood supply.

### The Peripheral Nervous System (PNS)

The PNS includes 31 pairs of spinal nerves, 12 pairs of cranial nerves, the autonomic nervous system and the ganglia (groups of nerve cells outside the CNS) associated with them. Also included in the PNS are the sensory receptor organs. The receptor organs are scattered in all parts of the body, sense and perceive changes from external and internal organs, then transform this information to electrical signals, which are carried via an extensive nervous network to the CNS (Figure 15). The cranial and spinal nerves contain nerve fibers that conduct information to-afferent-(Latin for carry toward) and from-efferent (Latin for carry away) the CNS. Afferent fibers convey sensory information from sensory



receptors in the skin, mucous membranes, and internal organs and from the eye, ear, nose and mouth to the CNS; the efferent fibers convey signals from cortical and subcortical centers to the spinal cord and from there to the muscle or autonomic ganglia that innervate the visceral organs. The afferent (sensory) fibers enter the spinal cord via the dorsal (posterior) root, and the efferent (motor) fibers exit the spinal cord via the ventral (anterior) root. The spinal nerve is formed by the joining of the dorsal and the ventral roots. The cranial nerves leave the skull and the spinal cord nerves leave the vertebrae through openings in the bone called foramina (Latin for opening).

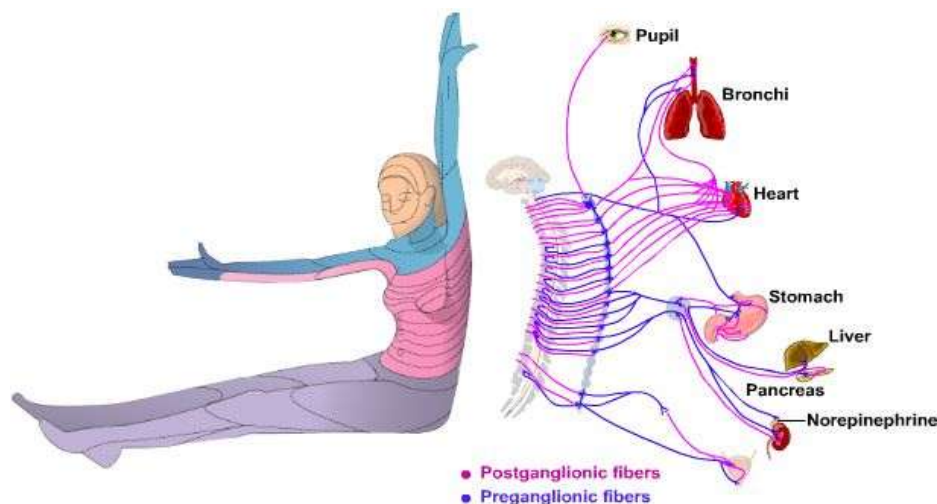


Figure 15. (Click to enlarge) Schematic drawing of the peripheral nervous system.

The PNS is divided into two systems: the visceral system and the somatic system. The visceral system is also known as the autonomic system. The autonomic nervous system (ANS) is often considered a separate entity; although composed partially in the PNS and partially in the CNS, it interfaces between the PNS and the CNS. The primary function of the ANS is to regulate and control unconscious functions including visceral, smooth muscle, cardiac muscle, vessels, and glandular function (Figure 16). The ANS can be divided into three subdivisions:

1. The sympathetic (or the thoracolumbar) subdivision associated with neurons located in the spinal gray between the thoracic and the upper lumbar levels;
2. The parasympathetic (or craniosacral) subdivision is associated with the 3rd, 7th, 9th and the 10th cranial nerves as well as with the 2nd, 3rd, and 4th sacral nerves;
3. The enteric subdivision is a complex neuronal network within the walls of the gastrointestinal system and contains more neurons than the spinal cord. The visceral (autonomic) system regulates the internal organs outside the realm of conscious control. The PNS component of the somatic system includes the sensory receptors and the neurons innervating them and their nerve fibers entering the spinal cord. The visceral and the somatic nervous system are primarily concerned with their own functions, but also work in harmony with other aspects of the nervous system.

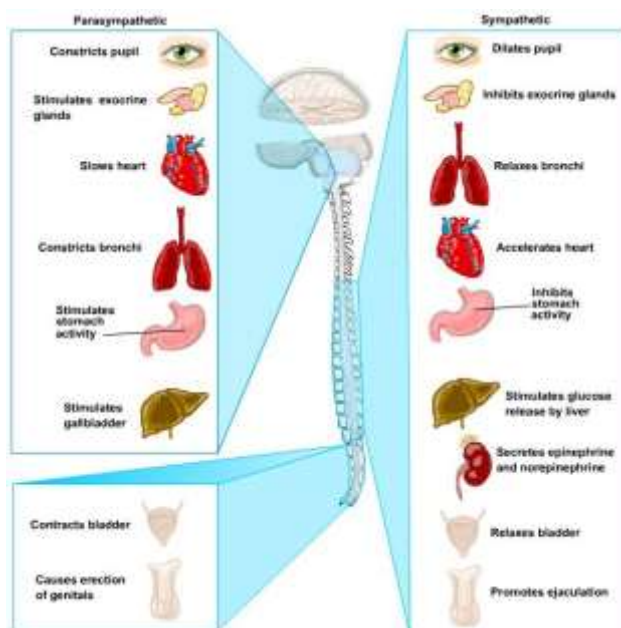


Figure 16. (Click to enlarge) Schematic drawing showing the autonomic nervous system. C, T, L and S indicate the cervical, thoracic, lumbar and sacral levels of the spinal cord, respectively. III, VII, IX, X indicate the 3rd, 7th, 9th and 10th cranial nerves respectively.

## Orientation to the Central Nervous System

In this section you will be introduced to representative sections through the human CNS. They will acquaint you with prominent structures that will help you to recognize the level and orientation of the section and provide landmarks for locating nuclei and tracts involved in sensory and motor functions. Directional terms are used in describing the locations of structures in the CNS.

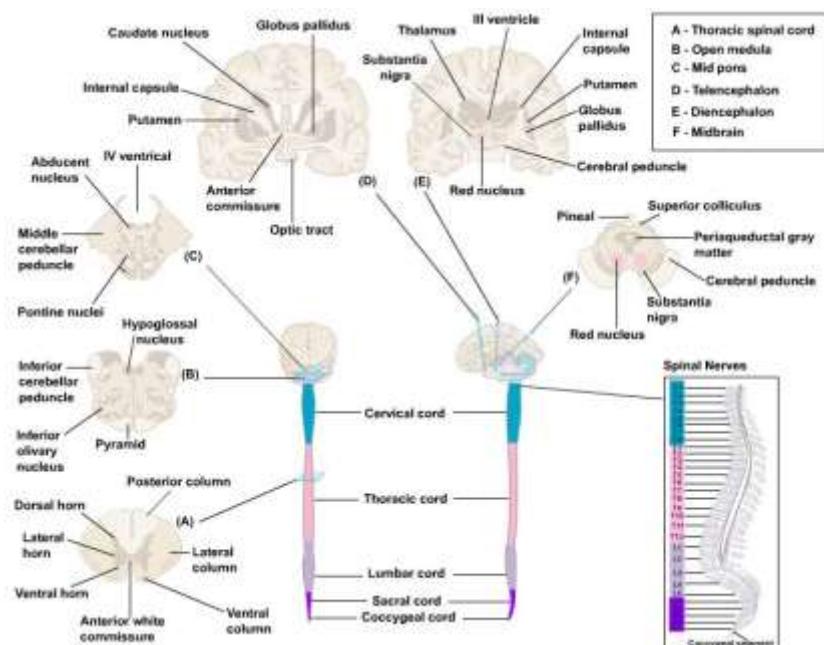


Figure 17. (Click to enlarge) Orientation of the central nervous system of the spinal cord and different brain sections.

Keep in mind that certain terms were developed to describe the nervous system of quadrupeds and may have a slightly different meaning when applied to bipeds. For example, the ventral surface of the quadruped spinal cord is comparable to the anterior surface of the biped (Figure 18). In the following descriptions, the terms are applied to a standing human. The terms rostral and anterior refer to a direction towards the face/nose. The terms caudal and posterior refer to a direction towards the buttocks/tail. The terms inferior and superior generally refer to spatial relationships in a vertical direction (Figure 18). A coronal section is parallel to the vertical plane and a midcoronal section would divide the head into anterior and posterior halves (Figure 19). The sagittal section is also parallel to the vertical plane, but a midsagittal section would divide the head into right and left halves. The horizontal (axial) section is parallel to the horizontal plane and a mid horizontal section would divide the head into superior and inferior halves. Transverse or cross sections of the spinal cord of humans are taken in a plane perpendicular to the vertical, i.e., in the horizontal plane of the head. Most electromagnetic imaging techniques produce images of the brain in the coronal, horizontal (axial) and sagittal planes. The representative sections are transverse sections through the spinal cord and brain stem and coronal sections through the telencephalon and diencephalon (Figure 17).

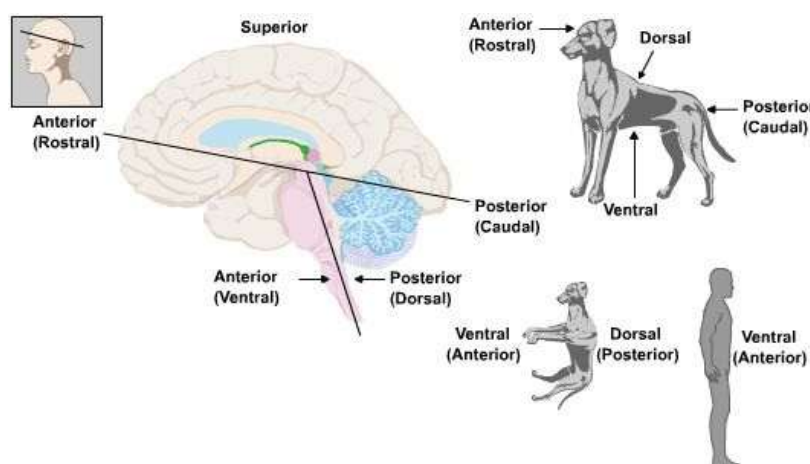


Figure 18. (Click to enlarge) A schematic illustration showing the brain direction.

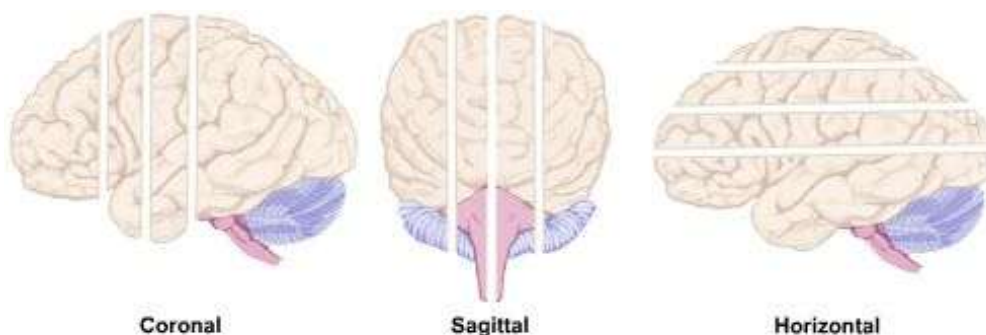


Figure 19. (Click to enlarge) A schematic illustration showing the three planes of brain section.

### Transverse Section through the Spinal Cord

This section was taken at the level of the thoracic spinal cord (Figure 17A). The spinal cord neuron (gray matter) form a central core taking a butterfly configuration that is surrounded by nerve fibers (white matter). In the left and right halves of the spinal cord, the gray matter is organized into a dorsal horn and ventral horn with the intermediate gray located between them. In the thoracic spinal cord, which is illustrated in this figure, a lateral horn extends laterally from the intermediate gray (Figure 17A). The spinal cord white matter is subdivided into the posterior white column, the anterior white column and the lateral white column. The anterior white commissure joins the two halves of the spinal cord and is located ventral to the intermediate gray. The dorsal root fibers enter the spinal cord at the dorsolateral sulcus and the fibers of the ventral root fibers exit the spinal cord in numerous fine bundles through the ventral funiculus (see Figures 1-5).

### Transverse Section through the Medulla

(Figure 17B) This is a section taken at the level of the upper medulla. Landmark structures include the fourth ventricle, hypoglossal nucleus, inferior cerebellar peduncle, inferior olivary complex and the pyramids. As in the spinal cord section, the fiber tracts, the inferior cerebellar peduncle and pyramids, appear dark in this section while the nuclei in the inferior olivary complex appear light.

### Transverse Section through the Pons

(Figure 17C) This is a section taken at the level of the mid pons. Landmark structures include the fourth ventricle, the pons tegmentum, which includes the abducens nuclei; the pons base, which includes the corticofugal fibers and pontine nuclei; and the middle cerebellar peduncles.

### Coronal Section through the Rostral Telencephalon

(Figure 17D) This is a section taken at the level of the decussation of the anterior commissure. Landmark structures include the head of the caudate nucleus, the anterior limb of the internal capsule, the globus pallidus and putamen (all-important in controlling motor functions). The anterior commissure, a fiber bundle connecting the right and left frontal lobes, can be seen decussating (crossing the midline). The corpus callosum forms a thick band of decussating nerve fibers located above the lateral ventricles. Below the telencephalon afferent nerve fibers from each eye decussate in the optic chiasm and join uncrossed fibers to form the optic tract.

### Coronal Section through the Midbrain-Diencephalon Junction

(Figure 17E) This is a section taken at the level junction of the midbrain with the diencephalon. Notice that the plane of section differs from those of previously viewed sections. At this level, a landmark structure of the diencephalon is the thalamus, which surrounds the third ventricle. The posterior limb of the internal capsule separates the thalamus from the surrounding telencephalic structures, i.e., the globus pallidus and putamen. Lateral to the putamen is the insula while more dorsomedially the corpus callosum overlies the cavities of the lateral ventricles. Below the third ventricle are the red nucleus, substantia nigra and crus cerebri of the midbrain, which are the continuation of the internal capsule.

### Section through the Midbrain

(Figure 17F) This section aims to show the main midbrain nuclei which include the tectum (superior colliculi) the periaqueductal gray, the red nuclei, substantia nigra and the cerebral peduncles.

# Laboratory Exercise #1:

## External Anatomy of the Brain

Lecturers: Pramod Dash, Ph.D.; Nachum Dafny, Ph.D.

January 4, 2012 1:00 PM

### Required Reading

---

- Nolte, Chapter 3, Gross Anatomy and General Organization of the Central Nervous System, pp. 53-64
- Nolte, Chapter 4, Meningeal Coverings of the Brain and Spinal Cord, pp. 80-94
- Brainiac: Gyri and Sulci 1-5 only (optional)

### Recommended Reading

---

- Nolte, Chapter 22, Cerebral Cortex, pp. 541-568

### Introduction

---

The purpose of this laboratory is to introduce the terminology, gross external anatomy and 3) major functional properties associated with the human nervous system. The laboratory is composed of the following five components:

- **Part A**  
**Examination of wet human brain material**
  1. Features of the brain, i.e., all the gyri and sulci, use the DeArmond Atlas as a guide. In addition, take the brain from the bucket and observe the meninges and study the surface.
  2. A hands-on examination by each student group of the gross morphological features described in the NeuroLab Online #01 "Overview Of The Nervous System." Each group will investigate the gross external structures of human brain and half brain using material provided to each laboratory group. Directions for this are located on Page 22 of this hand out.
  3. Preparations from human brain will be used by the laboratory teaching assistants to highlight the important aspects of the anatomy of the CNS.
- **Part B**  
**Complete exercise mode of Laboratory #1 of Neurolab**
  1. Each student should have gone through the NeuroLab computer program in review mode prior to arriving at the laboratory.
- **Part C**  
**An exercise at the end of the Laboratory (~3:30 P.M.) to assess your learning progress**
- **Part D**  
**Post Laboratory Review using Clinical Cases**
- **Part E**  
**Lecture: Principles of Neurological Examination**

## External Topology of the Brain

---

### *Examination of Wet Human Brain Material*

The purpose of this exercise is to introduce you to: 1) the overall structure of the nervous system; 2) general principles underlying the organization of the brain, and 3) basic nomenclature. You should pay particular attention to the spatial relationship between different brain parts to help you gain a three dimensional picture of the brain. By the end of this exercise, you should know:

1. The meningeal coverings of the brain.
2. Major gyri and sulci of the cerebral cortex.
3. Major subdivisions of the cerebral hemispheres,

Note that no two brains, nor two halves of the same brain, are exactly alike in their surface pattern. Many of the major sulci and gyri, however, are generally consistent in shape and position. Do not let the inconsistent use of the terms fissures and sulci disturb you. The term fissure is supposed to indicate a groove that is deeper than a sulcus, but many times the words are used interchangeably.

### Materials

---

Reference materials for the investigation of the human brain in this laboratory are:

1. NeuroLab Online #01 "Introduction to the Nervous System"
2. Figures on page 59-64 of Nolte
3. DeArmond Figures 1 – 6

- Brain specimen bucket containing
  - Whole brain specimen
  - Hemisected brain specimen
- Aluminum pan
- Squeeze bottles with water or bleach
- Cleanup towels for any dripping or spillage

#### *You need to bring:*

- Gloves
- Dissection kit
- Bring a plastic apron to protect your clothes.

### *Examination Of Whole And Hemisected Human Brains*

Your group is being provided a brain specimen bucket containing a whole brain and a hemisected human brain for the study of the lateral, basal and medial surfaces of the cerebrum. Use your review of the NeuroLab Online #1 "Overview Of The Nervous System" and DeArmond Atlas as guides to learn the structures and their relationships to one another as well as the major functions related to each structure.

1. If instructed to do so, dissect away the meningeal coverings over the cerebrum with BLUNT FORCEPS and scissors, if needed (bring your own). WHENEVER POSSIBLE, PRESERVE THE BLOOD VESSELS AND CRANIAL NERVES which will be studied in later labs.
2. Identify all the sulci and the gyri using the Atlas Fig 1-4 as a reference.

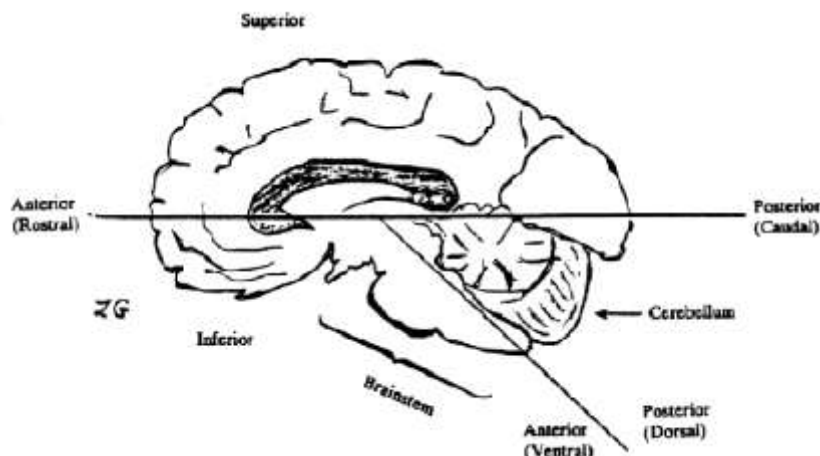


In this and all other laboratory exercises, learn to identify the locations of the structures in bold type. Also learn the names, connections (if provided), and functions of the structures that appear in bold type or in italics. You will also be responsible for knowledge of the clinical consequences of damage to the identified structures when such information is provided in the exercise. Often new terminology will be underlined or italicized: Learn the definitions and the specific meaning of these terms in the context in which they are used.

Use the whole brain to orient yourself to the various orientations of the brain.

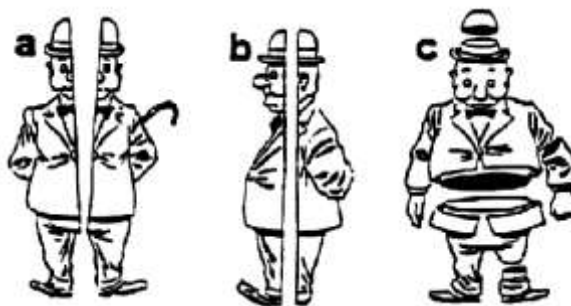
Orient yourself to these positions of the brain:

- Dorsal surface (superior) (Top of head in human upright position)
- Ventral surface (inferior) (base of brain or toward neck.)
- Rostral / anterior: Direction (toward the front of the brain i.e., direction of forehead or nose)
- Caudal / posterior direction- toward the buttock or the tail.



*Fig. 1-1 A schematic diagram of brain directions*

A coronal section is parallel to the vertical plane and a midcoronal section would divide the head into anterior and posterior halves. The sagittal section is also parallel to the vertical plane, but a midsagittal section would divide the head into right and left halves. The horizontal section is parallel to the horizontal plane and a midhorizontal section would divide the head into superior and inferior halves. Transverse or cross sections of the spinal cord of humans are taken in a plane perpendicular to the vertical, i.e., in the horizontal plane of the head



*Fig. 1-2 Planes of section: (a) sagittal; (b) coronal; (c) horizontal*

(Nolte pp. 80-90)

Within the cranium and spinal column, the brain is suspended in a clear liquid called cerebrospinal fluid (CSF) and is covered with three layers of non-neural connective tissue termed meninges (membranes). . Identify the meninges in your WHOLE BRAIN specimen.

### 1. Dura Mater

- a. dura mater, periosteum of the cranium, The cerebral dura folds into septa (partitions) to divide the cranial cavity into various components including
- b. falx cerebri between the two hemispheres, in the longitudinal fissure between the two hemispheres.
- c. tentorium cerebelli between the occipital lobe (in the back of the brain), and the cerebellum.

If the dura is still present on your specimen, gently raise it from the underlying arachnoid, and near the longitudinal fissure (midline) note the arachnoid villi (arachnoid granulations) that are extensions of the cerebral arachnoid protruding in the sinuses. In specimens with no dura attached, you may see the arachnoid villi forming small white clusters near the midline. The villi, which often become heavily calcified in older adults, serve as one-way valves in passing cerebrospinal fluid into the venous system.

### 2. Pia-Arachnoid

- a. arachnoid- Internal to the dura and separated from it by the subdural space is a more delicate membrane called the arachnoid ("spider's web"). The arachnoid covers the brain but does not follow the contour of its surface.
- b. The pia mater adheres intimately to the nervous tissue beneath it and follows the contours of the brain closely.
- c. arachnoid trabeculae, which resemble a lattice-work of connective tissue, normally extend from the arachnoid to the pia, traversing the subarachnoid space normally filled with cerebrospinal fluid (CSF)

### 3. The Subarachnoid Cisterns

- a. Identify the cerebellomedullary cistern (also known as cisterna magna) between the base of the cerebellum and medulla.

The cerebral hemispheres are paired structures separated from one another by the longitudinal fissure along the midline. A midsagittal cut through the longitudinal fissure is used to produce two hemisected brain halves.

## Lateral Aspect Of The Cerebral Hemisphere

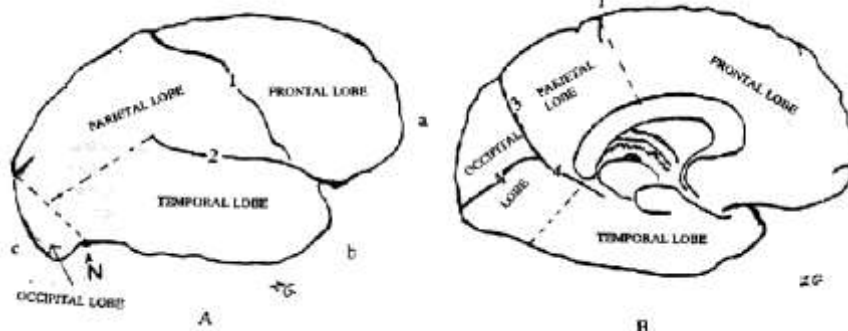
---

Using NeuroLab Online #1 "Overview of the Nervous System" as a guide, identify the following regions and structures on the gross brain. Be sure to learn their major functional roles. The photograph of the lateral aspect of the cerebrum (DeArmond, Fig. 2) will also be helpful.

Below is a list of material you need to identify and study. (Use DeArmond Atlas, Figs 1 and 2). Use the hemisected brain for the study of the lateral, basal and medial surfaces of the cerebrum

## I. The Telencephalon (Cerebral Hemispheres)

### A. The Cerebral lobes



*Fig. 1-3 Lateral (A) and medial (B) views of the poles, cerebral lobes and main sulci of the cerebral hemispheres; (a) frontal pole; (b) temporal pole; (c) occipital pole.*

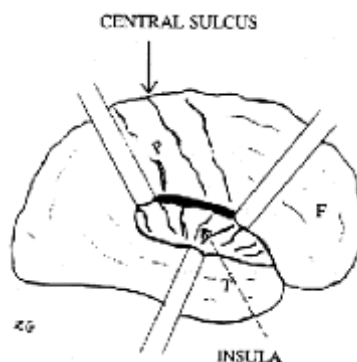
*(1) central sulcus; (2) lateral sulcus; (3) parieto-occipital sulcus; (4) calcarine fissure; N, preoccipital notch.*

Each cerebral hemisphere is organized into five lobes: frontal, parietal, occipital, temporal and insula (Figs. 1-3 and 1-4). A sixth area, the limbic system, is sometimes called the limbic lobe.

Examination of the lateral sulcus also called the Sylvian fissure that separates the temporal lobe from the rest of the lobes (DeArmond Fig. 2, pg. 4).

The central sulcus, also called Rolandic sulcus, demarcates the frontal lobe anteriorly from the parietal lobe posteriorly.

If this sulcus is difficult to find on your specimen, look for two parallel gyri extending from the superior margin of the cerebrum down to the lateral fissure. The sulcus separating these two parallel gyri is the central sulcus. On the medial surface of the specimen (in the longitudinal fissure) look for the parieto-occipital sulcus and the preoccipital notch (DeArmond, Fig. 4, pg. 8; Fig. 1-3). A line connecting the parieto-occipital sulcus with the preoccipital notch divides the parietal lobe from the occipital lobe posteriorly.



*Fig. 1-4 Frontal (F), parietal (P) and temporal (T) opercula retracted to show the insula buried underneath.*

Buried within the lateral sulcus is a fifth major lobe called the insula (also called the Island of Reil). The insula can be seen by gently retracting the frontal, parietal, and temporal opercula, as shown in Fig. 1-4.

Finally, examine the inferior surface of the brain to observe how the cortex of the frontal and temporal lobes spreads around to form a major part of the brain's inferior surface (DeArmond, Fig. 3, pg. 6).

## Frontal Lobe

The precentral gyrus is also called the somato-motor cortex because it controls volitional movements of the contralateral side of the body.

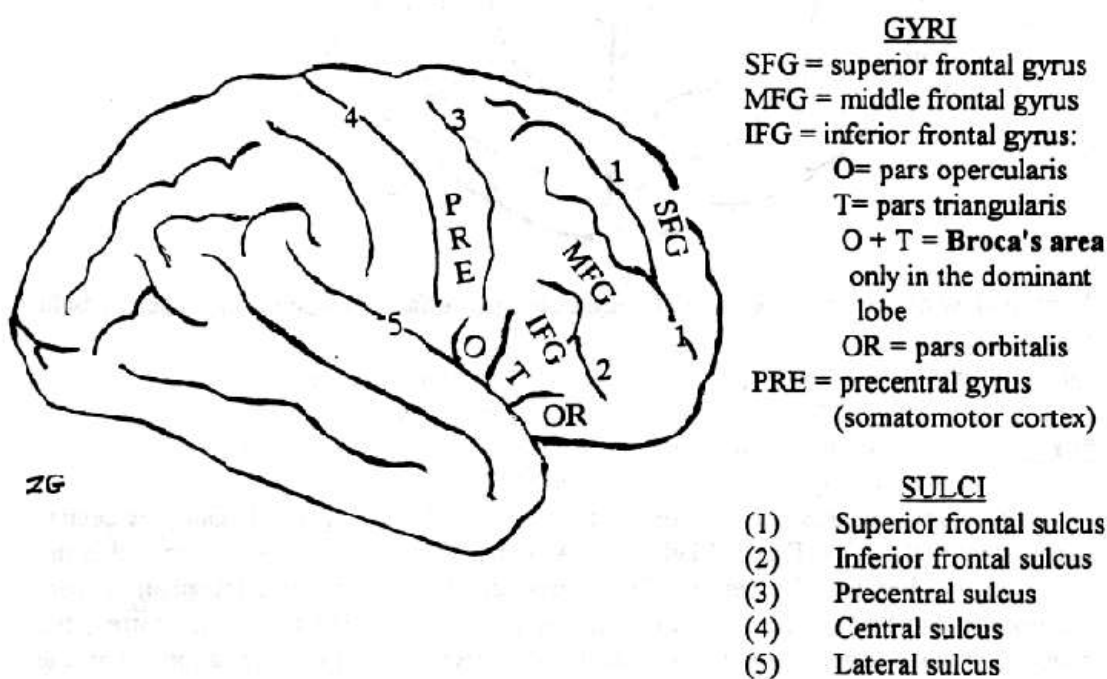
Just rostral to the precentral gyrus are three gyri oriented in the horizontal plane: the superior frontal gyrus (on top), the middle frontal gyrus and the inferior frontal gyrus (below).

Identify the three components of the inferior frontal gyrus

1. pars opercularis,
2. pars triangularis, and
3. pars orbitalis (DeArmond, Fig. 2, pg. 4, and Fig. 1-5).

In the dominant brain hemisphere (i.e. the left side in a right-handed person), the pars opercularis and pars triangularis (collectively known as Broca's area). are involved in the production of speech and in the use of language. Damage to Broca's area in the dominant hemisphere can lead to a productive (expressive) aphasia.

The frontal lobe subserves several diverse functions, including voluntary control of eye movements, emotions, and intellectual functions. Damage to this part of the brain can lead to profound changes in personality.



*Fig. 1-5 Lateral view of the frontal lobe (right side)*

## **Frontal Lobe**

- 1. Frontal pole**
- 2. Central sulcus**
- 3. Precentral gyrus**
- 4. Precentral sulcus**
- 5. Superior, middle, inferior frontal gyri**
- 6. Pars opercularis of frontal lobe**
- 7. Pars triangularis of frontal lobe**
- 8. Pars orbitalis of frontal lobe**
- 9. Broca's area**
- 10. Somatomotor area**

## **Parietal Lobe**

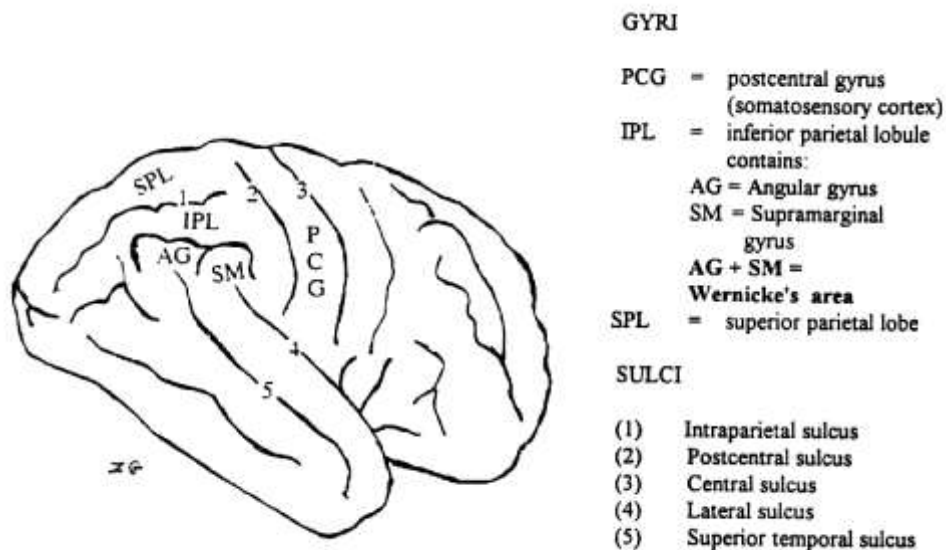
The parietal lobe is bounded rostrally by the central sulcus. The first gyrus behind the central sulcus is the postcentral gyrus (Fig. 1-7 below; DeArmond, Fig. 2, pg. 4). It is also called the somatosensory cortex, because the neurons in the postcentral gyrus receive information from sensory receptors located in the body of the skin, muscles and joints. Like the motor cortex, the somatosensory cortex is topographically organized; that is, sensory information from the contralateral side of the body, head and face is represented in specific areas of the somatosensory cortex. Damage to the postcentral gyrus produces a loss of somatosensory sensation in the half of the body contralateral to the damaged cortex.

Posterior to the postcentral gyrus is the parietal lobe, which is divided by the intraparietal sulcus into the inferior parietal lobule and the superior parietal lobule.

1. supramarginal gyrus forms a cap over the caudal end of the lateral fissure,
2. angular gyrus forms a cap over the caudal end of the superior temporal sulcus.
3. caudal parts of the superior temporal gyrus comprise Wernicke's area.

Wernicke's area is associated with the comprehension of language, both spoken and written. Damage to Wernicke's area in the dominant hemisphere reduces comprehension (receptive) aphasia.

The inferior parietal lobule includes two adjacent gyri (see Fig. 1-7) The (1)



*Fig. 1-7 Lateral view of the right parietal lobe.*

You can find the caudal boundary of the parietal lobe by locating the parieto-occipital sulcus on the medial surface of the hemisphere, and following it up to its superior limits [Fig. 1-8(B) and DeArmond, Fig. 4, pg. 8]. Then on the lateral surface, connect a line between the remote - occipital sulcus and the preoccipital notch [Fig. 1-8(A) below, and DeArmond Fig. 2, pg. 4]. The area of cortex behind this line is to the occipital lobe.

### **Parietal Lobe**

1. Parietal lobe
2. Postcentral gyrus
3. Postcentral sulcus
4. Intraparietal sulcus
5. Superior parietal lobule
6. Inferior parietal lobule
7. Supramarginal gyrus
8. Angular gyrus
9. Parieto occipital sulcus
10. Wernicke's area
11. Somatosensory receiving area

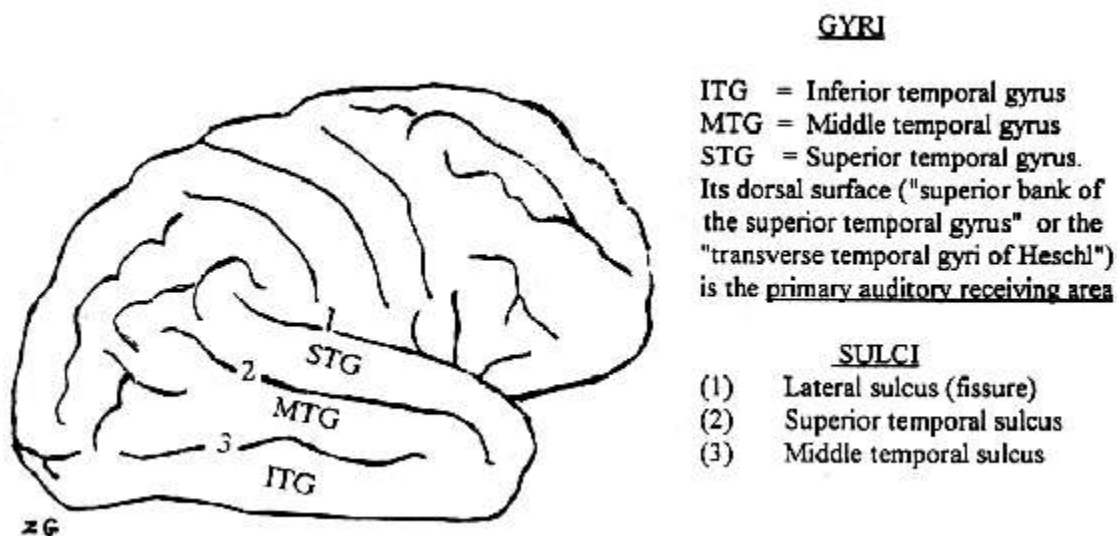


## Temporal Lobe

Find the lateral (Sylvian) fissure [Fig. 1-9(A); DeArmond, Fig. 2, pg. 4]. The cortex inferior to the lateral fissure is the temporal lobe.

1. Find the superior,
2. Middle and
3. Inferior temporal gyri.

The temporal cortex continues into the lateral fissure where its dorsal surface contains the superior bank of the superior temporal gyrus, also known as the transverse temporal gyri of Heschl. This gyrus serves as the primary auditory cortex.



*Fig. 1-9 (A) Lateral view of the temporal lobe.*

## **Temporal lobe**

1. Temporal pole
2. Lateral sulcus
3. Superior and middle temporal sulcus
4. Superior, middle, inferior temporal gyrus
5. Auditory receiving area

## Occipital Lobe

The most important function of the occipital lobe in humans is processing visual information.

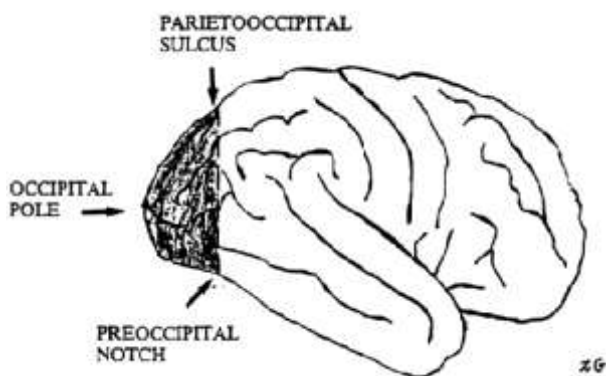
On the lateral surface of the hemisphere find the lateral occipital gyri [Fig. 1-8(A) and DeArmond, Fig. 2, pg. 4].

On the medial surface, note the prominent and deep calcarine fissure [Fig. 1-8(B) and DeArmond, Fig. 4, pg. 8].

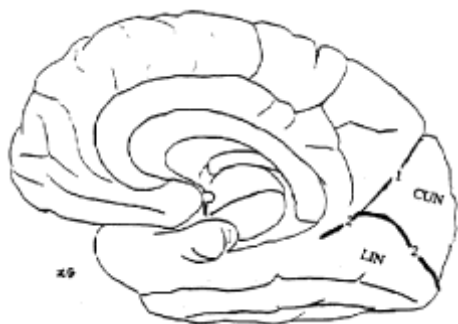
The calcarine fissure separates the occipital lobe into two parts:

1. lingual gyrus (inferior part), and
2. cuneus (superior part).

The primary visual cortex (also known as calcarine cortex) consists of the gyri that lie on both sides of the calcarine fissure. A representation of the contralateral half of the visual world is contained in the visual cortex of each hemisphere. This representation is like that of the motor and somatosensory cortices: it is topographic and provides a spatial map of the visual field. Blindness results in the half of the visual field contralateral to the damaged calcarine cortex.



*Fig. 1-8 (A) Lateral view of the occipital lobe which is formed by the lateral occipital gyri.*



### SULCI

1. Parietooccipital sulcus
2. Calcarine sulcus (fissure)

### GYRI

CUN = cuneus

LIN = lingual (lingula)

*Fig. 1-8 (B) Medial view of the occipital lobe.*

## **Occipital Lobe**

1. **Occipital pole**
2. **Occipital lobe**
3. **Preoccipital notch**

### **Insular Lobe**

In the depths of the lateral fissure lies the fifth cortical lobe, the insula (island; see Fig. 1B). The insular cortex is associated with gustatory and visceral sensations.

### **The Limbic Lobe**

The limbic lobe (also known as limbic system) is a functional grouping of telencephalic structures located on the medial and inferior aspects of the brain (Nolte, Fig. 3-2, pg. 56). These limbic structures include the: 1) subcallosal gyrus (located immediately inferior to the rostrum of the corpus callosum), 2) cingulate gyrus; 3) parahippocampal gyrus (connects to the cingulate gyrus via the isthmus, i.e. "bridge"); and 4) general location of the hippocampus (found deep in the parahippocampal gyrus) and its medial extension the uncus.



The Corpus Callosum Consists of:

R = Rostrum

G = Genu

B = Body

S = Splenium

AC = Anterior commissure (1) Calcarine sulcus (fissure)

CG = Cingulate gyrus (2) Cingulate sulcus

CUN = Cuneus (3) Precentral sulcus (medial extension)

LING = Lingual (lingula) (4) Marginal sulcus (an extension of the

PACL = Paracentral lobule the cingulate sulcus

PHG = Parahippocampal gyrus (5) Parietooccipital sulcus

PRECU = Precuneus

SCG = Subcallosal gyrus

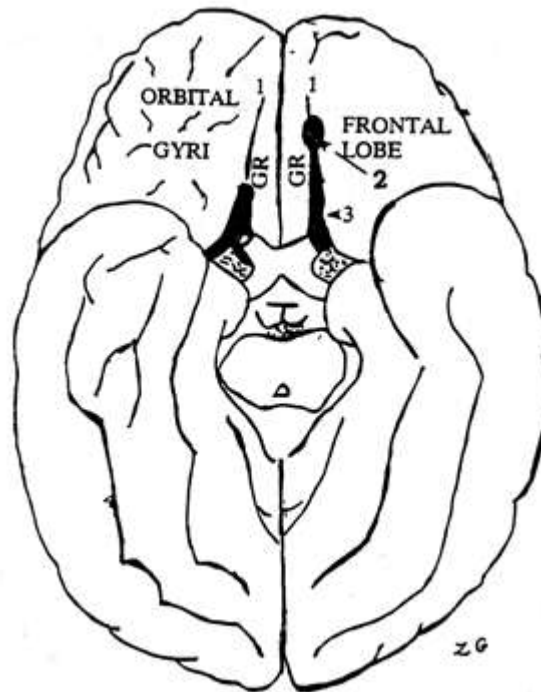
SFG = Superior frontal gyrus

U = Uncus

- 1. Corpus callosum: rostrum, genu, body & splenium**
- 2. Sulcus of corpus callosum**
- 3. Cingulate gyrus**
- 4. Cingulate sulcus**
- 5. Gyrus rectus (frontal lobe)**
- 6. Superior frontal gyrus**
- 7. Precentral sulcus**
- 8. Paracentral lobule**
- 9. Precuneus (parietal lobe)**
- 10. Parieto occipital sulcus**
- 11. Cuneus**
- 12. Calcarine sulcus**
- 13. Lingual gyrus (occipital lobe)**
- 14. Septum pellucidum**
- 15. Anterior commissure**
- 16. Marginal sulcus**
- 17. Parahippocampal gyrus**
- 18. Caudate nucleus**
- 19. Thalamus**
- 20. Hypothalamic sulcus**
- 21. Hypothalamus**

## Ventral Aspect Of The Brain

Using NeuroLab “Introduction to the Nervous System” as a guide, identify the following regions and structures on the gross brain. Be sure to learn the major functional roles. The photograph of the lateral aspect of the cerebrum (DeArmond, Fig. 3) will also be helpful.



*Fig. 1-6 Ventral view of the frontal lobes: GR = gyrus rectus; olfactory sulcus (1); olfactory bulb (2); olfactory tract (3) Primary olfactory cortex.*

### Frontal Lobe

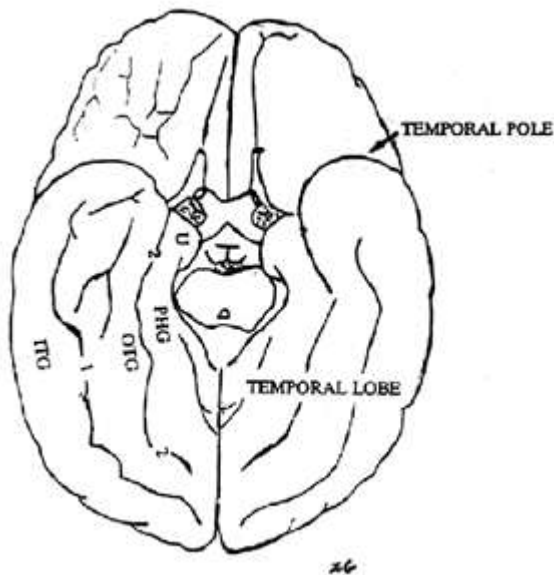
1. **Orbital gyrus**
2. **Gyrus rectus**
3. **Olfactory bulb & tract**

### Temporal Lobe

1. **Temporal pole**
2. **Uncus**
3. **Parahippocampal gyrus**
4. **Collateral sulcus & rhinal sulcus**
5. **Occipitotemporal gyrus**
6. **Inferior temporal sulcus**
7. **Inferior temporal gyrus**

### Insula

1. **Gustatory and visceral receiving areas**



### GYRI

ITG = Inferior temporal gyrus

OTG = Occipitotemporal ("fusiform") gyrus

PHG = parahippocampal gyrus

U = Uncus

### SULCI

1. Inferior temporal sulcus

2. Collateral sulcus

*Fig. 1-9 (B) Ventral view of the temporal lobe.*

On the inferior surface of the temporal lobe [Fig. 1-9(B); DeArmond, Fig. 3, pg. 6], locate the inferior temporal sulcus which separates the inferior temporal gyrus from the occipito-temporal gyrus (also known as "fusiform" because it is formed by the fusion of two gyri). Caudally the collateral sulcus, and rostrally, the rhinal sulcus, separate the occipitotemporal gyrus from the parahippocampal gyrus and the uncus. uncus The anterior part of the parahippocampal gyrus and the uncus are part of the

### FUNCTIONAL AREAS OF THE CEREBRAL CORTEX

Functionally, the cerebral cortex can be divided into three areas: (1) Primary sensory receiving areas: neurons in these areas process visual, auditory, vestibular, gustatory, olfactory, or somatosensory information. (2) Motor control areas: neurons in these areas are involved in the initiation of movements; and (3) Associative or integrative areas: neurons of most cortical areas outside the primary sensory and motor control areas are involved in the so-called higher functional processes such as language, learning, memory, and sensorimotor integration.

## Review Questions

---

- 1-1. What lobe is anterior to the central (Rolandic) sulcus?
- 1 - 2. What lobe is posterior to the parieto occipital sulcus?
- 1-3. From what embryonic brain vesicle(s) is the cerebral cortex derived?
- 1-4. What part of the frontal lobe is concerned with control of speech/language production?
- 1-5. Which part of the frontal lobe is concerned with intellectual function and personality?
- 1-6. a) What divides the occipital lobe from the parietal lobe on the lateral surface of the cortex?  
b) On the medial surface?
- 1-7. What gyrus caps the caudal end of the lateral fissure?
- 1-8. What separates the temporal lobe from the frontal lobe?
- 1-9. What is the spatial relationship between the uncus and the parahippocampal gyrus?
- 1-10. What part of the cortex is associated with visual sensations?
- 1-11. What part of the cortex is associated with auditory sensations?
- 1-12. Where are the gustatory and visceral cortices located?
- 1-13. Name the four nuclear groups that comprise the diencephalon.
- 1-14. Which meningeal membrane follows closely the contour of the brain surface?
- 1-15. Where is the somato-motor cortex located?
- 1-16. Where is the somato-sensory cortex located?
- 1-17. What is the difference between Broca's area and Wernicke's area?

## Answers

---

- 1 1. Frontal lobe
- 1 2. Occipital lobe
- 1 3. Prosencephalon, telencephalon
- 1 4. Broca's area, the pars triangularis and pars opercularis of the inferior frontal gyrus
- 1 5. Most frontal areas outside the motor control areas
- 1 6. a) A line drawn between the top of the parieto occipital sulcus and the preoccipital notch; b) The parieto occipital sulcus
- 1 7. The supramarginal gyrus
- 1 8. The lateral fissure
- 1 9. The uncus is located at the medial margin of the rostral parahippocampal gyrus
- 1 10. Calcarine cortex of occipital lobe
- 1 11. Transverse temporal gyrus of Heschl, a.k.a., superior bank of the superior temporal gyrus
- 1 12. Insula
- 1 13. Thalamus, hypothalamus, epithalamus & subthalamus
- 1 14. Pia mater
- 1-15. Precentral gyrus
- 1-16. Postcentral gyrus
- 1-17. Broca's area is implicated in the production of speech whereas Wernicke's area is implicated in the comprehension of speech.



## Laboratory Exercise #2: Internal Organization of the Brain

Lecturer: Nachum Dafny, Ph.D.

January 10, 2012 1:00 PM

### Required Reading

---

- Nolte, Chapter 3, pp. 64-73
- Nolte, Chapter 16, pp. 390-412

### Introduction

---

The main objectives of this exercise are to familiarize you with the internal organization of the fore-brain. You will be introduced to important structures at representative levels of the brain to provide an appreciation of the three dimensional organization of the brain by relating these internal structures to the external landmarks you learned in Exercise 1. To meet these objectives, you will be required to work with the NeuroLab Online #2 along with the whole brain, hemisected brain and brainstem demonstrations. The surface morphology of the brain should be carefully reviewed and the internal structures should be correlated with the external morphology and with the DeArmond Atlas. Please keep in mind that there may be one or more terms for a particular structure. In general, the present day terminology is one with a functional basis, i.e., a tract or pathway or nuclear group is usually named for the modality mediated or for origin and/or termination of the particular pathway. At the end of this exercise you should be able to:

1. Describe the external topography of the brain stem.
  2. Recognize the level of a section through the brain.
  3. Identify key structures in sections through the brain.
  4. Relate the positions of these internal structures with external landmarks.
- **Part A**  
**Examination Of Wet Human Brain Material**
    1. Your human specimens.
    2. Demonstration material presented by teaching assistants
  - **Part B**  
**Complete Exercise Mode of Neurolab Online #2**
    1. Each student should go through the NeuroLab Online computer program review mode prior to the laboratory.
  - **Part C**  
**An Exercise At The End Of The Laboratory (~3:30 P.M.) To Assess Your Learning Progress**
  - **Part D**  
**Post-Laboratory Review Using Clinical Cases**

## Materials

---

- Brain specimen bucket containing
  - Brain stem
- Aluminum pan
- Squeeze bottles with water or bleach
- Cleanup towels for any dripping or spillage

### *You need to bring:*

- Gloves
- Dissection kit
- Bring an plastic apron to protect your clothes.
- DeArmond Atlas

## External Topology Of The Brain (Continued).

---

On the whole brain, REVIEW the major subdivisions of the central nervous system. The medulla (myelencephalon) is the most caudal division of the brain and is normally continuous with the spinal cord (DeArmond, Fig. 2, pg. 4). The metencephalon consists of the pons and the cerebellum. Rostral to the pons is the midbrain (mesencephalon), which is distinguished by two anteriorly located columns of fibers, the crura cerebri or cerebral peduncles (DeArmond, Fig. 3, pg. 6).

That portion of the diencephalon, which you can see on the inferior surface of the brain, is the hypothalamus. In this view, two small round elevations, the mammillary bodies (part of the hypothalamus), mark the caudal extent of the diencephalon and the optic chiasm marks its rostral border. The remainder of the brain, i.e., the cerebrum, constitutes the telencephalon. These five divisions (i.e., the medulla, metencephalon, midbrain, diencephalon, and telencephalon) together with the spinal cord constitute the bulk of the central nervous system.

## The Midbrain Or Mesencephalon

---

(Use The Hemisected Brain And The Brain Stem)

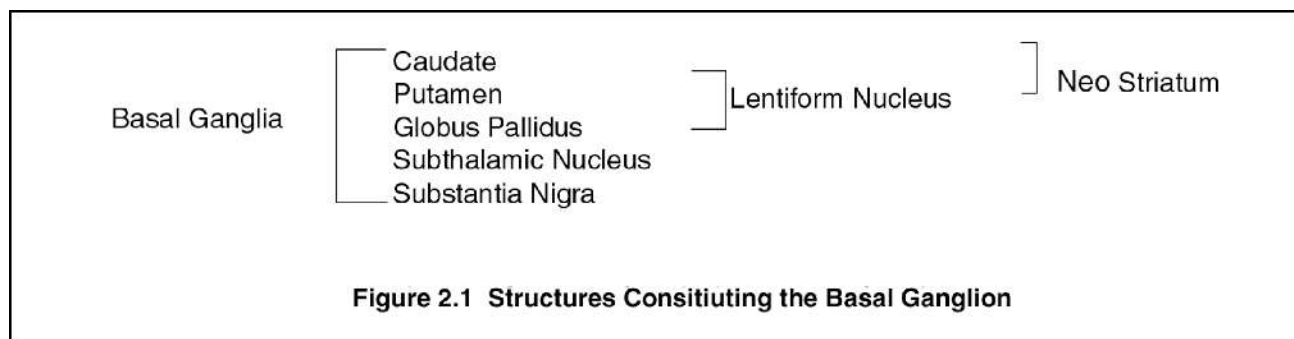
On the brain stem specimen, examine the cut edge of the midbrain and look for two black bands posterior to the two crura cerebri that are formed by the substantia nigra (DeArmond, Fig. 54, pg. 108). Locate the two large reddish gray structures, the red nuclei, located along the midline just posterior to the substantia nigra. The colors of these two midbrain nuclei in the unstained gross specimens result from pigment in their neurons. Observe also the small channel formed by the cerebral aqueduct at the midline, just anterior to the midbrain tectum. As you learned in Exercise 1, four small, round elevations, the inferior colliculi and the superior colliculi form the tectum or roof of the midbrain (DeArmond, Fig. 5, pg. 10). What is the primary function of the superior colliculi? \_\_\_\_ (2-1). The inferior colliculi? \_\_\_\_ (2-2). On the anterior surface of the midbrain two large longitudinal fiber bundles, the crura cerebri (also known as crus cerebri or cerebral peduncles) are separated by a deep groove called the interpeduncular fossa (DeArmond, Fig. 6, pg. 12).

## The Basal Ganglia

*Note the DeArmond figure is of a myelin stained section and therefore fiber tracts appear dark and most nuclear groups appear light in the photomicrograph.*

You should recall from Exercise 1 that an important structural group in the telencephalon is the so called basal ganglia. It is not really a group of ganglia, but a collection of nuclei. The basal ganglia include the caudate, putamen, globus pallidus, subthalamic nucleus and substantia nigra (Figure 2.1). The putamen and globus pallidus are often grouped together and referred to by the descriptive name lentiform nucleus (they appear as bean shaped structures in coronal section). At their most rostral point, the caudate appears to merge with the anterior putamen to form a structure called the nucleus accumbens. The nucleus accumbens and adjacent parts of the caudate and putamen form the ventral striatum. The putamen and the caudate are referred to together as the neostriatum or striatum. Some texts also refer to the caudate, putamen and globus pallidus as the corpus striatum. The basal ganglia are a major subunit of the motor control system that works with the cerebral cortex and other brainstem structures to program movements. Name five lobes of the cerebral cortex \_\_\_\_, \_\_\_\_, \_\_\_\_, \_\_\_\_, and \_\_\_\_ lobes (2-3). Which cortical lobe is involved with motor control? \_\_\_\_ (2-4).

*NOTE: The answers to questions 1-4 are at the end of this section.*



Fibers within the internal capsule contain reciprocal connection between the thalamus with the cerebral cortex by thalamocortical and corticothalamic fibers. In addition to these fibers, the internal capsule contains axons, which descend from the cortex to lower levels of the neuraxis such as the brain stem and spinal cord. These cortical efferent fiber systems, which are referred to as corticofugal fibers, include the corticoreticular, corticopontine, corticobulbar, corticorubral and corticospinal tracts. Smaller projections also exist to the basal ganglia, other areas of the diencephalon and the midbrain. Below the level of the thalamus, corticofugal fiber systems make up the crus cerebri of the midbrain. When viewing the photomicrographs in this laboratory, observe how, together, the internal capsule, crus cerebri, and medullary pyramids form a continuous fiber system from the cerebral cortex down to the spinal cord.

## The Diencephalon

---

The diencephalon consists of four parts: the epithalamus, hypothalamus, thalamus, and subthalamus. The two major structures of the diencephalon, which you have seen in the hemisected brain, are the thalamus and hypothalamus.

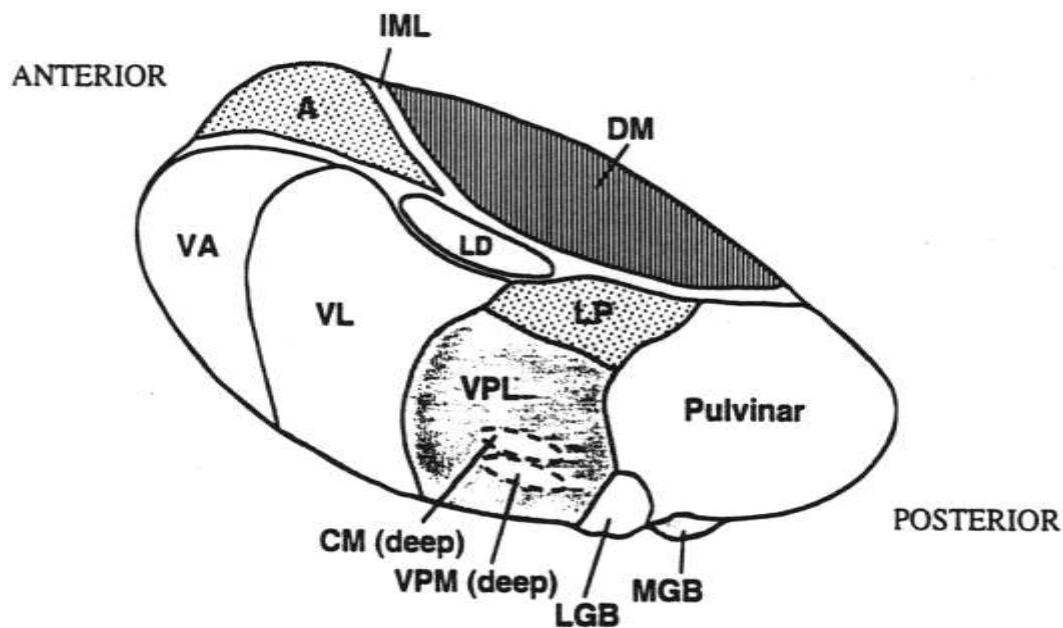
### A. Thalamus

The thalamus is a collection of nuclei that have sensory, motor or association function. In the review section at the end of this laboratory is a diagram showing the gross organization of the nuclei in the thalamus. You are not responsible for knowing the organization or names of the nuclei for the first exam. This figure is simply to introduce you to the names of these nuclei for the upcoming somatosensory and motor system labs and lectures. All sensory information traveling to the cerebral cortex reaches it by way of a sensory thalamic nucleus, except the olfactory pathway.

### B. Hypothalamus

The second major structure of the diencephalon is the hypothalamus. This area exerts important controls over visceral and endocrine activities. The hypothalamus is the major subcortical center for the regulation of both sympathetic and parasympathetic autonomic activities. It is connected extensively with the limbic system. These connections will be covered in detail in the laboratory on hypothalamic and limbic structures. The activity of the pituitary gland is also controlled by the hypothalamus. The gland is joined to the inferior aspect of the diencephalon, at the infundibulum. You saw on the hemisected brain that the lamina terminalis and anterior commissure marked the rostral border of the hypothalamus, the mammillary bodies its caudal border and the hypothalamic sulcus its superior border (DeArmond, Fig. 4, pg. 8).

## Organization And Names Of Thalamic Nuclei



Anterior group	{	A	Anterior nucleus
Medial group	{	DM	Dorsomedial nucleus
Lateral group	[	VA	Ventral Anterior nucleus
		VL	Ventral Lateral nucleus
		LD	Lateral Dorsal nucleus
		LP	Lateral Posterior nucleus
		VPL	Ventral Posterolateral nucleus
		VPM	Ventral Posteromedial nucleus
		LGB	Lateral Geniculate Body
Intralaminar nuclei	{	CM	Centromedian nucleus
		IML	Internal Medullary Lamina

Figure 2-2. A cartoon of the general organization of the left thalamus and the major groupings of thalamic nuclei.

At the conclusion of this laboratory you should be able to identify the following internal structures of the brain. Many of these structures can be found in several slides. Some are landmarks demarcating different structures, some are nuclei, some are myelinated fiber tracts, and others are fluid filled spaces.

**Internal Capsule**

- Corona Radiata
- Anterior Limb
- Genu
- Posterior Limb
- Sublenticular Limb

**Basal Ganglia and Related Structures**

- Insula
- Claustrum
- Putamen
- Caudate
  - Head
  - Body
  - Tail
- Globus Pallidus
- Neostriatum (caudate & putamen)
- Lentiform or lenticular nucleus (putamen & globus pallidus)
- Substantia nigra
- Subthalamic
- Nucleus accumbens
- Amygdala

**Diencephalon and Related Structures**

- Thalamus and related structures
- Stria Terminalis
- Red Nucleus
- Terminal Vein
- Stria Medullaris Thalami
- Hypothalamus and Hypothalamic Sulcus
- Optic Tracts, Optic Chiasm, Optic Nerve
- Parahippocampal Gyrus
- Hippocampal Formation
- Temporal Lobe
- Corpus Callosum
- Fornix
- Mammillary Bodies
- Cerebral Peduncle
- Cerebral Aqueduct
- Tectum
- Inferior Colliculi
- Superior Colliculi

## Answers

---

- 2-1. Visual
- 2-2. Auditory
- 2 3. The frontal, parietal, occipital, temporal & insula lobes
- 2 4. Frontal lobe, precentral gyrus is especially important

## Laboratory Exercise #3: Ventricles, Blood Vessels, and External Surface of the Brain Stem

Lecturer: Terry Crow, Ph.D.

January 17, 2012 1:00 PM

### Required Reading

---

- Nolte, Chapter 5, Ventricles and Cerebrospinal Fluid
- Nolte, Chapter 6, Blood Supply of the Brain

### Introduction

---

In this part of the exercise, we will first examine the ventricles and the superficial blood vessels of the brain. We will then examine the external surface of the brain stem and the cranial nerve attachments. As the veins are impossible to differentiate from small arteries in the gross material, we will not go over the veins in this exercise. Consequently, it is important that you read the assignments in Nolte to gain an appreciation of the locations of the major veins and the venous sinuses. External landmarks of the brainstem should be studied as an aid to determining the level of the brain stem, to help develop a three-dimensional view to correlate with slides, and to help identify and recall the points of attachment of the cranial nerves.

The cranial nerves, which you covered in Gross Anatomy, should be reviewed. Try to recall their extracranial course, the structures they innervate, and the functions they subserve. You will spend a considerable amount of time in later exercises learning about the central connections of the cranial nerves and a bit of effort reviewing their peripheral connections now will be helpful to you. As you locate each cranial nerve, identify the part of the brain to which it is attached and try to recall from what embryonic brain vesicle it is derived.

Provided you have carried out your reading assignments, at the end of this part of today's exercise, you should be able to:

1. Recall the major characteristics of the ventricles and the flow of cerebrospinal fluid through the brain.
2. Identify the major superficial blood vessels of the brain and describe the regions supplied by the vessels.
3. Describe the external topography of the brain stem.
4. Identify the cranial nerves and the points of their attachment to the brain.

- **Part A**

#### **Examination of wet human brain material**

1. Personal exploration of bench human specimens
2. TA demonstration material

- **Part B**

#### **Complete Exercise Mode Of Laboratory #3 Of Neurolab Online**

1. Each student should go through the NeuroLab computer program review mode prior to the laboratory



- **Part C**  
**An Exercise At The End Of The Laboratory (~3:30 P.M.) To Assess Your Learning Progress**
- **Part D**  
**Post-Laboratory Review Using Clinical Cases**

## Materials

---

- Brain specimen bucket containing
  - Whole brain specimen
  - Hemisected brain specimen
- Aluminum pan
- Squeeze bottles with water or bleach
- Cleanup towels for any dripping or spillage

### *You need to bring:*

- Gloves
- Dissection kit
- You may want to bring an plastic apron to protect your clothes.

The hemisected brain will be used to examine the ventricles and the whole brain will be used to study the superficial blood vessels. Be certain to keep your bench's specimens moist to prevent desiccation while working with them.

A cast of the ventricular system will be provided in your room, examine it to gain a three-dimensional view of the ventricles.

To assist in this lab, also use DeArmond Figs. # 48, 99, 101, 103, 104, 105 and Nolte Figs. # 5-1, 5-2, 5-3, 5-7, 5-10, 5-13, 6-2, 6-3, 6-4, 6-6, 6-8, 6-10, 6-11, 6-15, 6-29, 6-31, 11-29. In this and in all other exercises, learn to identify the names, locations, areas of the brain receiving blood from the identified blood vessels.

## Pons

---

Part of the posterior surface of the pons forms the rostral half of the floor of the fourth ventricle. The stria medullaris in the floor of the fourth ventricle forms the caudal border of the pons (Nolte, Fig. 11-3, p.270). The stria medullaris thalami are found in what division of the brain? \_\_\_\_ (3-1). Rostral to the stria medullaris, the paired elevations bordering the median sulcus are called the facial colliculi. The elevation which continues rostral to the facial colliculus is known as the median eminence. A shallow groove, the sulcus limitans, extends from the pons into the medulla and separates the facial colliculus and median eminence from the more laterally located sensory or vestibular area. The superior cerebellar peduncles appear on the rostral end of the posterior pons as two bands of fibers running in the walls of the fourth ventricle.

The anterior surface of the pons is characterized by a massive band of transverse bundles of nerve fibers that converge posteriorly on each side to form the middle cerebellar peduncles (DeArmond, Fig. 6 & 5, pp. 12 & 10). The shallow groove running along the midline marks the normal course of the basilar artery. The pontomedullary sulcus marks the caudal border of the anterior surface of the pons.

## Medulla

---

The anterior median sulcus along the midline of the anterior medulla divides two longitudinal eminences called the pyramids (DeArmond, Fig. 6, pg. 12). This sulcus is obscured by small fiber bundles in the pyramidal decussation near the junction of the medulla and the spinal cord. Rostrally, the preolivary sulcus, containing rootlets of the hypoglossal nerve (cranial nerve XII) divides the pyramids from the olivary eminence. The postolivary sulcus borders the olivary eminence laterally and contains the rootlets of the glossopharyngeal nerve (cranial nerve IX), the vagus nerve (cranial nerve X), and the spinal accessory nerve (cranial nerve XI).

In a posterior view, the medulla is seen to consist of a closed, caudal portion that contains a continuation of the spinal cord central canal and an open, rostral portion that forms part of the floor of the fourth ventricle (DeArmond, Fig. 5, pg. 10). The apex of the V-shaped caudal border of the fourth ventricle is known as the obex. The posterior median sulcus extends rostrally from the spinal cord to the obex. Lateral to this sulcus is a longitudinal bulge, the gracilis tubercle or clava. At a level slightly rostral to the clava, the cuneate tubercle appears as a small bulge laterally. The tuberculum cinereum is a slight swelling located lateral to the cuneate tubercle. Where is the tuber cinereum located? \_\_\_\_ (3-2). The tuberculum cinereum becomes displaced laterally in the rostral (open) medulla by the large inferior cerebellar peduncles or restiform body. The stria medullaris in the floor of the fourth ventricle marks the rostral border of the medulla. The median sulcus divides the floor of the ventricle along the midline, while the sulcus limitans divides each half of the medulla into medial (motor) areas and lateral (sensory) areas. The motor area of the medulla consists of two paired elevations called trigones. The paired elevations nearest the midline are called the hypoglossal trigones. The vagal trigones are located just lateral to the hypoglossal trigones. Lateral to the sulcus limitans is the sensory or vestibular area. The inferior cerebellar peduncles appear as two ridges extending along the sides of the ventricle on the lateral surface of the medulla.

## Examination Of Wet Human Brain Material

---

Identify The Following On The Gross Brain:

### Ventricles and Foramina

- Lateral Ventricle
- Frontal Horn
  - Temporal Horn
  - Posterior Horn
  - Body
  - Atrium
- Foramen of Monro, Foramen of Magendie, Foramina of Luschka
- Third Ventricle
- Aqueduct of Sylvius
- Fourth Ventricle
- Choroid plexus

### Arterial Blood Supply

- Internal Carotid Arteries
- Vertebral Arteries
- Anterior, Posterior and Middle Cerebral Arteries
- Anterior Choroidal Arteries
- Medial Striate Arteries (Recurrent artery of Heubner, see Figure 3-1)
- Anterior Communicating Artery
- Lateral Striate Arteries
- Posterior Communicating Arteries
- Basilar Artery
- Superior Cerebellar Arteries
- Paramedian Arteries
- Anterior Inferior Cerebellar Arteries
- Posterior Inferior Cerebellar Arteries
- Vertebral Arteries
- Anterior Spinal Artery
- Posterior Spinal Arteries

### Brainstem Structures

- Pontomedullary Sulcus
- Hypoglossal Trigone
- Vagal Trigone
- Anterior Median Sulcus
- Pyramids
- Preolivary Sulcus
- Olivary Eminence
- Postolivary Sulcus
- Facial Colliculi

- Sulcus Limitans
- Superior Cerebellar Peduncle
- Middle Cerebellar Peduncle
- Inferior Cerebellar Peduncle

## Cranial Nerves

---

- Identify on the gross brain cranial nerves II-XII

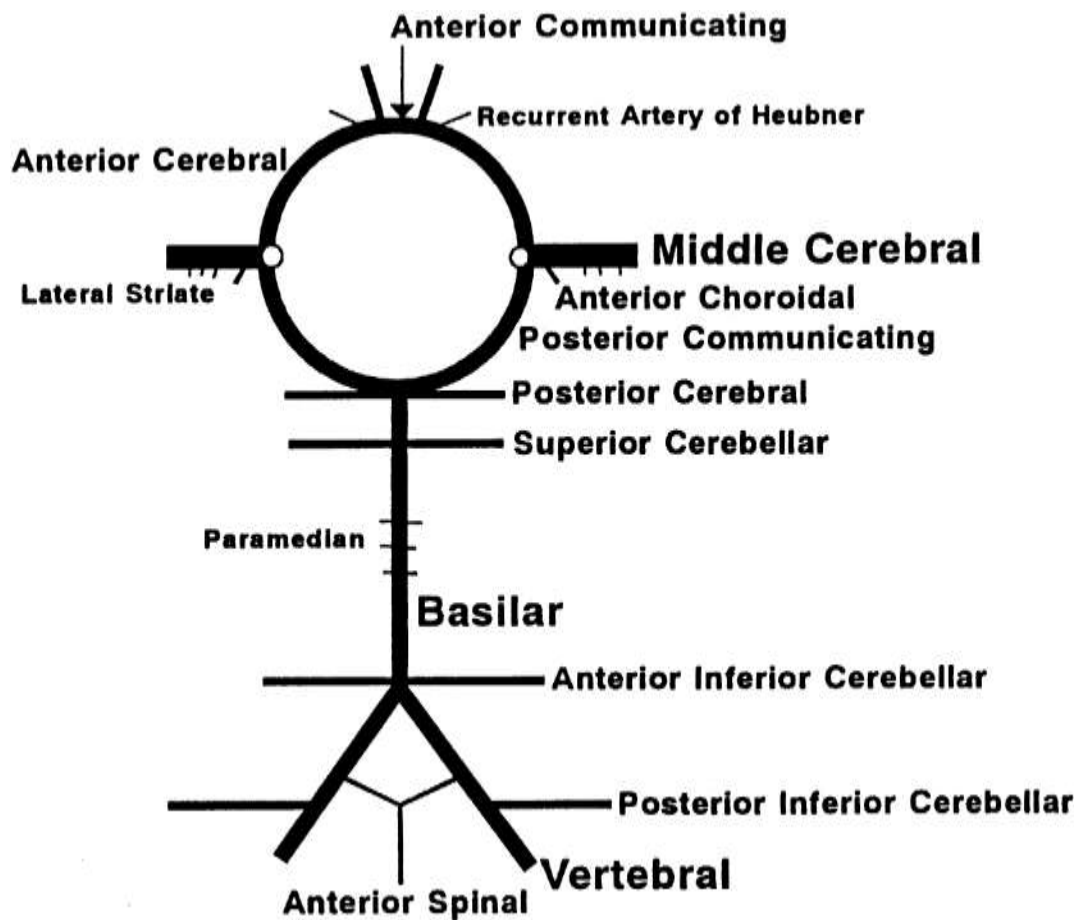


FIGURE 3-1. Diagram of the major components of the Circle of Willis and superficial blood vessels of the brain. (Adapted from figure by T. Crow)

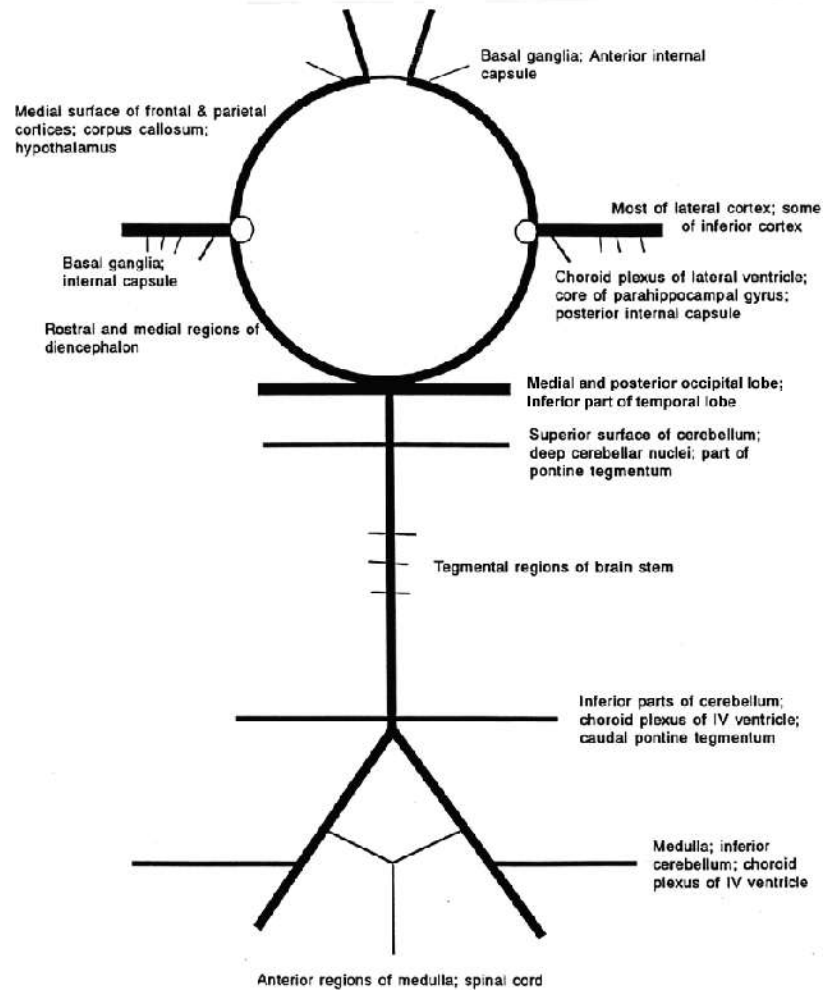


FIGURE 3-2. Diagram of brain areas supplied by the Circle of Willis and major superficial blood vessels (Adapted from a figure by T. Crow)

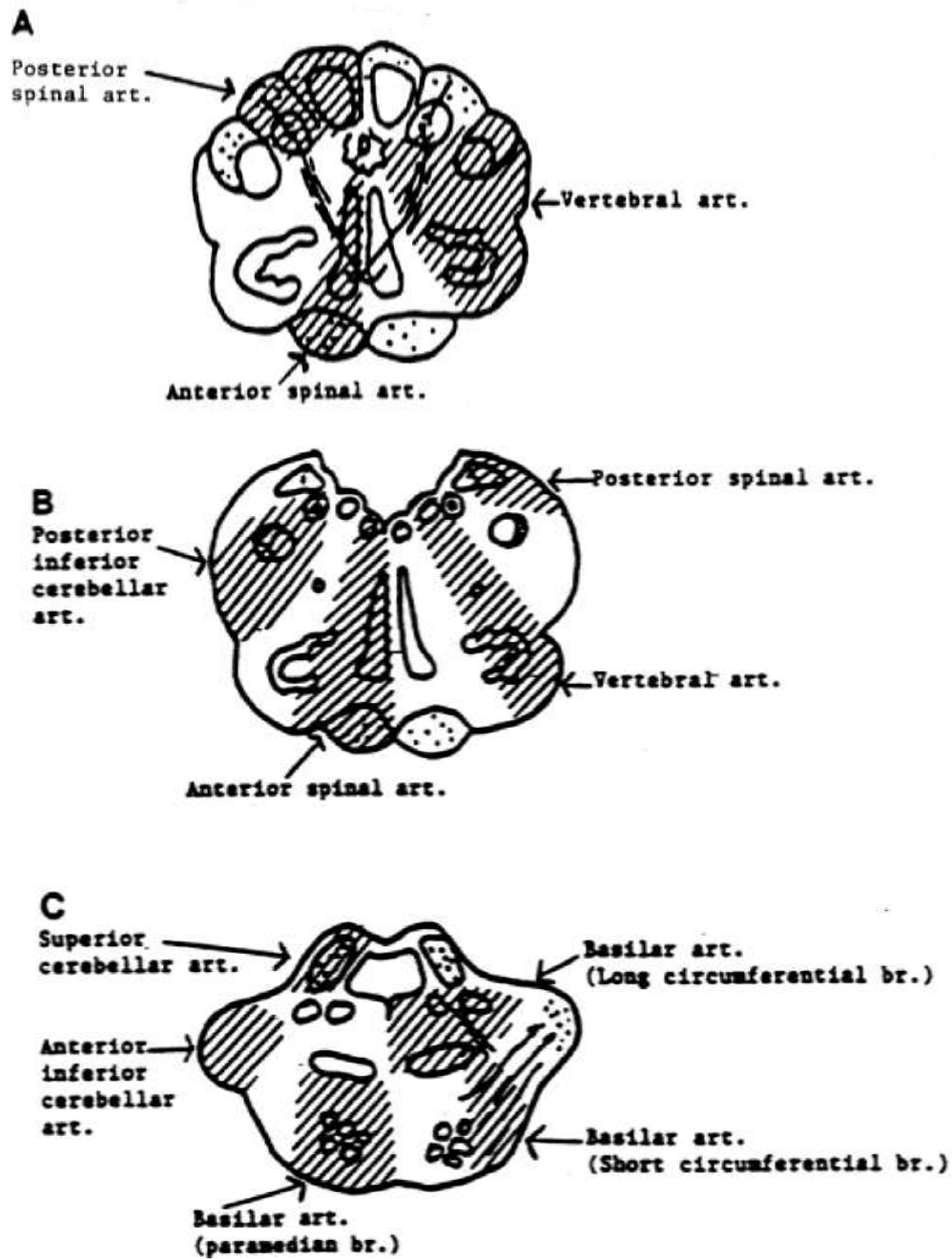


FIGURE 3-3. Diagrams of the arterial supply of the closed medulla (A), open medulla (B), and pons (C). Shaded areas show approximate region nourished by the indicated vessels. (Adapted from "Core Text for Neuroanatomy", Malcolm B. Carpenter Williams & Wilkins, Baltimore)

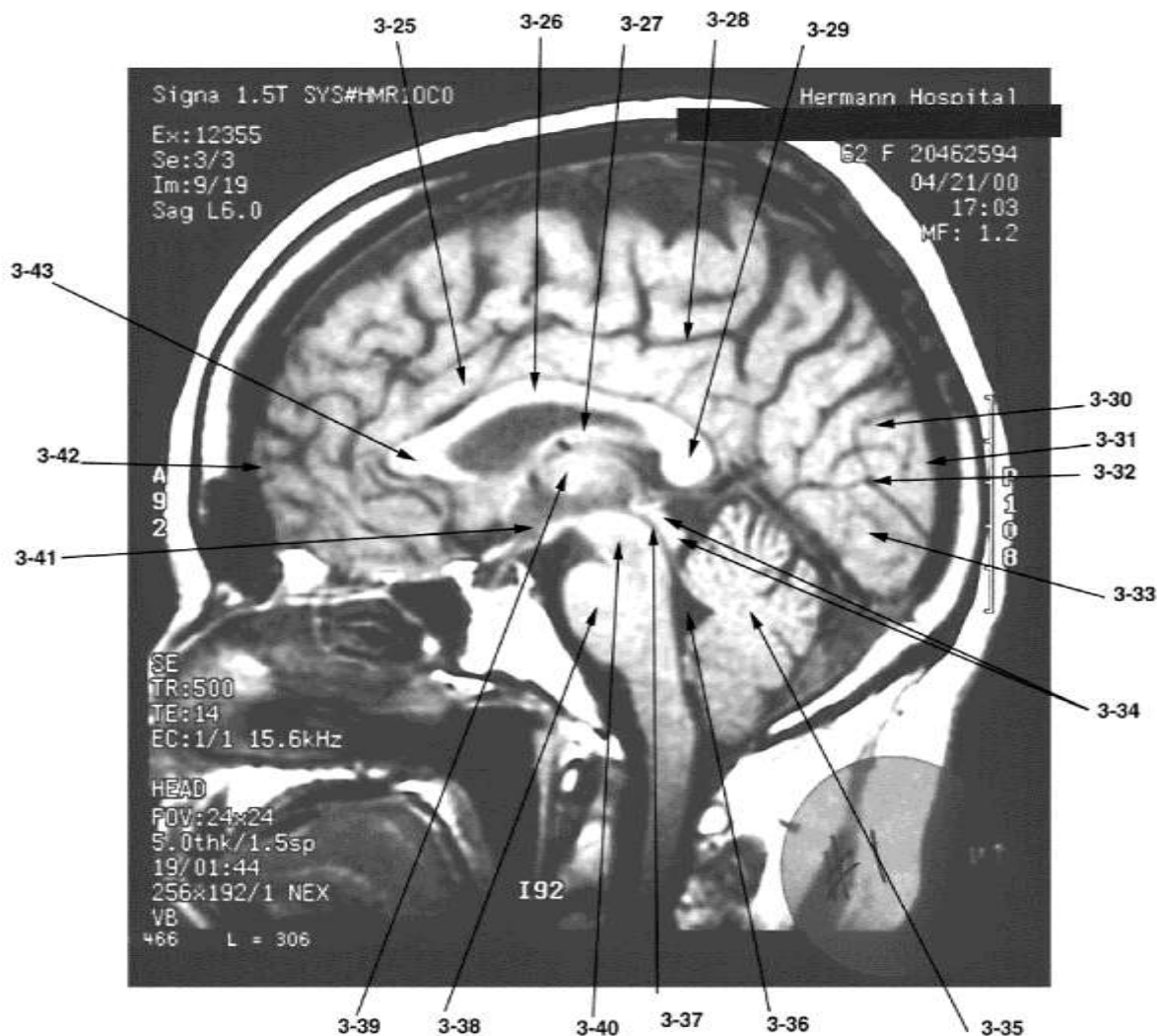


Figure 3.4: MRI mid-sagittal section. With the help of the DeArmond Fig. 4 (pages 8-9), identify:

- the main subdivisions or structures at the tip of the pointers 3.26, 3.27, 3.29, 3.34, 3.35, 3.38, 3.39, 3.40, 3.41, and 3.43
- the sulci at the tip of pointers 3.28 and 3.32
- the gyri at the tip of pointers 3.25, 3.30, 3.33
- the subdivision of the ventricular system at the tip of pointers 3.36 and 3.37
- the poles at the tip of pointers 3.31 and 3.42

## Answers

- 3-1. The prosencephalon
- 3-2. The hypothalamus



# Laboratory Exercise #4:

## Spinal Cord: External and Internal Anatomy and Introduction to Somatosensory Pathways

Lecturer: Nachum Dafny, Ph.D.

January 31, 2012 1:00 PM

### Required Reading

---

- Nolte, Chapter 9, pp. 201-218 Sensory Receptors
- Nolte, Chapter 10, pp. 227-252 Spinal Cord

### Introduction

---

The spinal cord constitutes a vital link between the brain and most of the body. Within it are long tracts of ascending and descending axons, which transmit sensory and motor information up and down the neuraxis. Certain reflexes are controlled by mechanisms within the spinal cord. Damage to the spinal cord can disrupt the flow of information necessary for conscious appreciation of sensory events and voluntary control of limb, trunk, bowel, and bladder movements. Spinal cord trauma

due to auto accidents, sports injuries and combat is especially tragic since the affected population is frequently in the prime of life at the time of the trauma, and there is often no other impairment of intellectual and communicative faculties. The secondary effects of the paralysis, e.g., urinary tract infection, may further complicate treatment of these patients.

In part one of today's exercise, you will study in detail the gross anatomy of the spinal cord and will be introduced to the intrinsic organization of the spinal cord. At the end of part one of today's exercise, you should be able to:

1. Describe the external topography of the spinal cord, the spinal meninges, and blood supply.
2. Identify, on a microscopic level, the principal spinal cord cell groupings and their functions.
3. Understand some of the basic principles underlying the organization of the spinal cord.
4. Identify the major spinal cord fiber tracts and their functions.

- **Part A**

#### **Examination Of Wet Human Brain Material**

1. Examination of wet human brain material: the external & internal anatomy of the spinal cord
2. Demonstration material presented by teaching assistants

- **Part B**

#### **Complete Exercise Mode Of Laboratory #4 Of Neurolab, Version 4.2**

1. Each student should go through the NeuroLab Online computer program review mode prior to the laboratory.

- **Part C**

**An exercise at the end of the laboratory (~3:30 p.m.) To assess your learning progress**

- **Part D**

**Post-Laboratory Review Using Clinical Cases**

## Materials

---

- Brain specimen bucket containing
  - Spinal Cord
- Aluminum pan
- Squeeze bottles with water or bleach
- Cleanup towels for any dripping or spillage

### *You need to bring:*

- Gloves
- Dissection kit
- You may want to bring an plastic apron to protect your clothes.

## Gross Specimen – Spinal Cord

---

### External Landmarks

Look at the diagram of the entire spinal cord in DeArmond (Fig. 31, pg. 63) and the gross specimen. Notice that the spinal cord is a long thin structure whose thickness varies from caudal to rostral. Nerve rootlets emerge from the posterolateral and anterolateral parts of the cord along its entire length (Nolte, Fig. 10-1, pg. 228). You will notice that a few centimeters from the cord, groups of nerve rootlets fuse together to form the posterior & anterior roots (normally 31 pairs in the intact spinal cord). Each pair of roots passes through one of the intervertebral spaces of the spinal column. The spinal cord consists of 31 segments defined by their corresponding pair of posterior and anterior roots (8 cervical, 12 thoracic, 5 lumbar, 5 sacral & 1 coccygeal).

In the demonstration and your gross materials locate the cervical & lumbar enlargements, the conus medullaris, the cauda equina, and the filum terminale (Nolte, Fig. 10-3, pg. 230). Locate the following longitudinal fissures and sulci, which divide the spinal cord: anterior median fissure, posterior median sulcus, posterolateral sulcus, posterior intermediate sulcus, and anterolateral sulcus, (Figure 4-1). Note that the posterior intermediate sulcus is present only above level T6.

Observe the cut surface of the spinal cord. In the central gray matter, note the posterior horn and anterior horn (Fig. 4-2 of this exercise). At thoracic levels, the intermediate region between the posterior and anterior horns expands laterally to form the intermediolateral or lateral horn. Recognize the small central canal within the gray commissure that connects the gray matter on either side. The anterior white commissure is formed by decussating fibers anterior to the gray commissure. In the outer white matter, locate the posterior, lateral, & anterior funiculi or columns. Do not be confused by the interchangeable use of dorsal & posterior or ventral & anterior funiculi (Fig. 4-1). The terms dorsal and ventral are applicable to quadrupeds while the terms anterior and posterior are equivalent but applicable to bipeds.

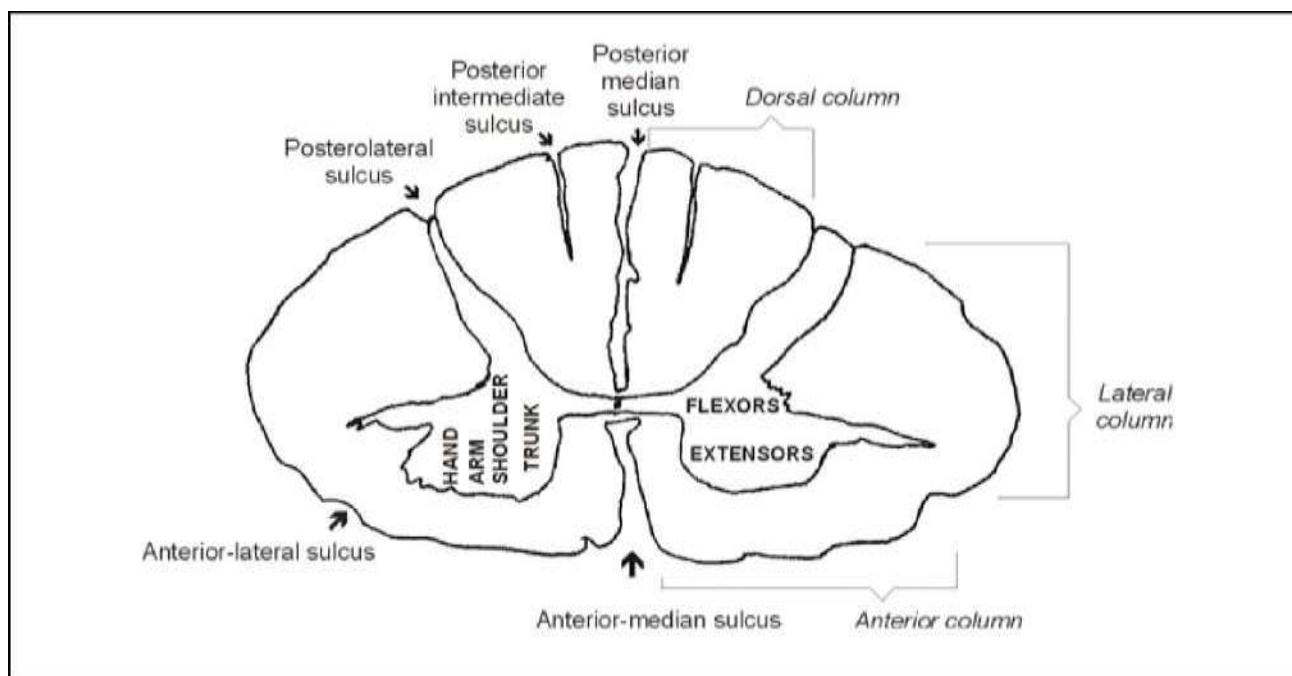


Figure 4-1: Diagram of the cervical spinal cord to indicate the different sulci and the general location of anterior horn cells that send motor axons to specific muscle groups of the upper extremity.

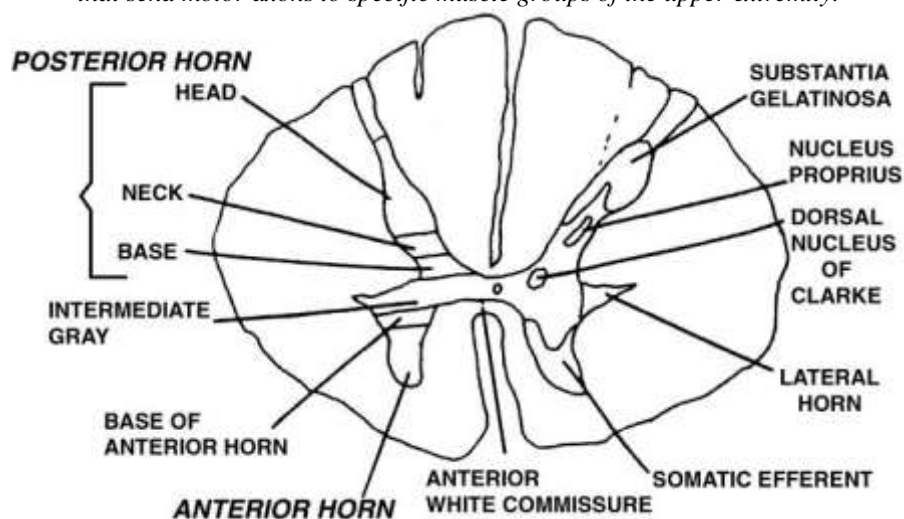


Figure 4-2: Diagram of the thoracic spinal cord to demonstrate the important subdivisions of the gray matter.

## Position Of Spinal Cord In The Vertebral Canal

The brain and spinal cord are semi-solid structures encased in the hard, bony structure of the cranium and vertebral canal (Nolte, Fig. 10-2, pg. 228). In the adult, the spinal cord extends from the foramen magnum to the lower border of the first lumbar vertebra. Below vertebral level L2, the vertebral column contains only the roots of spinal nerves, the cauda equina, which will exit the column at lower levels. Consequently, the spinal cord proper occupies only the upper two thirds of the vertebral canal. An important consequence of this is that the level of the cord that gives rise to a spinal nerve does not necessarily correspond physically to the level at which the nerve leaves the vertebral canal. This also

means that a needle can be inserted into the lower region of the vertebral canal (below the second lumbar vertebra) to sample cerebral spinal fluid (CSF), measure its pressure, or to introduce anesthetic agents without danger of damaging the spinal cord.

## Spinal Cord Meninges

---

The CSF and the spinal meninges protect the spinal cord within the vertebral column. These membranes are continuous with the cerebral meninges at the foramen magnum and the spinal subdural & subarachnoid spaces are thus continuous with the corresponding cranial spaces. This is important since bleeding, infection, or inflammation in the cerebral subarachnoid space can be detected by sampling CSF from the lumbar subarachnoid space (i.e., using a lumbar puncture). CSF is produced by the \_\_\_\_\_ (4-1) located in the \_\_\_\_\_, \_\_\_\_\_, and \_\_\_\_\_ (4-2) ventricles. (You learned this in lab #3).

The spinal dura extends down to the level of the second sacral vertebra (Nolte, Fig. 10-3, p. 230) and is separated from the vertebral periosteum by the epidural space. The epidural space contains veins and fat. Note that the spinal nerve roots traverse the epidural space; thus allowing the effective introduction of local anesthetics into this space, particularly for obstetric purposes (as in an epidural block). The anterior and posterior nerve roots penetrate the dura at the intervertebral foramen, and the sleeve of dura, which envelops these roots, becomes continuous with the epineurium of the peripheral nerves.

The arachnoid extends with the dura down to the level of the second sacral vertebra. It is separated from the dura by the subdural space which is more potential than real. The subarachnoid space is wider and contains cerebrospinal fluid. Since the arachnoid extends to the second sacral vertebra, but the spinal cord ends at the level of the upper lumbar vertebra, a large cistern, the lumbar cistern, is formed below the second lumbar vertebra. CSF can be safely sampled without puncturing the spinal cord by introducing a needle into the lumbar cistern.

The pia adheres closely to the spinal cord. The blood vessels of the spinal cord lie on the surface of the pia. In the specimen provided, LOOK for the spinal dura, arachnoid, & pia. The denticulate ligaments are double folds of pia that extend from the lateral aspect of the cord to the inner surface of the dura - where they are attached on each side as a series of some 21 tooth-like extensions. The points of attachment of the dentate ligaments alternate with the points of exit of nerve roots. At the conus medullaris, the filum terminale, which is also derived from the pia, extends caudally to penetrate the dura and continue as the coccygeal ligament (Nolte, Fig. 10-3, pg. 230). If you cannot find the filum terminale or coccygeal ligament on your row's specimen, be sure to examine the demonstration specimens.

## Blood Supply Of The Spinal Cord

---

The arterial blood supply to the spinal cord in the upper cervical regions is derived from two branches of the vertebral arteries, the anterior spinal artery and the posterior spinal arteries (Nolte, Fig. 10-29 & 30, pp. 261-262). At the level of medulla, the paired anterior spinal arteries join to form a single artery that lies in the anterior median fissure of the spinal cord. The posterior spinal arteries are paired and form an anastomotic chain over the posterior aspect of the spinal cord. A plexus of small arteries, the arterial vasocorona, on the surface of the cord constitutes an anastomotic connection between the anterior and posterior spinal arteries. The spinal arteries continue in an uninterrupted fashion along the entire length of the spinal cord.

At spinal cord regions below upper cervical levels, the anterior and posterior spinal arteries narrow and form an anastomotic network with radicular arteries (Nolte, Fig. 10-30, pg. 262). The radicular arteries are branches of the cervical, trunk, intercostal & iliac arteries. The radicular arteries supply most of the lower levels of the spinal cord. There are approximately 6 to 8 pairs of radicular arteries supplying the anterior and posterior spinal cord.

## Peripheral Nerves

The peripheral processes of the posterior root ganglion cells and the fibers of the anterior root join to form a spinal nerve, which leaves the vertebral canal through an intervertebral foramen (Nolte, Fig. 10-2, p. 229). Once out of the vertebral canal, the spinal nerve branches immediately to form posterior & anterior rami. These rami branch again and form the peripheral nerves, which travel to skin, muscle or viscera, which they innervate. The cutaneous area supplied by a single posterior root and its ganglion is called a dermatome; the somatic musculature supplied by an anterior root is called a myotome. In diseases involving nerve roots (e.g., herniation of the intervertebral discs), one can localize the level of root injury by identifying the dermatome (sensory) or myotome (motor) in which the defect is present.

**REVIEW:** In distinguishing spinal cord levels, the following are useful to remember: (1) Rostral regions (where ascending fibers have accumulated from all cord levels, and descending fibers have not yet dispersed to their terminations) naturally have more white matter than more caudal regions and conversely, caudal regions have less white matter. (2) In regions supplying the limbs and digits (i.e., the cervical & lumbar enlargements), the gray horns are enlarged as they contain more neurons than other levels of the cord. This provides a higher density of innervation of skin and muscle to subserve increased sensory acuity and discrete motor control in the limbs and digits. (3) The lateral horn is present only at thoracic and lumbar levels; and (4) The posterior intermediate sulcus subdivides the posterior funiculus at levels above T6.

The cervical segments are characterized by their large size, extensive white matter, and the increase in gray matter in the segments which supply the efferent and afferent innervation to the brachial plexus. The fasciculus cuneatus of the posterior funiculus at cervical level is much larger than at thoracic levels. There are no autonomic neurons and no dorsal nucleus of Clarke at cervical levels of the spinal cord, while all descending tracts are present.

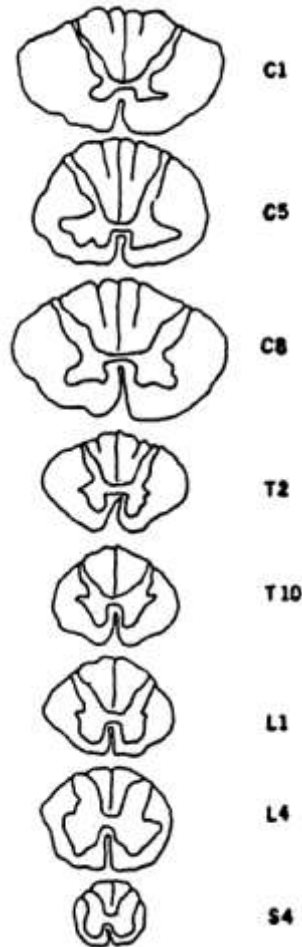
The thoracic segments are characterized by the prominent lateral gray horn, which extends into the lateral funiculus. The lateral horn contains the cell bodies of preganglionic sympathetic nerve fibers. The thoracic segments of the spinal cord also display variations, which enable one to identify which level of the thoracic cord is being observed. Lower thoracic (T9 T12) segments have larger anterior horns than the upper thoracic (T2 T8) segments because the lower thoracic segments supply axial musculature (back & intercostals) and abdominal musculature, while the upper thoracic segments supply only axial musculature. The posterior intermediate sulcus appears at and above level T6 and subdivides the posterior funiculus into the fasciculus gracilis and fasciculus cuneatus.

The lumbar segments of the spinal cord appear enlarged when compared with sections through the lower thoracic and sacral segments. The gray horns are enlarged to accommodate the increase in density of innervation of the lower limbs and digits. The anterior gray horn is expanded laterally with the increased motor innervation of the leg and foot.

The sacral segments are characterized by their small overall diameter, by the thick appearance of the gray matter relative to the white matter, by their short gray commissure, and by the relatively small amount of white matter in all three surrounding funiculi.

### Internal Structures Of The Spinal Cord

The internal structures of the spinal cord are comprised of the centrally located gray matter and the peripherally located white matter.



*Figure 4 3: Diagram of spinal cord segments at different levels. Notice the variations in size and shape of the centrally located gray matter. The letters and numbers correspond to the respective spinal levels.*



Table 4-I: Provides the relationship between the traditional classification of nuclear groups and the scheme of Rexed. The laminae of Rexed were devised to describe histological and functional nuclear groups in the spinal cord. They were included in the Table because they are widely used in the scientific literature on the spinal cord.

TABLE 4-I: SPINAL CORD NUCLEI AND LAMINA OF REXED

Nucleus	Lamina	Extent	Function
Nucleus posteromarginalis	I	Entire cord	Neospinothalamic: sharp pain
Substantia gelatinosa	II, III	Entire cord	Paleospinothalamic: dull pain & Thermal, Simple touch
Nucleus proprius	III, IV, V	Entire cord	Paleospinothalamic: dull pain & Thermal, Simple touch
Dorsal nucleus of Clarke	VII	C8-L3	Origin posterior spinocerebellar tract
Lateral horn	VII	T1-L3	Origin preganglionic sympathetic axons
Sacral parasympathetic	VII	S2-S4	Origin preganglionic parasympathetic axons
Medial motor	IX	Entire cord	Efferents to muscles of neck & trunk
Lateral motor	IX	C4-T1 & L2-S3	Efferents to muscles of limbs & digits
Spinal accessory	IX	C1-C6	Efferents in spinal root of accessory nerve (cranial nerve XI)

## Review: Spinal Cord Gray Matter

The spinal cord gray matter consists of glia, neuronal somata, dendrites and finely myelinated and unmyelinated axons that form an H shaped or butterfly-shaped central core.

For descriptive purposes, it is subdivided into the posterior gray columns, the anterior gray columns and a small middle zone, the intermediate gray column. These columns are frequently referred to as horns, e.g., the posterior horn. The gray commissure is not a true commissure and consists of neurons that form a thin band across the midline just dorsal to the white commissure. The white commissure is formed by fibers crossing from one side of the spinal cord to the other. A group of neurons with similar connections and functions is called a nucleus or nuclear column. Some nuclear columns extend the length of the spinal cord while others are found only at certain levels of the cord (DeArmond, Fig. 31, pg. 63, and Table 4-1 in this exercise).

The posterior/dorsal roots and the posterior/dorsal horn are associated with afferent pathways. The neurons providing afferent innervation to the body are the pseudounipolar cells located within the posterior/dorsal root ganglia. Pseudounipolar cells in certain cranial nerve ganglia provide the afferent innervation of the face. The peripheral processes of these cells form sensory receptor complexes in the skin, joints, periosteum, muscles, fascia and viscera. The vast majority of the central processes of posterior root ganglion cells enter the spinal cord in the posterior horn. Prior to entering the posterior horn, the posterior root fibers bifurcate and send ascending and descending branches in the posterolateral tract of Lissauer (Nolte, Fig. 10-22, page 248). Collaterals of these branches may terminate (i.e., make synaptic connection) in the gray matter within or near the segment of root entry, while others may ascend or descend to more distant regions. Some posterior root collateral fibers are of large diameter and ascend in the posterior funiculus of the spinal cord to terminate in brainstem levels.

The anterior/ventral horns (Fig. 4-2) contain the alpha and gamma motor neurons that innervate the somatic musculature. These multipolar neurons give rise to axons that form the anterior/ventral roots.



The larger alpha motor neurons innervate the skeletal (extrafusal) muscles of the body, while the smaller gamma motor neurons innervate the intrafusal muscle fibers in the muscle spindle receptor organ. All neurons that supply a particular muscle or muscle group tend to be located in the same motor neuron group or pool. Motor neurons located in the medial part innervate the trunk (proximal) musculature principally while motor neurons located in the lateral part innervate the limb (distal) musculature principally (Figure 4 1 of this exercise). In addition to this organization, the more posterior groups supply flexors and the more ventral groups the extensor muscles respectively.

The intermediate gray column contains interneurons, and autonomic neurons. The autonomic neurons form a discontinuous nuclear column. Those present at thoracic and upper lumbar levels form a small but prominent lateral horn at T1 through L2 or L3. These neurons are preganglionic sympathetic efferent cells, which send their axons out the anterior roots. The axons leave the roots in the white rami communicans to join the spinal sympathetic column. There they synapse on sympathetic ganglion cells (Nolte, Fig. 10-1 & 10-2, pp. 228-229). The postganglionic axons of the sympathetic ganglion cells travel to and terminate upon the target organ (Nolte, Fig. 10-28, p. 257). The cell bodies of preganglionic neurons of the parasympathetic system are located in a corresponding position in the intermediate gray of sacral segments S2, S3 and S4; but no lateral horn is present at these levels. The axons of these cells travel in the anterior root and spinal nerves to parasympathetic ganglia in or near their target organ (Nolte, Fig. 10-28, p. 257). The target organs are innervated by the postganglionic axons of these parasympathetic ganglia.

## Spinal Cord White Matter

---

The white matter of the spinal cord is composed of fiber tracts or fasciculi, containing myelinated and unmyelinated axons. The tracts or fasciculi, in turn, are grouped into large bundles of tracts called funiculi. The presence of many myelinated axons gives the outer rind of the spinal cord its whitish appearance in unstained specimens. Note that the microscopic slides are of myelin-stained nervous tissue. Consequently, the white matter appears darkly stained, while the gray matter appears light in contrast. In each half of the spinal cord, there is a posterior (dorsal), lateral, & anterior (ventral) funiculus (column) (Nolte, Fig. 10-8, pg. 236 and Fig. 4-1). These funiculi contain long fiber tracts, which are ascending or descending the spinal cord. The long ascending tracts consist of the axons originated from the posterior root ganglion cells that travel in the posterior funiculus (dorsal column); or of the axons of posterior horn neurons that travel mainly in the lateral & anterior funiculi and terminate in the brain stem, cerebellum or thalamus. The long descending tracts arise in the cerebral cortex or brainstem nuclei, travel in the lateral & anterior funiculi, and terminate in the spinal cord gray matter. Axons traveling within or between spinal cord segments ascend or descend the spinal cord in the posterolateral tract of Lissauer or in the fasciculus proprius. You will be learning the positions, origins and termination sites of the ascending and descending pathways in later exercises. At this time concentrate only on the tracts presented in bold type.

## Dorsal Posterior Column - Medial Lemniscus Pathway

---

The dorsal column-medial lemniscal pathway consists of a chain of neurons that includes 1° afferents of the posterior root ganglion, 2° afferents of the gracile and cuneate nuclei in the medulla, 3° afferents of the ventral posterolateral nucleus of the thalamus, and neurons in the postcentral gyrus of the parietal cortex. (See Nolte, Fig. 10-19, pg. 245) The neurons in this pathway carry and process discriminative touch and proprioceptive information from the body. The central processes of the 1° afferents ascend

the spinal cord in the posterior (dorsal) columns without crossing to terminate in the ipsilateral medulla on the 2° afferents in the gracile and cuneate nuclei. The axons of the 2° afferents decussate and collect to form the medial lemniscus in which they ascend to the thalamus contralateral to their cells of origin. These crossed 2° afferent axons terminate on 3° afferents in the ventral posterolateral nucleus (VPL) of the thalamus. The axons of the 3° afferents enter the posterior limb of the internal capsule, travel to and terminate in the postcentral gyrus of the parietal lobe, the primary somatosensory cortical receiving area.

### Review: Posterior Column/Medial Lemniscal Pathway

The medial lemniscal system is concerned with the more discriminative aspects of somatic sensation, such as accurate localization of tactile stimuli (discriminative touch), the sense of limb position and movement (proprioception), as well as temporal (vibratory sense) aspects of the somatic stimulus. The cell bodies of the 1° medial lemniscal afferents are located in posterior/dorsal root ganglia. The peripheral axons (A $\beta$ , AII and A Ia nerve fibers) of posterior root ganglion cells form somatosensory receptors: (1) encapsulated endings in skin, joints & tendons, (2) hair follicles and Merkel's cells, and (3) muscle spindles. The central axons of these 1° posterior column-medial lemniscal afferents enter the spinal cord in the medial division of the posterior root, branch and send collaterals into the gray matter, the tract of Lissauer, and the posterior funiculus. The 1° posterior column-medial lemniscal afferents from the coccygeal & S5 to T7 posterior roots form the gracile fasciculus and those from the T6 to C2 posterior roots form the cuneate fasciculus. These fibers ascend in the posterior funiculus ipsilateral to their cells of origin (pseudounipolar cells in the posterior root ganglia) up to the medulla (Nolte, Fig. 10 19, pg. 245). In the medulla, the 1° afferents terminate upon 2° afferents in the gracile nucleus for the gracile fasciculus and in the cuneate nucleus for the cuneate fasciculus. The axons of the 2° afferents pass anteriorly as internal arcuate fibers and cross the midline in the decussation of the medial lemniscus (which is also known as the sensory decussation). The medial lemniscus is made up of the crossed 2° somatosensory afferents of the posterior column-medial lemniscal pathway. These fibers ascend to the ventral posterolateral (VPL) nucleus of the thalamus to terminate upon VPL 3° somatosensory afferents. The axons of the VPL neurons enter the posterior limb of the internal capsule, pass through the corona radiata and terminate within the primary somatosensory cortex, i.e., the postcentral gyrus of the parietal cortex. Damage to this area of the cortex results the following sensory losses contralateral to the site of injury: (1) a lack of appreciation of vibratory stimuli, (2) poor cutaneous discrimination, and (3) diminished limb position and movement sense.

### Answers

- 4-1. Choroid plexus
- 4-2. Lateral, third and fourth ventricles.

## Review Exercise

---

Know the following structures:

- Posterior Column -- Medial Lemniscal Pathway:
- Meissner corpuscle (NeuroLab)
- Pacinian corpuscle (NeuroLab)
- Gracile fasciculus,
- Cuneate fasciculus
- Posterior intermediate sulcus
- Gracile nucleus
- Cuneate nucleus
- Internal arcuate fibers
- Medial lemniscus
- VPL of thalamus
- Posterior limb of internal capsule
- Postcentral gyrus of the parietal lobe
- Tract of Lissauer
- Anterior median fissure
- Nucleus proprius
- Substantia gelatinosa
- Posterior median fissure
- Anterior white commissure
- Intermediate gray
- Dorsal nucleus of Clarke
- Lateral corticospinal tract
- Spinothalamic tract
- Lateral horn
- Dorsal spinocerebellar tract

# Laboratory Exercise #5: Somatosensory, Viscerosensory and Spinocerebellar Pathways

Lecturer: Patrick Dougherty, Ph.D.

February 7, 2012 1:00 PM

## Required Reading

---

- Nolte, Chapter 10: Spinal Cord, pp. 227-265
- Nolte, pp. 306-313, Trigeminal Nerve

## Introduction

---

Recall that afferent pathways process information arising from the body and face and include peripherally located neurons and neurons in the central nervous system. The somatosensory systems (i.e., their anatomical pathways) are a subset of afferent systems that include neurons in the posterior root and cranial nerve ganglia, spinal cord, brain stem, thalamus and cerebral cortex. As the somatosensory pathways include the cerebral cortex, stimulation of somatosensory neurons results in the conscious perception of tactile, proprioceptive, painful or temperature sensations. Other afferent pathways, e.g., the spinocerebellar pathways, do not include the thalamus and cerebral cortex, and, when stimulated, do not give rise to conscious sensations. In addition, the somatosensory systems processing information about crude touch, pain and temperature involve anatomical pathways that differ from those processing information used in discriminative touch and proprioception.

In this Exercise, we will examine the following afferent pathways: A) spinothalamic pathways: processing pain, temperature and simple touch information from the body and viscera; B) trigeminal pathways: processing somatosensory information from the face and consisting of three parts: (1) the spinal sensory trigeminal pathway mediating crude touch, pain and temperature information, (2) the main sensory trigeminal pathway, a precisely topographically organized pathway mediating fine tactile discrimination and proprioception, and (3) the mesencephalic trigeminal pathway monitoring jaw position and movement; C) viscerosensory pathway: slow conducting, barely topographically organized, sensitive to mechanical, thermal and chemical stimulation of the viscera (i.e., internal body organs such as the bladder and gastrointestinal tract); and D) spinocerebellar pathways: “nonsensory” afferent pathways which include the posterior & anterior spinocerebellar pathways and cuneocerebellar pathway. There are excellent illustrations of these pathways in your required textbook by Nolte.

Table 5- I of this Exercise provides information concerning the major ascending tracts of the spinal cord. Table 5 -II provides a summary of the somatosensory pathways. Each ascending pathway is described separately from its point of origin (body or organs) to its point of destination in the brain. Each pathway is summarized in the text and tables. A review of the pathways covered in this Exercise is provided at the end of the chapter. At the end of this Exercise you should be able to:

1. Describe the course of major somatosensory and viscerosensory pathways from the receptors to the thalamus.
2. Describe the course of the spinocerebellar pathways.
3. Identify the relevant tracts and nuclei on the listed slides and DeArmond plates
4. Identify the location of the cell bodies and synapses of each pathway.

5. Identify where each pathway crosses the midline.
6. Name the sensory modalities carried by each pathway.

**NOTE: The shaded material is for review purposes.**

- **Part A**  
**Examination Of Wet Human Brain Material**
  1. Your row's human specimens
  2. Demonstration material presented by teaching assistants
- **Part B**  
**Complete Exercise Mode Of Laboratory #5 Of Neurolab**
  1. Each student should go through the NeuroLab computer program review mode prior to the laboratory.
- **Part C**  
**An Exercise At The End Of The Laboratory (~3:30 P.M.) To Assess Your Learning Progress.**
- **Part D**  
**Post-laboratory review using clinical Cases**

## Spinothalamic Pathways - Crude Touch, Pain And Temperature From The Body

---

### Materials

---

Use DeArmond Figs. # 32 to 37, 40, 42, to 44, 48, 49, 51, 52, 55 and 65. Brainiac, Pal-Weigert Section  
– Click on lumbo-sacral cord section 1-12 for spinal thalamic.

- Brain specimen bucket containing
  - Hemisected Brain
  - Spinal Cord
  - Brainstem
- Aluminum pan
- Squeeze bottles with water or bleach
- Cleanup towels for any dripping or spillage

### ***You need to bring:***

- Gloves
- Dissection kit
- You may want to bring an plastic apron to protect your clothes.

There are two spinothalamic pathways we will cover in this exercise that are chiefly concerned with pain and temperature sensations and with crude touch. The “fast” conducting neospinothalamic pathway is involved in conveying the “sharp/cutting” pain elicited at the time tissue is damaged. The “slower” conducting paleospinothalamic pathway is involved in conveying the “dull/burning” pain that

accompanies the later inflammatory reaction in the damaged tissue and temperature and crude touch information.

There is a third spinothalamic pathway, the archeospinothalamic pathway that is poorly defined and involved in a generalized sense of discomfort and diffuse pain.

The first-order ( $1^\circ$ ) afferents of the spinothalamic pathways are posterior root ganglion cells that send A-delta and c fibers to the periphery where they form free nerve endings in skin, muscle/tendon, joint capsules and viscera. The central processes of these  $1^\circ$  afferent neurons (pseudounipolar cells of the posterior root ganglia) enter the spinal cord in the lateral division of the posterior root. These axons branch and send fibers to the gray matter at the segment of entry and into the tract of Lissauer. The  $1^\circ$  afferents of the spinothalamic systems may end in the segment of root entry or one or two higher segments on  $2^\circ$  afferents in the nucleus posteromarginalis the neospinothalamics or on  $2^\circ$  afferents in the substantia gelatinosa the paleospinothalamics.

**Neospinothalamic Pathway:** The  $2^\circ$  neospinothalamic afferents (nucleus posteromarginalis axons) cross in the anterior white commissure to collect in the spinothalamic tract within the contralateral anterior and lateral (predominantly) funiculi (Nolte, Fig. 10-22, p. 248). These  $2^\circ$  neospinothalamic afferent axons ascend the spinal cord and brain stem in the spinothalamic tract to terminate on  $3^\circ$  afferents in the ventral posterolateral (VPL) nucleus of the thalamus. Note that these  $3^\circ$  neospinothalamic VPL afferents differ from the VPL neurons synapsing with  $2^\circ$  afferent axons of the medial lemniscus. The  $3^\circ$  neospinothalamic VPL neurons send their axons to the primary somatosensory cortex (i.e., the postcentral gyrus of the parietal lobe).

**Paleospinothalamic Pathway:** The  $2^\circ$  paleospinothalamic afferents (axons of the substantia gelatinosa) travel a short distance to terminate on  $3^\circ$  afferents in or near the ipsilateral nucleus proprius. While the axons of most paleospinothalamic  $3^\circ$  (nucleus proprius) afferents cross in the anterior white commissure, others remain uncrossed. Consequently, the  $3^\circ$  nucleus proprius afferents collect bilaterally in the spinothalamic tracts of the anterior (predominantly) and lateral funiculi. Along their ascending course to the thalamus, many of the paleospinothalamic  $3^\circ$  (nucleus proprius) afferents leave the spinothalamic tracts to terminate in the brain stem reticular formation or midbrain periaqueductal gray. The remaining paleospinothalamic  $3^\circ$  afferents remain in the spinothalamic tracts and ascend to terminate on  $4^\circ$  paleospinothalamic afferents in the intralaminar nuclei of the thalamus. The projections of the intralaminar nuclei axons ( $4^\circ$  paleospinothalamic afferents) are to diffuse areas of the cerebral cortex which are believed to play a role in poorly localized sense of pain. For example, destruction of the primary somatosensory cortex (i.e., the postcentral gyrus of the parietal lobe) does not seem as detrimental to the appreciation of painful stimuli as it is to the appreciation of other somatic sensations.

## Spinothalamic And Spinal Sensory Trigeminal Pathways

Pain, temperature and crude touch from Body: Spinothalamic Pathways From Face: Spinal Trigeminal Tract and Nucleus of the Trigeminal System

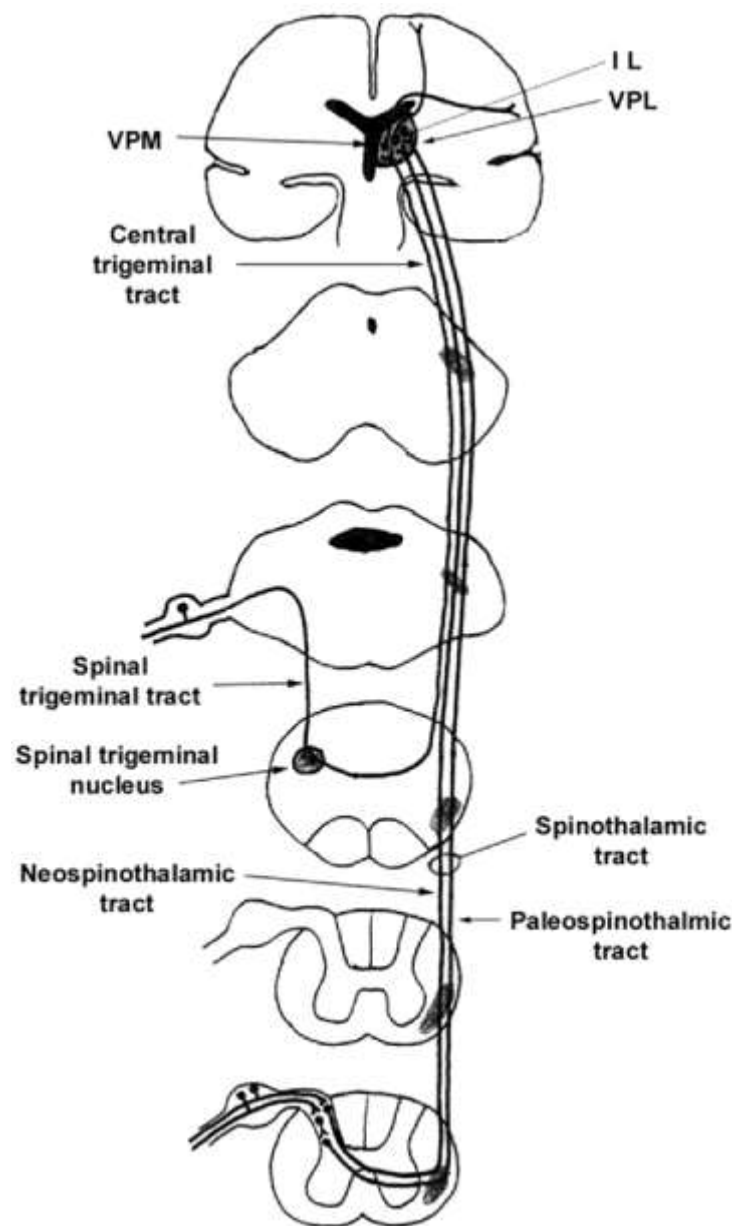


Figure 5-1. Spinothalamic and Spinal Sensory Trigeminal Pathways

IL = intralaminar thalamic nuclei

VPM =Ventral PosteroMedial nucleus of thalamus

VPL =Ventral PosteroLateral nucleus of thalamus

Syringomyelia is a disease, which causes a softening or cavitation of the spinal cord anterior white commissure. Typically the lesion is around the central canal and most often anterior to it. Syringomyelia produces bilateral deficits in pain and temperature in the body areas innervated by the affected cord segments. For example, syringomyelia affecting spinal segments C8-C4 would produce a bilateral deficit in pain and temperature in both arms, hands and fingers. This results from the destruction of the crossing fibers of the spinothalamic pathways in the anterior white commissure of spinal segments C8-C4.



## Spinal Trigeminal Pathway

---

Crude touch, pain and temperature from the face

### Materials

---

Use DeArmond figures and Brainiac, Pal-Weigert Sections. Use Figure 12-18 from Nolte (page 311) to help gain an appreciation of the three dimensional organization of this pathway.

The spinal trigeminal pathway, the cranial homologue of the spinothalamic pathway, mediates crude touch, pain and temperature from the face (Nolte, Fig. 12-18, p. 311). Somatosensory information from the face and dura travels via four cranial nerves: the trigeminal (V) nerve, facial (VII) nerve, glossopharyngeal (IX) nerve and the vagus (X) nerve. Recall that some afferent fibers in the facial, glossopharyngeal and vagus nerves carry somatosensory information from the ear (pinna, external auditory meatus, tympanic membrane, and middle ear cavity) and posterior dura. The central processes of the 1° afferent neurons carrying information about simple touch, pain and temperature from the face and dura enter the spinal trigeminal tract and terminate on 2° afferents in the spinal trigeminal nucleus (Nolte, Fig. 12-18, p. 311)<sup>1</sup>. Most of the 2° afferent axons from the spinal trigeminal nucleus decussate and form the contralateral ventral trigeminal lemniscus (called the ventral trigeminothalamic tract by DeArmond). The 2° afferent fibers ascend in the ventral trigeminal lemniscus to the thalamus where they terminate on 3° afferents in the ventral posteromedial nucleus (VPM, the A delta fibers) or intralaminar nuclei of the thalamus (the c fibers). The axons of these 3° afferents (VPM neurons only) ascend in the posterior limb of the internal capsule and terminate in the postcentral gyrus of the parietal lobe. The afferent fibers originating from the intralaminar nuclei terminate in more diffuse cortical areas.

<sup>1</sup>Nolte (pp. 306-313) describes the 2° spinal trigeminal afferent axons as ascending to the thalamus with the spinothalamic tract.



## Main Sensory Trigeminal Pathway

---

Face discriminative touch & proprioception

### Materials

---

Use DeArmond figures and Brainiac, Pal-Weigert Sections. Use Figure 12-16 from Nolte (page 309) to help gain an appreciation of the three dimensional organization of this pathway.

The main sensory trigeminal pathway, the cranial homologue of the medial lemniscal pathway, mediates discriminative touch and proprioception from the face (Nolte, Fig. 12-16, p. 309). Somatosensory information from the face and dura travels via four cranial nerves: the trigeminal (V) nerve, facial (VII) nerve, glossopharyngeal (IX) nerve and the vagus (X) nerve. Recall that some afferent fibers in the facial, glossopharyngeal and vagus nerves carry somatosensory information from the ear (pinna, external auditory meatus, tympanic membrane, and middle ear cavity). The central processes of the 1° afferent neurons carrying information processed for discriminative touch and proprioception from the face terminate on 2° afferents in the main sensory trigeminal nucleus. Most of the 2° afferent axons from the main sensory trigeminal nucleus decussate and join the contralateral ventral trigeminal lemniscus (also called the ventral trigeminothalamic tract). The 2° afferent fibers ascend in the ventral trigeminal lemniscus to the thalamus where they terminate on 3° afferents in the ventral posteromedial nucleus (VPM) of the thalamus. The axons of these 3° afferents, ascend in the posterior limb of the internal capsule and terminate in the postcentral gyrus of the parietal lobe.

## Visceral Afferent Pathways

---

Mechanical, Thermal, and Chemical Information from Viscera

### Materials

---

Use DeArmond figures and Brainiac, Pal-Weigert Sections Use Figure 10-19 (page 243), Figure 12-27 (page 314) and Figure 12-28 (page 314) to help gain an appreciation of the three dimensional organization of these pathways.

The vast majority of visceral afferents and the pathways they form are not sensory in function. They are an integral part of the autonomic system and serve to provide information important for regulating cardiovascular, respiratory, digestive, reproductive, etc. functions.

The cell bodies of 1° viscerospinal afferents are located in the posterior root ganglia of the sacral, lumbar and thoracic spinal cord. Recall from Gross Anatomy that the peripheral axons of visceral 1° afferent fibers travel in somatic, sympathetic and parasympathetic nerves to their target sites. Some of the posterior root ganglion cells of the sacral segments give rise to axons that travel in the sacral parasympathetic nerves to the abdominal & pelvic viscera, and convey perceived sensations such as gut and bladder distention. Many visceral sensory neurons at upper lumbar levels (L2-L1) monitor the condition of the blood vessels, glands and viscera in the lower extremities and pelvic region. The visceral 1° afferents of the thoracic segments travel in the thoracic sympathetic nerves to innervate the blood vessels, glands, and visceral organs of the neck, upper extremities, chest and abdominal cavities. There are few visceral afferents in cervical segments.

The cell bodies of 1° viscerocranial afferents are located in the cranial nerve ganglia of the vagus and glossopharyngeal nerves. The visceral 1° afferents of the vagus and glossopharyngeal nerves travel in parasympathetic nerves to their terminal sites. The visceral 1° afferents of the vagus (X) nerve innervate the thoracic and abdominal viscera, while those of the glossopharyngeal (IX) nerve innervate the pharynx, tonsil, carotid sinus and carotid body.

The cell bodies of the visceral 1° afferents are located in the posterior root ganglia and in the petrosal ganglion (IXth nerve) and nodose ganglion (Xth nerve). The course of the spinal viscerosensory pathway is similar to that of the paleospinothalamic (See part A of this Laboratory Exercise & Nolte, Fig. 10-22, p. 248). The central axons of the 1° cranial visceral afferents enter the medulla, travel in the tractus solitarius and synapse in the caudal two-thirds of the nucleus solitarius (2° cranial visceral afferents). Many of the higher order visceral afferents end in the brain stem and are involved in initiating and regulating autonomic functions. Few of the visceral afferents (3° spinal and 2° cranial viscerosensory afferents) reach the thalamus where they terminate in the intralaminar nuclei. While the intralaminar nuclei project diffusely to the cortex, part of the insular cortex has been identified as a cortical visceral sensory area.

## Spinocerebellar Pathways

### Unconscious Proprioception

#### Materials

Use DeArmond figures and Brainiac, Pal-Weigert Sections are indicated in the following text. Use Figure 10-23 from Nolte (page 250) to help gain an appreciation of the three dimensional organization of these pathways.

There are three different pathways that carry proprioceptive information from the body to the cerebellum (Nolte, Table 10-5, p. 251): (1) the posterior/dorsal spinocerebellar pathway carries information from the lower body (S5 to T1) and enters the cerebellum via the inferior cerebellar peduncle; (2) the cuneocerebellar pathway carries information from the upper body (C8 to C2) and also enters the cerebellum via the inferior cerebellar peduncle<sup>2</sup>; and (3) the anterior/ventral spinocerebellar pathway carries both unconscious proprioceptive and cutaneous information from the lower body (L5 to T12) and enters the cerebellum via the superior cerebellar peduncle.

The cell bodies of the 1° afferents are located in the posterior root ganglia of the spinal cord. Most of the 1° afferents conveying unconscious proprioceptive information from muscle and joint receptors in the body travel to the cerebellum in the posterior spinocerebellar and cuneocerebellar tracts, which remain ipsilateral throughout their entire extent (Nolte, Fig. 10-23, p. 250). In the posterior spinocerebellar pathway, 1° afferents from the lower body make their first synapse in the dorsal nucleus of Clarke. As this nucleus is found only in cord segments L3 to C8, 1° afferents from lower segments must ascend in the gracile fasciculus to reach it. The posterior spinocerebellar 2° afferents ascend the cord uncrossed in the ipsilateral lateral funiculus as the posterior spinocerebellar tract. These 2° afferents join the inferior cerebellar peduncle and terminate in the ipsilateral cerebellum.

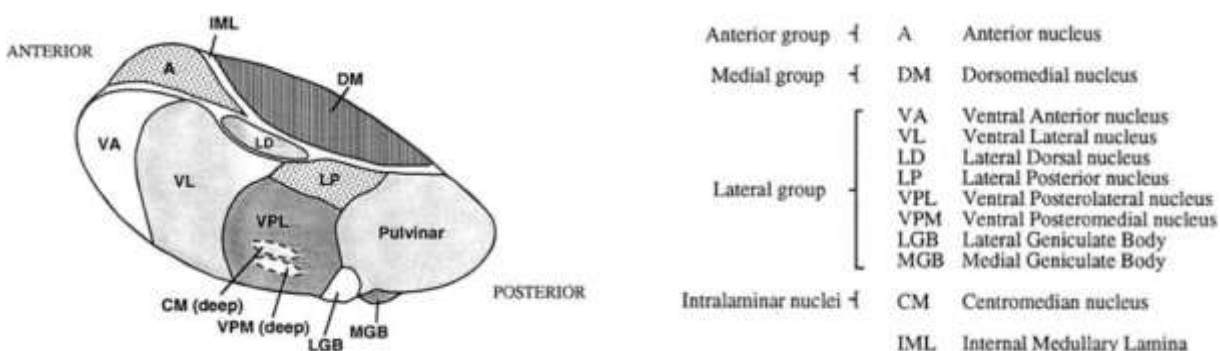
In the cuneocerebellar pathway, the 1° afferent fibers enter the cord in the cervical posterior roots, join the cuneate fasciculus in which they ascend to the lateral cuneate nucleus where they terminate. The axons of the 2° afferents, the cuneocerebellar tract, join the inferior cerebellar peduncle to travel to and terminate in the ipsilateral cerebellum. In the anterior spinocerebellar pathway, 1° afferents conveying unconscious proprioceptive information from Golgi tendon organs and muscle spindle Group II fibers of the leg and trunk terminate on anterior horn neurons called spinal border cells. These cells, found at cord levels L5 to T12, also synapse with 1° cutaneous afferents, spinal interneurons, and descending tracts. The axons of the spinal border cells, 2° anterior spinocerebellar afferents, decussate and form the anterior spinocerebellar tract at the posterolateral border of the anterior funiculus. These fibers ascend to midbrain levels where they join the superior cerebellar peduncle and descend back down to the cerebellum. Before the anterior/ventral spinocerebellar tract fibers terminate, they decussate again and terminate in the cerebellum ipsilateral to the body part represented. Consequently, there is a double cross in this pathway, one at the level of the tract's cells of origin, i.e., the spinal border cells, and a second one in the cerebellum.

<sup>2</sup>Both of these terminate in the cerebellum ipsilateral to the body part represented.

**TABLE 5-I: ASCENDING TRACTS IN THE SPINAL CORD**

Tracts	X/UNX	N °	Cells of Origin	Terminates	Functions
Dorsal Column: Gracile fasciculus	UNX	1°	Dorsal Root Ganglion (S5-T7)	Gracile nucleus	Discriminative Touch & Proprioception
Dorsal Column: Cuneate fasciculus	UNX	1°	Dorsal Root Ganglion (T6-C2)	Cuneate nucleus	Discriminative Touch & Proprioception
Spinothalamic: Neospinothalamic	X in Cord	2°	Nucleus Posteromarginalis	VPL of Thalamus	Sharp, cutting Pain
Spinothalamic: Paleospinothalamic	UNX & X in Cord	3°	Nucleus Proprius	RF, PP & Intralaminar Nuclei of Thalamus	Dull pain, Temperature, Simple touch, Visceral
Spinothalamic: Archeospinothalamic, Spinoreticular, & Spinomesencephalic	UNX & X in Cord	3°+	Nucleus Proprius to Intermediate Gray & Anterior Horn	RF, PP & Intralaminar Nuclei of Thalamus	Discomfort, Diffuse pain
Posterior Spinocerebellar	UNX	2°	Clarke's Nucleus	Cerebellum	Unconscious Proprioception
Dorsal Column: Cuneate fasciculus	UNX	1°	Dorsal Root Ganglion (C8-C2)	Lateral Cuneate Nucleus	Unconscious Proprioception
Anterior Spinocerebellar	X in cord	2°	Spinal Border cells (T12 to L5)	Cerebellum where X again	Unconscious Proprioception

KEY: UNX, uncrossed; X, crossed; C, cervical; T, Thoracic; L, Lumbar; S, Sacral; RF, Reticular Formation; PP, Periaqueductal Gray; VPL, Ventral PosteroLateral nucleus.

*Figure 5.5 Thalamic Nuclei*

**TABLE 5-II: SOMATOSENSORY PATHWAYS**

<b>Pathway</b>	<b>1° Neuron</b>	<b>2° Neuron</b>	<b>3° Neuron</b>	<b>Thalamus</b>	<b>Cortex</b>
Medial Lemniscal	Dorsal Root Ganglia	Gracile and Cuneate Nuclei	VPL	VPL	Postcentral Gyrus
Neospinothalamic	Dorsal Root Ganglia	Nucleus Posteromarginalis	VPL	VPL	Postcentral Gyrus
Paleospinothalamic	Dorsal Root Ganglia	Substantia Gelatinosa	Nucleus Proprius	Intralaminar Nuclei	Diffuse areas
Spinovisceral	Dorsal Root Ganglia (sacral, upper lumbar & thoracic)	Substantia Gelatinosa	Nucleus Proprius	Intralaminar Nuclei	Insula & Diffuse areas
Archeo-spinothalamic	Dorsal Root Ganglia	Substantia Gelatinosa	Nucleus Proprius	Intralaminar Nuclei	Diffuse areas
Trigeminal: Main Sensory	Cranial Nerve Ganglia (V, VII, IX, X)	Main Sensory Trigeminal Nucleus	VPM	VPM	Postcentral Gyrus
Trigeminal: Spinal	Cranial Nerve Ganglia (V, VII, IX, X)	Spinal Trigeminal Nucleus	VPM & Intralaminar Nuclei	VPM & Intralaminar Nuclei	Postcentral Gyrus & Diffuse areas
Trigeminal: Mesencephalic	Mesencephalic Trigeminal Nucleus	Trigeminal motor Nucleus (jaw jerk reflex)			
Craniovisceral	Cranial Nerve Ganglia (IX, X)	Solitary Nucleus	Intralaminar Nuclei	Intralaminar Nuclei	Insula & Diffuse areas

## Review Of CNS Ascending Pathways

### A. Spinothalamic Pathways

The spinothalamic pathways are chiefly concerned with pain and temperature sensations. They also mediate tactile sensations (called simple or crude touch) that, in the absence of the posterior funiculi, are difficult to localize or identify as to their quality, i.e., as rough or smooth, vibrating, moving stimuli. The spinothalamic pathway can be subdivided into a “fast” conducting neospinothalamic pathway (Nolte, Fig, 10-22, p. 248) and a “slow” conducting paleospinothalamic pathway. The neospinothalamic pathway is involved in conveying the “sharp/cutting” pain elicited at the time tissue is damaged. The paleospinothalamic pathway is involved in conveying the “dull/burning” pain that accompanies the later inflammatory reaction in the damaged tissue. Temperature and simple touch information are probably carried in a subdivision of the paleospinothalamic pathway. The 1° afferents of the spinothalamic pathways send A delta and C fibers to the periphery where they form free nerve endings in skin, muscle/tendon, joint capsules and viscera. The central processes of these neurons (pseudounipolar cells of the posterior root ganglia) enter the spinal cord in the lateral division of the posterior root. The axons branch and send fibers to the gray matter at the segment of entry and in the tract of Lissauer. The 1° afferents of the spinothalamic systems may end in the segment of entry or one or two segments up on 2° afferents in the nucleus posteromarginalis the neospinothalamics or on 2° afferents in the substantia gelatinosa the paleospinothalamics.

The axons of the nucleus posteromarginalis (neospinothalamic 2° afferents) cross in the anterior white commissure to collect in the spinothalamic tract within the contralateral anterior and lateral funiculi. The axons of the substantia gelatinosa (2° paleospinothalamic afferents) travel a short distance to terminate in or near the nucleus proprius on 3° afferents. The axons of some of the 3° nucleus proprius afferents remain uncrossed or cross in the anterior white commissure to collect bilaterally in the spinothalamic tracts of the anterior and lateral funiculi. These spinothalamic tracts are often referred to collectively as the anterolateral spinothalamic tract. Along their course to the thalamus, many fibers leave the spinothalamic tracts to terminate in the reticular formation or periaqueductal gray. Nolte refers to the fibers terminating in the reticular formation as spinoreticular fibers and those ending in the periaqueductal gray as spinomesencephalic fibers. The remaining spinothalamic tract fibers either ascend up to the ventral posterolateral (VPL) nucleus of the thalamus to terminate on 3° (neospinothalamic) afferents, or to the intralaminar nuclei of the thalamus to terminate on 4° (paleospinothalamic) afferents. The neospinothalamic fibers do not terminate on the same group of VPL neurons that receive medial lemniscal fibers; i.e., pain, temperature, simple touch information is kept separate from the discriminative touch and proprioceptive information. Although the spinothalamic VPL neurons send their axons to the primary somatosensory cortex (i.e., the postcentral gyrus of the parietal lobe), destruction of this cortical area does not seem as detrimental to the appreciation of painful stimuli as it is to the appreciation of other somatic sensations. The projections of the intralaminar nuclei to more diffuse areas of the cerebral cortex are believed to play a role in a more poorly localized sense of pain.

### B. Trigeminal Sensory Systems

The somatic innervation of the face area (i.e., the skin, muscles and joints of the face, the mucous membranes of the oral, nasal and ear cavities, the teeth, jaw, and the dura) is provided by four cranial nerves: The trigeminal nerve innervates most of the face area, while the facial, glossopharyngeal & vagal nerves provide somatic innervation to the oral and ear cavities and the skin covering the ear. The cell bodies of the 1° afferents are located in the ganglia of these nerves and their central processes enter

the brain stem in the cranial nerve roots. Once in the brain stem, the fibers branch and send collaterals to cranial motor nuclei (reflex responses), to the reticular formation, and into the spinal trigeminal tract or to the main sensory trigeminal nucleus (Nolte, Figs. 12-16 and 12-18, p. 309 and 311). The 1° afferents ending in the main sensory trigeminal nucleus are homologues of the 1° afferents of the medial lemniscal pathway: They convey discriminative touch & proprioceptive information. The 1° afferents descending in the spinal trigeminal tract are the homologues of the 1° afferents of the spinothalamic tracts: They convey pain, thermal & simple touch information. The 2° main sensory trigeminal nucleus axons decussate and collect in the contralateral ventral trigeminal lemniscus. The 1° afferents in the spinal trigeminal tract leave the tract as it descends towards the spinal cord to terminate on 2° neurons in the spinal trigeminal nucleus. The 2° axons of the spinal trigeminal nucleus also decussate and collect in the contralateral ventral trigeminal lemniscus. The innervation of the jaw joints and muscles is unique in having the cell bodies of the 1° afferents located within the brain stem in the mesencephalic trigeminal nucleus. The fibers of the ventral trigeminal lemniscus ascend to and terminate in the ventral posteromedial (VPM) nucleus of the thalamus (main sensory trigeminal afferents and sharp pain component of spinal trigeminal afferents) or in the intralaminar nuclei of the thalamus (dull pain, temperature & simple touch components of spinal trigeminal afferents). The axons of the VPM 3° afferents ascend in the posterior limb of the internal capsule to the primary somatosensory cortex (the postcentral gyrus) of the parietal lobe. The axons of the intralaminar nuclei travel to more diffuse areas of the cerebral cortex.

### **C. Viscerosensory Systems**

The internal organs of the body (i.e., the viscera), the blood vessels, and the membranes lining the body wall and in the body cavities are also richly innervated by free nerve endings. Most of the stimuli, which activate the afferents forming these free nerve endings, are never consciously perceived. They function to initiate and regulate visceromotor functions on an unconscious level. For example, normally we are unaware of our blood gas levels, heart rate, and blood pressure, although these are monitored continually by the visceral afferents. These afferents provide the autonomic system with the information necessary to regulate respiratory and cardiovascular mechanisms to maintain the required blood gas levels, heart rate and blood pressure. The viscerosensory pathways, we define here, involve those parts of the visceral afferent system which ultimately terminate in the cerebral cortex and which when stimulated result in a conscious sensory perception. Gut and bladder distensions are normally perceived. Other viscerosensory afferents may convey information about the distention and inflammation of tissues that result in a general sense of discomfort and pain. The viscerosensory system involves two pathways, a spinal pathway with 1° afferents in the posterior root ganglia of the sacral, upper lumbar and thoracic segments and a cranial pathway with 1° afferents in the cranial (inferior) ganglia of the glossopharyngeal and vagus nerves. The 1° afferents are pseudounipolar cells that give rise to A fibers or C fibers. These fibers travel in the posterior or cranial root and in somatic, sympathetic, or parasympathetic nerves to terminate on the target organs. The central processes of the posterior roots are believed to terminate in the substantia gelatinosa of the spinal cord, while those of the glossopharyngeal and vagus nerves terminate in the nucleus solitarius of the medulla. Within the spinal cord, the 2° substantia gelatinosa neurons send their axons a short distance to the nucleus proprius where they terminate on 3° neurons. It is believed that many of the 2° and/or 3° neurons are also innervated by somatic afferents, and thus are multimodal in function. The axons of the 3° spinal viscerosensory afferents appear to ascend the neuraxis bilaterally in or near the spinothalamic tract and in the fasciculus proprius. Many of these fibers terminate in the brainstem reticular formation and midbrain periaqueductal gray. The remainder terminates in the intralaminar nuclei of the thalamus. The cranial



viscerosensory component has the cell bodies of its 2° afferents located in the more caudal regions of the nucleus solitarius. Like the spinal component, most of the axons of these afferents end in the brainstem reticular formation and few reach the intralaminar nuclei of the thalamus. The thalamic afferents send their fibers in the posterior limb of the internal capsule and project diffusely to the cortex. A cortical primary receiving area for visceral sensation has been identified in the insular cortex near the insular gustatory receiving area (Nolte, Fig. 23-25, p. 605).

#### **D. Spinocerebellar Pathways**

Three spinocerebellar pathways are examples of afferent pathways that are not sensory in function: They terminate in the cerebellum (and not in the cerebral cortex) and when stimulated do not elicit a perceived sensation (Nolte, Table 10-5, p. 251). Damage to these pathways does not produce significant sensory deficits but does produce deficits in motor function. The two major spinocerebellar pathways are the posterior spinocerebellar pathway and the cuneocerebellar pathway (Nolte, Fig. 10 -23, p. 250). The 1° afferents are the posterior root ganglion cells that innervate muscle and joint receptors (primarily) and skin receptors (A1a, A1b, A II & A  $\beta$  fibers). Branches of these afferents ascend in the gracile fasciculus of the sacral and lower lumbar spinal cord to the 2° afferents in the dorsal nucleus of Clarke which is located only at spinal cord levels L3 C8. The 1° afferents from the upper lumbar and thoracic spinal cord pass directly to the dorsal nucleus of Clarke in their segment of root entry. These 1° afferents (i.e., from coccygeal to C8) terminate in the dorsal nucleus of Clarke, whose axons pass to the ipsilateral lateral funiculus to form the posterior spinocerebellar tract. This tract ascends the spinal cord uncrossed, enters the inferior cerebellar peduncle in the medulla and terminates in the cerebellum. The 1° afferents from the cervical spinal segments pass into the cuneate fasciculus and also ascend the spinal cord without decussating. These afferents terminate on 2° afferents in the lateral cuneate nucleus of the medulla. The axons of these 2° afferents enter the inferior cerebellar peduncle to travel to and terminate in the ipsilateral cerebellum.

A third, minor, pathway is the anterior spinocerebellar pathway. It conveys more complex information from the leg to the cerebellum: Golgi tendon organs (predominantly), muscle spindle afferents, and cutaneous receptors send afferents to the 2° afferents, the spinal border cells, which are only found in the anterior horn of cord levels L5 to T12. These 2° afferents also synapse with spinal interneurons and descending tract fibers. The 2° anterior spinocerebellar afferents cross in the spinal cord and ascend the cord in the anterior funiculus as the anterior spinocerebellar tract. The anterior spinocerebellar tract ascends to the rostral pons where it joins the superior cerebellar peduncle to descend to the cerebellum. Within the cerebellum, the anterior spinocerebellar tract fibers cross again and terminate in the cerebellum ipsilateral to the body area represented.



## Brain Specimen Review

---

Identify the following structures on your specimens:

1. Hemisected brain to identify somatosensory cortical areas
  - Primary Somatosensory Cortex
    - Postcentral gyrus & posterior paracentral lobe (medial extension of postcentral gyrus on medial surface of cortex)
  - Secondary Somatosensory Cortex
    - Pars opercularis of postcentral gyrus (Postcentral gyrus forming the "upper lip" of the lateral fissure)
  - Somatosensory Association Cortex
    - Posterior (superior) parietal cortex (areas 5 & 7)
    - Superior temporal cortex (area 38 lower aspect of superior temporal lobe)
  - "Primary" Viscerosensory Cortex
    - Insular cortex
2. Spinal Cord
  - Posterior & Anterior Roots
  - Posterior root ganglia
  - Cervical & lumbar enlargements
  - Conus medullaris, Filum terminale & coccygeal ligament
  - Cauda equina

Blood supply

  - Anterior spinal artery
  - Posterior spinal artery

Spinal Meninges

  - Dura
  - Denticulate ligaments
  - Filum terminal
  - Coccygeal ligament
3. Brainstem
  - Gracile and Cuneate turbercule

## Structures To Identify

---

**Know the following structures:**

- Spinothalamic Pathways (from Laboratory 4):
  - Tract of Lissauer
  - Nucleus posteromarginalis
  - Substantia gelatinosa
  - Nucleus proprius
  - Anterior white commissure
  - Anterolateral or Spinothalamic tract
  - Spinoreticular tract
  - Propriospinal tract
  - Reticular formation

- Periaqueductal gray
- VPL
- Intralaminar nuclei of thalamus (Centromedian nucleus & Nucleus parafascicularis)
- Posterior limb of internal capsule
- Posterior Dorsal Column -- Medial Lemniscal Pathway:
  - Gracile fasciculus
  - Cuneate fasciculus
  - Posterior intermediate sulcus
  - Gracile nucleus
  - Cuneate nucleus
  - Internal arcuate fibers
  - Medial lemniscus
  - Posterior limb of internal capsule
  - VPL
- Trigeminal Pathways:
  - Spinal trigeminal tract and nucleus
  - Ventral trigeminothalamic tract
  - Main (or principal) sensory trigeminal nucleus
  - Mesencephalic trigeminal nucleus and tract
  - VPM
  - Intralaminar nuclei of thalamus
  - Posterior limb of internal capsule
- Viscerosensory Pathway:
  - Substantia gelatinosa
  - Nucleus proprius
  - Anterior white commissure
  - Spinothalamic tract
  - Solitary tract and nucleus
  - Central tegmental tract
  - Reticular formation
  - Intralaminar nuclei of thalamus
- Spinocerebellar pathway:
  - Gracile fasciculus
  - Dorsal nucleus of Clarke
  - Posterior spinocerebellar tract
  - Anterior spinocerebellar tract
  - Cuneate fasciculus
  - Lateral cuneate nucleus
  - Cuneocerebellar tract
  - Inferior cerebellar peduncle
  - Superior cerebellar peduncle
- Gross Structure Identification:
  - Somatosensory, Viscerosensory & Spinocerebellar Pathways
  - Spinal Cord
  - Dorsal & Ventral Roots
  - Dorsal Root Entry Zone

- Ventral Median Fissure
- Dorsal Medial Sulcus
- Dorsal Intermediate Sulcus
- Dorsolateral Sulcus
- Funiculus Gracilis
- Funiculus Cuneatus
- Dorsolateral Funiculus
- Anterolateral Funiculus
- Medulla
- Ventral Median Sulcus
- Ventral Lateral Sulcus
- Inferior Olive
- Supra-Olivary Sulcus
- Vagus Nerve
- Dorsal Medial Sulcus
- Funiculus Gracilis
- Funiculus Cuneatus
- Gracile Tubercle
- Cuneate Tubercle
- Tuberculum Cinereum
- Obex
- Pyramidal Decussation
- Inferior Cerebellar Peduncle
- Trigeminal Nerve
- Superior Cerebellar Peduncle
- Forebrain
- SI Cortex
- SII Cortex
- Insular Cortex
- Hypothalamic Sulcus
- Anterior Cingulate Cortex
- Internal Capsule
- Posterior Limb

## Review Questions

---

- 5-1. Damage to the left spinothalamic tract would result in analgesia in which side of the body?
- 5-2. Will section of the posterior funiculus result in a loss of all touch sensations from the buttocks and leg?
- 5-3. At which cord segments does Clarke's Nucleus occur?
- 5-4. If the right posterior funiculus were sectioned, on which side of the body is the sensory loss?
- 5-5. How does the viscerosensory pathway compare to the paleospinothalamic pathway with respect to ipsilateral/contralateral/bilateral organization?
- 5-6. How do the 1° afferents from sacral and lower lumbar levels reach the dorsal nucleus of Clarke?
- 5-7. Why do the thoracic anterior horns appear to be smaller than at lumbar levels?
- 5-8. The axons from the dorsal nucleus of Clarke travel to the (ipsilateral/contralateral) lateral funiculus and ascend the spinal cord as what tract?
- 5-9. What somatosensory deficits would be produced by syringomyelia affecting spinal segments C8-C4?
- 5-10. Where do the discriminative touch fibers in the gracile and cuneate fasciculi terminate?
- 5-11. What are the relationships between the gracile and cuneate nuclei and the tuberculi gracilis & cuneatus?
- 5-12. Which cranial nerves exit the medulla at the postolivary sulcus? At the preolivary sulcus?
- 5-13. Axons of what order travel in the medial lemniscus?
- 5-14. Fibers carrying sensory information from the face for discriminative touch and proprioception terminate in what thalamic nucleus?

## Answers

---

- 5-1. Right side
- 5-2. Not if the spinothalamics are spared
- 5-3. C8 to L3
- 5-4. Right side
- 5-5. It is bilateral while the spinothalamics are predominantly contralateral
- 5-6. They ascend in the gracile fasciculus
- 5-7. Thoracic anterior horn cells innervate trunk muscles that do not have a high density of innervation
- 5-8. Ipsilateral & posterior spinocerebellar
- 5-9. A bilateral deficit in pain and temperature sense from the arms, hands and fingers
- 5-10. Nuclei gracilis and cuneatus
- 5-11. They underlay the tuberculi
- 5-12. Spinal accessory, vagus & glossopharyngeal nerves at the post olivary sulcus and the hypoglossal at the preolivary sulcus.
- 5-13. Second order discriminative touch and proprioception
- 5-14. VPM

# Laboratory Exercise #6: Auditory, Vestibular, Gustatory and Olfactory Systems

Lecturer: Terry Crow, Ph.D.

February 21, 2012 1:00 PM

## Required Reading

---

- Nolte, Chapter 13
- Nolte, Chapter 14

## Introduction

---

The purpose of today's exercise is to introduce you to the structure of the auditory, vestibular, gustatory, and olfactory systems. The auditory system is an exteroceptive system involved in the perception of sound. The vestibular system is a proprioceptive system involved in the perception of the position and movement of the head with respect to the force of gravity. The receptors of the auditory and vestibular systems are modified epithelial cells that are located within the ear. The gustatory system, although classically called a special visceral system, is an exteroceptive system involved in the perception of the flavors/tastes of solids and liquids ingested into the oral cavity. The taste receptors are also specialized epithelial cells which are located in the oral cavity. The olfactory system is a chemosensory system responsive to air borne chemicals. The olfactory system is considered one of the most primitive of the sensory systems. It is directly involved with the limbic system and is often grouped with it in discussions of structure and function. At the end of this exercise you should be able to:

1. Recall the major components of the receptor organs.
  2. Identify the major nuclei and tracts of the ascending pathways.
  3. Describe other important "non sensory" connections involved in feedback or reflex pathways.
- **Part A**  
**Examination Of Wet Human Brain Material**
    1. Your human specimens
    2. Demonstration material presented by teaching assistants
  - **Part B**  
**Complete Exercise Mode Of Laboratory #6 Of Neurolab**
    1. Each student should go through the NeuroLab computer program review mode prior to the laboratory.
  - **Part C**  
**An Exercise At The End Of The Laboratory (~3:30 P.M.) To Assess Your Learning Progress**
  - **Part D**  
**Post-Laboratory Review Using Clinical Cases**

## Materials

---

You should use the following figures in DeArmond (Figs # 2, 3, 44, 45, 47, 48, 51, 54, 65, 70, 71) and in Nolte, (Figs. # 13-2, 13-4, 13-6, 13-8, 13-10, 13-17, 13-19, 14-1, 14-9, 14-11, , 14-18, 14-24, 14-29) to help you identify these structures. Preceding each numbered section. As in other exercises, learn to identify the names, locations, connections, and functions of the structures.

- Brain specimen bucket containing
  - Hemisected brain specimen
- Aluminum pan
- Squeeze bottles with water or bleach
- Cleanup towels for any dripping or spillage

### *You need to bring:*

- Gloves
- Dissection kit
- You may want to bring an plastic apron to protect your clothes.

## Peripheral Components

---

A review of the peripheral receptor organs of the four sensory systems is provided in Section 6.3 of this exercise.

### Auditory Receptor Organ

---

The auditory system is an exteroceptive system involved in the perception of sound. The receptor organ includes the outer, middle and inner ears. The outer ear consists of the pinna and external auditory canal or meatus. The middle ear is an air-filled bony chamber that is partitioned from the outer ear by the tympanic membrane or eardrum. The middle ear ossicles (a chain of three small bones in the middle ear cavity) conduct sound energy from the tympanic membrane to the inner ear. The auditory portion of the inner ear is a fluid-filled bony chamber, the cochlea, which contains a membranous, fluid-filled cochlear duct (Nolte, Fig. 14-1, p. 3438 and 14-9, p. 352). The receptor cells are located in the organ of Corti within the cochlear duct.

The cochlear duct has a triangular shape; its three walls formed by the basilar membrane, the stria vascularis and the vestibular or Reissner's membrane. The bony cochlear canal is divided in half by the osseous & membranous spiral lamina. The osseous spiral lamina is a bony ridge extending from the modiolus into the cochlear canal. The membranous spiral lamina or basilar membrane is a fairly thick membrane that extends from the osseous spiral lamina to the outer cochlear wall. A thickening of the soft tissue overlying the osseous spiral lamina forms the spiral limbus. The vestibular membrane is a thin sheet of tissue extending obliquely from the spiral limbus to the outer cochlear wall. It is easy to identify the cochlear chambers if you remember that the vestibular membrane (the thinnest wall of the cochlear duct) separates the scala vestibuli from the scala media. The stria vascularis is a highly vascularized, pigmented cell layer lining the outer cochlear wall between the points of attachments of the basilar and vestibular membranes. The stria vascularis is believed to be important in maintaining the unique ionic content of the fluid endolymph. The receptor surface of the auditory system, the organ of Corti, is located upon the basilar membrane within the scala media.

The organ of Corti consists of supporting and sensory receptor cells. A prominent feature of the organ of Corti is the space called the tunnel of Corti, which separates two groups of hair receptor cells. The hair receptor cells are arranged in two groups, a single row of inner hair cells near the osseous spiral lamina and a band of outer hair cells organized in three rows. Extending peripherally from the spiral limbus, over the organ of Corti, is the tectorial membrane. This membrane has a gelatinous surface facing the receptor hair cells. It is believed that the hairs of the receptors are embedded within this surface. Although you cannot clearly visualize the receptor cells, you should be aware of their general structure. (Note, Figure 14-11, p. 354). The receptor cells are modified epithelial cells that contain synaptic vesicles and that generate receptor potentials to acoustic stimuli. The receptor cells are oblong (outer hair cells) or globular (inner hair cells) in shape and at their apical end, bear cilia or hairs. The hairs line-up to form the shape of a W or U. These hairs are embedded in a cuticular layer at the upper end of the hair receptor cell. In humans, the hair cells are arranged in three rows of outer hair cells and one row of inner hair cells. The terminals of the peripheral processes of the first-order afferents end near the base and lower third of the receptor cell. Efferent terminals of brainstem neurons are also found synapsing upon the outer hair cells. Efferents do not appear to synapse directly upon inner hair cells, but end on the afferent fibers innervating the inner hair cells. Both types of efferent terminals are part of neural feedback circuits that permit brainstem structures to control the inflow of auditory information. These efferents are collectively called the olivocochlear bundle. Within a canal in the bony modiolus of the cochlea, the cell bodies of the auditory 1° afferents form a spiral-shaped ganglion called the spiral ganglion. These neurons can be seen in the base of the osseous spiral lamina.

## The Vestibular Receptor Organ

---

The vestibular system is a proprioceptive system involved in the detection of head position and movement with respect to gravity. It functions to help maintain muscle tone and posture of the body, neck, head and eyes. The vestibular receptor cells are distributed in five discrete patches; i.e., in each crista of each semicircular duct and in the macula of the saccule and the macula of the utricle.

## Gustatory Receptor Organ

---

The gustatory system is an exteroceptive system involved in the perception of chemicals (flavors) in solids and liquids that are ingested into the oral cavity. The receptor organ includes the tongue, palate, pharynx, epiglottis & esophagus. The receptor cells, taste cells, are organized into small groups, the taste buds, and are innervated by branches of three different cranial nerves. The chorda tympani branch of the facial nerve innervates the taste buds in the anterior two-thirds of the tongue. The greater superficial petrosal branch of the facial nerve innervates taste buds in the palate. The lingual branch of the glossopharyngeal nerve innervates taste buds of the posterior third of the tongue and the pharynx. The superior laryngeal branch of the vagus nerve innervates taste buds in the epiglottis and esophagus.

## Review Of The Peripheral Receptor Organs

---

### The Auditory Ear

#### A. The Outer Ear

The outer ear is divided into the pinna or auricle and the external auditory meatus or canal (Nolte, Fig. 14-1, p.343). The pinna consists of cartilage that is covered by skin continuous with that covering the head. The external auditory canal consists of a lateral cartilaginous portion that is continuous with the

auricular cartilage and a medial bony portion that appears as a canal in the temporal bone. The external auditory canal is closed off at its medial end by the tympanic membrane or ear drum. The tympanic membrane is attached at its edges to the cartilage lining the medial extent of the bony external auditory canal. It is an oval, semitransparent membrane consisting of two layers of collagenous fibers and fibroblasts.

## B. The Middle Ear

The middle ear or tympanic cavity is an air-filled space within the petrous portion of the temporal bone. It is closed off from the external auditory canal by the tympanic membrane and from the fluid-filled inner ear by one of the middle ear bones in the oval window and by a membrane over a second opening the round window. The middle ear cavity contains the middle ear ossicles, the tendons of the middle ear muscles, the chorda tympani branch of the facial nerve and the Eustachian tube. This tube is utilized to equalize air pressure in the middle ear cavity with the outside air pressure. The middle ear ossicles form a chain of three small bones that conduct sound energy from the tympanic membrane to the inner ear. The malleus is attached to the tympanic membrane, the stapes to the oval window, and the incus is interposed between them. The bones and their various components are illustrated in Nolte (Fig. 14-1, p. 343). The stapes, a stirrup-shaped bone, is the smallest bone in the body. It is the most medial of the ossicles and its footplate fits into and is attached to the cartilaginous wall of the oval window by an annular ligament. The middle ear muscles are named the tensor tympani and the tensor stapedius. The tendon of the tensor tympani is attached to the malleus. The tensor tympani is innervated by a branch of the trigeminal (cranial V) nerve. Contraction of this muscle inhibits the movement of the malleus and thus reduces sound transmission to the inner ear. The tendon of the tensor stapedius muscle attaches to the stapes. A branch of the facial (cranial VII) nerve provides motor innervation. Contraction of the stapedius muscle restricts the movement of the stapes, which results in an attenuation of sound energy transmission to the inner ear. The middle ear muscles provide a motor feedback system that controls the flow of auditory information to the central nervous system. **SOUND CONDUCTION IN THE MIDDLE EAR:** When vibrating air molecules strike the tympanic membrane, they displace the membrane causing it to move in and out of the middle ear cavity. The movement of the membrane results in the movement of the malleus to which it is attached. The movement of the malleus, in turn, results in the movement of the incus and stapes, with the net result that the footplate of the stapes is driven in and out of the inner ear at the oval window.

## C. The Inner Ear

The oval window provides an opening from the middle ear cavity into the vestibule of the inner ear. The vestibule is a bony, fluid-filled cavity located medial to the tympanic cavity. The bony cochlea is located anteromedial to the vestibule and is continuous with it. The cochlea is a narrow fluid-filled canal that coils like a snail-shell into a spiral of two and one-half turns in human around an axis formed by a conical pillar of spongy bone called the modiolus. That portion of the cochlea continuous with the vestibule is called the basal turn, while that portion forming the tip of the coil is called the apex. The gross structure of the inner ear is best pictured with the cochlea uncoiled and viewed longitudinally. The canal of the bony cochlea is divided by the cochlear duct into upper and lower chambers, the scala vestibuli and the scala tympani. The cochlear duct does not extend the entire length of the cochlear canal and leaves a small opening, the helicotrema at the apex of the cochlea. The fluid in the scalae vestibuli & tympani is free to flow between the scalae via the helicotrema. The scala vestibuli extends from the oval window & vestibule to the helicotrema. The scala tympani extends from helicotrema to the round window. Recall that the round window is covered by a thin elastic membrane, the round



window membrane. The *scalae vestibuli* and *tympani* contain the fluid *perilymph*, which is in communication with the *perilymph* in the vestibular portion of the inner ear. The *cochlear duct* is a membranous tube that ends blindly at the *helicotrema* and at the base of the cochlea. The *cochlear duct* contains the fluid *endolymph*, which communicates with the *endolymphatic spaces* of the membranous chambers of the vestibular organ via the *ductus reuniens*.

#### D. First Order Afferents

Within a canal in the bony *modiolus* of the cochlea, the bipolar cell bodies of the auditory 1° afferents form a spiral-shaped ganglion called the *spiral ganglion*. The peripheral processes of these cells enter the organ of Corti to innervate the receptor cells; the central processes collect within the core of the *modiolus* to form the auditory nerve in the VIII cranial nerve. Within the internal auditory meatus, the auditory nerve joins the vestibular nerve to form the VIII cranial nerve. This nerve passes into the cranium of the skull through the internal auditory meatus. The central processes of the first order auditory afferents enter the brain stem laterally at the cerebellopontine angle, bifurcate and terminate within the dorsal and ventral cochlear nuclei.

### Vestibular Receptor Organ

#### A. The Labyrinth

**The Bony Labyrinth:** The vestibular end organ is located within the temporal bone near the cochlea – with which it is continuous. The vestibular portion of the bony labyrinth consists of the vestibule and semicircular canals that arise from the vestibule. The vestibule is a fluid-filled cavity located medial to the middle ear cavity. It is partitioned from the air-filled middle ear cavity by the stapes footplate at the oval window and by a membrane at the round window. Three semicircular canals are continuous with the vestibule and contain the fluid *perilymph*.

**The Membranous Labyrinth:** Within the vestibule are suspended two sac-like structures, the *utricle* and *sacculus*. The *sacculus* is attached the medial wall of the vestibule while the *utricle* is suspended above it in the vestibule. A thin *utriculo saccule duct* connects the *utricle* to the *sacculus* - while the *ductus reuniens* connects the *sacculus* to the *cochlear duct*. Within each of the semicircular canals is suspended a thin tube-like *semicircular duct* which is continuous at both ends with the *utricle* (Nolte, Fig. 14-24A, p. 365). Consequently, the fluid *endolymph*, which is produced by the *stria vascularis* of the *cochlear duct*, flows from the *cochlear duct*, to the *sacculus* and *utricle* and thence to the *semicircular ducts*.

#### B. The Maculae And Cristae

A thickening of the *utricle* floor forms the *macula* of the *utricle* while a thickening of the *sacculus* medial wall forms the *macula* of the *sacculus*. The surface of each *maculae* is formed by vestibular receptor (hair) cells and supporting cells and is covered by a gelatinous structure called the *otolith membrane*. In turn, the surface of the *otolith membrane* contains crystals of calcium carbonate called *otoconia* (Nolte, Fig. 14-27, p. 367). The receptor cell hairs (rows of *stereocilia* and a single *kinocilium*) are embedded in the *otolith membrane*.

Each *semicircular duct* expands at one end to form the *ampulla*. The *ampulla* contains a transverse ridge of tissue covered by vestibular receptor (hair) cells called the *crista* (Nolte, Fig. 14-24B, p. 365). The *crista* is, in turn, covered by a gelatinous, dome-shaped structure, the *cupula*, that extends to the roof of the *ampulla*. The cilia of the *crista* receptor cells are embedded in the *cupula*.

### C. Stimulation Of The Vestibular Receptor Cells

Gravitational forces and linear accelerating forces on the otoconia are believed to displace the otolith membrane and bend the cilia of the macular receptor cells. The relative motion of the endolymph during rotatory acceleration is believed to distort the cupula, which bends the cilia of the crista receptor cells. The bending of the vestibular receptor cell cilia opens stress-gated (mechanical) channels in the receptor membrane, which initiates the sensory transduction process that results in the release of neurotransmitters on vestibular 1° afferent terminals.

### D. First Order Afferents

The bipolar cell bodies of the vestibular 1° afferents, which are grouped in the peripheral branches of the vestibular nerve, are collectively called Scarpa's ganglion. The peripheral processes of these cells enter a macula or crista to innervate the receptor cells; and the central processes collect within the internal auditory meatus to form the vestibular nerve in the VIII cranial nerve. Within the internal auditory meatus, the vestibular nerve joins the auditory nerve to form the VIII cranial nerve. The central processes of the 1° vestibular afferents enter the brain stem laterally at the cerebellopontine angle and terminate within the superior, medial, lateral or inferior vestibular nucleus. A small number of 1° vestibular afferents also terminate directly in the cerebellum.

## Gustatory Receptor Organ

### A. The Tongue

The epithelium of the tongue is organized into a series of small ridges and peaks called papilla. You can see these on the surface of your tongue as bright red dots. The taste buds are distributed within the fungiform papillae (which are located in the front and lateral parts of the tongue), the foliate papillae (which are located on the lateral part of the back of the tongue), and the circumvallate papillae (which are located on the back of the tongue).

### B. The Taste Buds

The taste receptors are modified epithelial cells that recycle along with the oral epithelium. Approximately 50 to 100 taste cells are clustered into a taste bud (like the petals of a chrysanthemum bud) along with supporting & basal cells. The basal cells differentiate into supporting cells and some of these, in turn, differentiate into receptor cells. The taste cell is elongated in form, produces small villi at its apical end and contains synaptic vesicles at its basal end. Within the taste bud, the receptor cells are aligned with their apical ends facing a small opening, the taste pore, and their basal ends resting on the basal cells (Nolte, Fig. 13-2, p. 325). The taste bud is embedded in the epithelium near the surface of the fungiform papillae and in the crevice between foliate papillae and between circumvallate papillae.

## Olfactory Receptor Organ

The olfactory receptor organ is the olfactory epithelium of the nose. It is a small patch (approximately 2.5cm<sup>2</sup>) of tissue that lines the roof and adjacent walls deep in the nasal cavity. It consists of the olfactory receptor cells, supporting cells and basal cells (Nolte, Fig. 13-10, p.333). The olfactory receptor cells are bipolar neurons and serve as both the receptor cell and 1° afferent of the olfactory system. The supporting cells of the olfactory epithelium are believed to secrete mucus along with Bowman's glands in the lamina propria. The basal cells are considered to give rise to olfactory receptor cells, which have a life span of approximately 60 days. The peripheral process of the olfactory 1° afferent forms the receptive element: It arises from one pole of the neuron cell body terminates in a

knob like structure called the olfactory vesicle or knob. Short processes, the olfactory cilia, extend from the olfactory knob into the overlying mucus film. Air borne chemicals are dissolved in the mucus film and delivered to receptor sites on the olfactory cilia. It is believed that the cilia contain ligand gated channels that serve as receptive sites for specific chemical molecules. The activation of the receptive sites produces electrochemical changes in the olfactory receptor cell that result in the production of generation potentials in the olfactory cell. The opposite end of the bipolar olfactory 1° neuron gives rise to a thin process, the olfactory axon, which is unmyelinated and grouped into small bundles of 10 100 axons called the olfactory fila. The olfactory fila pass through the cribriform plate of the ethmoid bone to end in the olfactory bulb within the cranial cavity. The generation potential in the receptor cell results in the initiation of action potentials in the unmyelinated olfactory axons that are conducted to the olfactory bulb.

## **Review Of The Sensory Pathways**

### **A. Auditory System**

The 1° afferents of the auditory nerve terminate in the cochlear nuclear complex. These 2° afferents give rise to axons that either cross the midline in the trapezoid body or remain uncrossed. Many of the 2° afferents (both crossed and uncrossed) terminate in the superior olivary complex. The axons of the 3° afferents may join those of 2° afferents that did not end in the superior olivary complex to form the lateral lemniscus. Some of the fibers in the lateral lemniscus terminate within the nuclei of the lateral lemniscus. The axons of these 4° afferents also join the lateral lemniscus. All axons in the lateral lemniscus terminate in the inferior colliculus. The cells of the inferior colliculus (which we will call 5° afferents for simplicity) give rise to axons that ascend in the brachium of the inferior colliculus to the medial geniculate nucleus of the thalamus. The axons of the medial geniculate nucleus travel in the sublenticular division of the internal capsule to terminate in the superior bank of the superior temporal gyrus (significantly in the Transverse Temporal Gyrus (of Heschl) (Nolte, Fig. 14-18, p.359)

### **B. Vestibular System**

The 1° vestibular afferents enter the brain stem, bifurcate and ascend and descend the brain stem to terminate within the four nuclei of the vestibular nuclear complex. This complex consists of the inferior, medial, lateral & superior vestibular nuclei. Their names describe their relative locations in the brain stem (Nolte, Fig. 14-29, p. 369). The major outflow from the vestibular nuclei is not to the thalamus: That is, most of the axons of the vestibular nuclei travel to (1) visceromotor nuclei via the reticular formation, (2) the extraocular motor nuclei via the medial longitudinal fasciculus, (3) the cerebellum via the inferior cerebellar peduncle and (4) the spinal cord via the medial longitudinal fasciculus and lateral vestibulospinal tract. The 2° afferents ascending to the thalamus appear to travel either with the lateral lemniscus or near the medial longitudinal fasciculus. The 2° afferents end in the ventral posterior inferior nucleus of the thalamus (Figure 6-1). The VPI axons travel in the posterior limb of the internal capsule to terminate in the superior parietal lobule and in rostral areas of the superior temporal gyrus.

### **C. Gustatory System**

The central processes of the 1° gustatory afferents enter the solitary tract and ascend (vagus & glossopharyngeal afferents) or descend (facial afferents) the brain stem to terminate in the rostral or gustatory part of the solitary nucleus (Nolte, Fig. 13-4, p. 327). Axons of the solitary nucleus (the 2° afferents) ascend the brain stem uncrossed in the central tegmental tract and terminate in the most medial part of the ventral posteromedial (VPM) nucleus of the thalamus. The axons

of these 3° afferents travel in the posterior limb of the internal capsule to terminate in the rostral parietal operculum (the area of the postcentral gyrus lining the lateral fissure) and in the insula. Affective reactions to taste stimuli (e.g., pleasant or unpleasant flavors) appear to involve a different pathway that includes the solitary nucleus, a pontine taste area, and the limbic system & hypothalamus (Nolte, Fig. 13-6, p. 329).

#### D. Olfactory System

The olfactory pathway has classically been described to originate in the olfactory mucosa and to terminate in the piriform cortex (Nolte, Figure 13-17, pp. 337). The olfactory receptor cells, which number more than 100 million, serve as both the receptor cell and the 1° afferent neuron of this sensory system. The axon of the receptor cell passes through the cribriform plate of the ethmoid bone to end in the olfactory bulb, which is part of the telencephalon (Nolte, Fig. 13-16, p. 336). Within the bulb they terminate primarily on the dendrites of mitral cells in a tangle of dendrites and axon terminal processes called the glomerulus. There is a large convergence of olfactory nerve fibers on a given mitral cell (approximately 1,000 to 1). The axons of the mitral cells form the olfactory tract. Also found in the olfactory bulb are interneurons called periglomerular cells. Efferent neurons to the olfactory bulb form the basis for a neural feedback system. These efferents arise from the anterior olfactory nucleus, a loose collection of cells within the olfactory tract and from the region of the anterior perforated substance.

The olfactory tract branches at the olfactory trigone into the medial and lateral olfactory stria. The lateral olfactory stria is larger in humans and carries the 2° afferents to piriform and periamygdaloid cortex, and amygdala. The piriform cortex, sometimes also called the lateral olfactory gyrus, and the periamygdaloid area are considered to constitute the primary cortical olfactory receiving area. The entorhinal cortex is considered to be a secondary olfactory cortical area. Other connections considered as part of the limbic system will be covered in the Exercise on the Limbic System & Hypothalamus. The piriform cortex sends axons to the dorsomedial (DM) nucleus of the thalamus, which, in turn, sends its axons to the orbital gyrus of the frontal cortex.

On your hemisected brain, try to identify the following:

- Insula (anterior part - gustatory cortex)
  - Superior bank of the superior temporal lobe
  - Transverse Temporal Gyri of Heschl
  - Posterior insula
  - Inferior parietal lobule
  - Olfactory bulb
  - Olfactory tract
  - Orbital gyrus
  - Gyrus rectus
  - Medial and lateral olfactory stria
  - Uncus
  - Periamygdaloid cortex
  - Entorhinal cortex
  - Parietal opercular cortex (gustatory area)

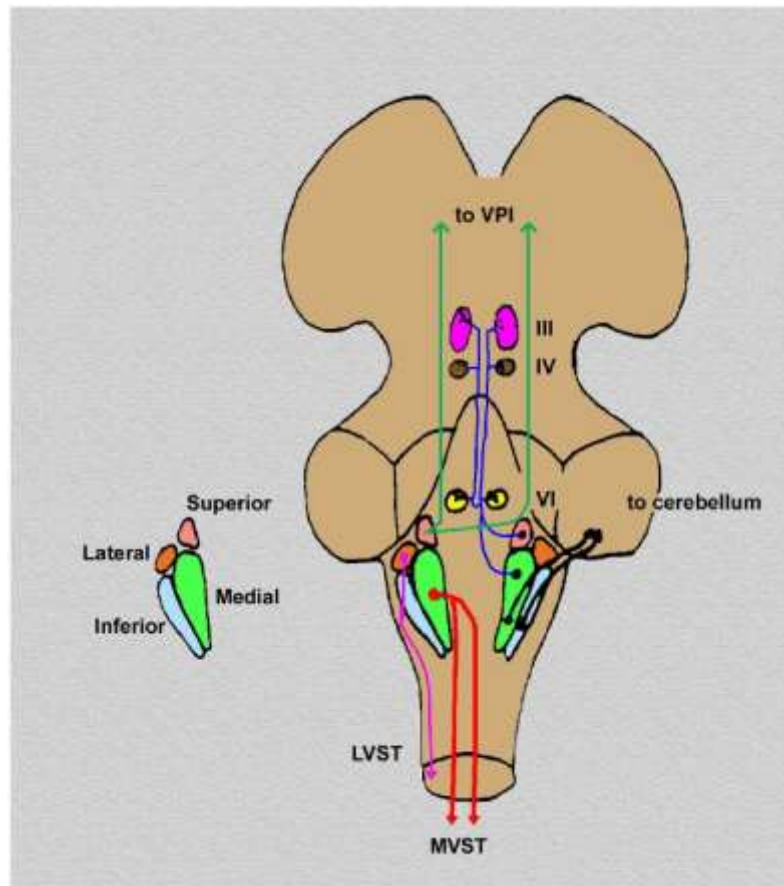


Figure 6-1. This figure illustrates the tracts arising from the vestibular nuclei, which are outlined to the left. The lateral vestibulospinal tract (LVT) arises from the lateral vestibular nucleus and descends to the spinal cord. The medial vestibulospinal tract (MVST) arises from the medial vestibular nucleus, descends the brain stem in the medial longitudinal fasciculus to form the MVST in the anterior funiculus of the spinal cord. The vestibulocerebellar fibers from the vestibular nuclei travel in the inferior cerebellar peduncle (drawn in the right half of the illustration) to the cerebellum. Axons from the superior and medial vestibular nuclei (predominantly) ascend in the medial longitudinal fasciculus to terminate in cranial nerve nuclei (III, IV & V) and are involved with controlling the extraocular muscles. The 2° vestibular afferents are shown traveling to the thalamus.



# Laboratory Exercise #7:

## Visual System and Oculomotor Control

Lecturer: Valentin Dragoi, Ph.D.

March 13, 2012 1:00 PM

### Required Reading

---

- Nolte, Chapter 12, Cranial Nerves, pp. 295-302
- Nolte, Chapter 17, Visual System
- Nolte, Chapter 21, Control of Eye Movements

### Introduction

---

In this exercise, you will study the major structures of the visual sensory and ocular motor systems. The visual sensory pathway from the eye to the occipital cortex is involved in the processing of complex visual imagery. Neurons within this system respond selectively to specific patterns of light, such as contours, and to light of different wavelengths, i.e., color. This pathway is organized in a topographic manner, a feature that contributes to our ability to recognize objects and accurately localize objects in visual space. Knowledge of this topographic organization is important clinically since visual field deficits serve as useful indicators of the site of damage. You will also examine the ocular motor pathways involved with controlling the eye blink reflex, eye movements, pupil size and near vision responses.

At the conclusion of today's laboratory you should be able to:

1. Identify the principal structures of the eye.
  2. Identify the major components of the visual sensory pathway.
  3. Identify the neural structures controlling visual/ocular motor responses.
- **Part A**  
**Examination Of Wet Human Brain Material And**
    1. Your human specimens
    2. Demonstration material presented by teaching assistants
  - **Part B**  
**Complete Exercise Mode Of Laboratory #7 Of Neurolab**
    1. Each student should go through the NeuroLab computer program review mode prior to the laboratory.
  - **Part C**  
**An Exercise At The End Of The Laboratory (~3:30 P.M.) To Assess Your Learning Progress**
  - **Part D**  
**Post-Laboratory Review Using Clinical Cases**



## Materials

---

- Brain specimen bucket containing
  - Whole Brain
  - Hemisected brain specimen
- Aluminum pan
- Squeeze bottles with water or bleach
- Cleanup towels for any dripping or spillage

### *You need to bring:*

- Gloves
- Dissection kit
- You may want to bring an plastic apron to protect your clothes.

## Examination Of Wet Human Brain Material: Visual Systems

---

### Brain Specimens

Locate the optic nerve on the inferior surface of the whole brain (DeArmond, Fig. 3, p. 6 & Nolte, Fig. 3-16, p. 65). Each optic nerve contains uncrossed, myelinated axons of the retinal ganglion cells. Fibers in the optic nerve are thus axons of third-order ( $3^{\circ}$ ) afferents in the visual pathway. What are the second-order afferents called? \_\_\_\_ (7-1). Identify the optic chiasm on the inferior surface of the brain. Fibers arising from the nasal half of each retina (and representing the temporal visual hemifields) cross in the optic chiasm to the opposite optic tract. Notice the proximity of optic chiasm to the infundibulum (the pituitary stalk). Recall that fibers arising from the temporal areas of the retina (and representing the nasal visual hemifields) do not cross.

Locate the oculomotor nerves emerging from the midbrain within the interpeduncular fossa. Notice that the oculomotor nerve is positioned between the posterior cerebral artery and superior cerebellar artery and is vulnerable to vascular abnormalities. The abducens nerves emerge more caudally at the pontomedullary junction. Recall that the trochlear nerves emerge from the posterior surface of the midbrain and can only be visualized if the cerebellum is removed. These three cranial nerves (the abducens, trochlear & oculomotor) provide the motor innervation to the extraocular muscles.

On the hemisected brain specimen, see if you can follow the optic tract from the chiasm posteriorly to the lateral geniculate body of the thalamus (DeArmond, Fig. 6, p. 12). The optic chiasm is located at approximately the same rostral-caudal level as what fiber tract connecting the two sides of the brain? \_\_\_\_ (7-2). What major artery is located just lateral to the chiasm? \_\_\_\_ (7-3). What are its five major branches? \_\_\_\_, \_\_\_\_, \_\_\_\_, \_\_\_\_, and \_\_\_\_ (7-4).

The axons of the lateral geniculate nucleus pass in the retrolenticular and sublenticular segments of the internal capsule as the optic radiations (DeArmond, Fig. 10-13, pp. 20-26; Nolte, Fig. 17-27 and 17-28, p. 441-442). Optic radiations (called the geniculocalcarine tract in DeArmond) terminate in an orderly manner in the calcarine cortex of the occipital lobe. Using the hemisected brain review the boundaries of the occipital lobe (DeArmond, Fig. 4, p. 8). Identify the parieto- occipital sulcus, the preoccipital notch, and the calcarine sulcus. The primary visual receiving area, i.e., the calcarine or striate cortex, is



located medially in the walls of the calcarine sulcus and in adjacent portions of the cuneate and lingual gyri. The extrastriate cortex extends from the medial surface of the occipital lobe to occupy most of the lateral surface of this lobe (Nolte, Fig. 22-10, p. 550). Parietal and temporal cortical areas adjacent to the extrastriate cortex form visual association areas important for perceiving the spatial location and movement of objects (parietal association area) and for perceiving the shape & color of objects and recognizing & naming objects (temporal association area). The parietotemporal eye field includes portions of the parietal visual association area and caudal parts of the superior temporal and middle temporal gyri (Brodmann's areas 39 & 37). The parietotemporal eye fields are important for the visual guidance of smooth pursuit (tracking) eye movements. On the lateral surface of the hemisected brain locate the frontal eye field. It includes the caudal part of the middle frontal gyrus and adjacent areas of the inferior frontal gyrus (Nolte, Fig. 22-10, p. 550). The frontal eye fields are important for initiating voluntary (guided) saccadic eye movements. Which fibers are decussating within the chiasm? \_\_\_\_ (7-5). What fibers are contained within the optic tract? \_\_\_\_ (7-6) In which thalamic nucleus do the optic tract fibers terminate? \_\_\_\_ (7-7).

The superior colliculus forms the rostral part of the midbrain tectum (i.e., the roof of the cerebral aqueduct). The superior colliculus plays a role in generating reflex eye movements to auditory and visual stimuli and also works with the basal ganglia to affect voluntary eye movements (Nolte, Fig. 21-18, p. 536). The superior colliculus receives input from the eye (via optic tract fibers in the brachium of the superior colliculus), inferior colliculus, cortical areas and from the basal ganglia. It sends some of its axons to two nuclei in the periaqueductal gray that are called the "vertical gaze centers". These two nuclei, the rostral interstitial nucleus of the medial longitudinal fasciculus and interstitial nucleus of Cajal, send their axons to the trochlear and oculomotor nuclei to control vertical eye movements.

The superior colliculus is important for controlling reflex saccades - e.g., eye movements to a sudden noise or light flash and voluntary vertical saccades. It provides controlling inputs to the midbrain "vertical gaze centers" and the pons "horizontal gaze centers". The superior collicular axons descend as tectopontine fibers within the tectospinal tract. The tectopontine fibers leave the tectospinal tract in the pons to terminate in the pons horizontal gaze center.

The supraoculomotor area is located immediately posterior to the oculomotor nuclear complex - in the periaqueductal gray. The supraoculomotor area contains neurons that provide control signals for the accommodation or near response, (i.e., adjustments in eye position - convergence, pupil size and lens shape to view near objects). These supraoculomotor area neurons send their axons bilaterally to motor neurons (oculomotor and abducens) controlling the medial and lateral rectus muscles and to Edinger-Westphal neurons controlling the lens shape and position and the pupil size (Nolte, Fig. 17-39, p. 453).

In the reticular formation near the midline and anterior to the MLF are paramedian pontine reticular formation (PPRF) neurons that constitute the "horizontal gaze center". The "horizontal gaze center" neurons synapse with tectopontine fibers from the superior colliculus and corticofugal fibers from frontal eye field neurons (Nolte, Figure 21-13, pp. 532). In turn, these PPRF "horizontal gaze center" neurons send their axons to the ipsilateral abducens nucleus. The axons of abducens nucleus interneurons decussate and ascend in the medial longitudinal fasciculus to the contralateral oculomotor nucleus. This pathway, from the "horizontal gaze center" to the abducens and oculomotor nuclei, is important in the control of saccades (e.g., conjugate horizontal gaze).

Corticofugal fibers terminating in dorsolateral pontine nuclei form part of the circuit controlling smooth pursuit, i.e., eye movements for tracking moving objects (Nolte, Figure 21-16, p. 535).

The axons of the pontine nuclei decussate and travel in the middle cerebellar peduncle to the part of the cerebellum associated with the vestibular system. In turn, the cerebellum provides input back to the vestibular nuclei. The vestibular nuclei (superior and medial) are part of the smooth pursuit pathway controlling the movement and trajectory of the eye and send axons via the medial longitudinal fasciculus to the cranial motor nuclei controlling the extraocular muscles.

The spinal trigeminal tract and nucleus are located immediately anterior to the vestibular nuclei. They contain the 1° and 2° afferents, respectively, conveying information about somatosensory stimulation of the cornea (as well as other face areas). The facial motor nucleus is located anteriorly in the pons tegmentum, lateral to the central tegmental tract and posterior to the superior olivary complex. Axons of spinal trigeminal nucleus neurons representing the cornea terminate bilaterally on facial motor neurons innervating the orbicularis oculi of the eyelid. Consequently, somatosensory stimulation of the cornea can elicit a rapid eye blink bilaterally via this eye blink reflex pathway (Nolte, Figure 12-26, p. 316).

Oculomotor nuclear neurons innervate which extraocular muscles? \_\_\_\_ (7-8). The Edinger-Westphal nucleus provides preganglionic parasympathetic fibers to which autonomic ganglion? \_\_\_\_ (7-9). The ciliary ganglion, in turn, provides postganglionic parasympathetic fibers to which eye muscles? \_\_\_\_ and \_\_\_\_ (7-10). Which section of the left oculomotor nerve results in paralysis of the left superior levator palpebrae (left ptosis or eyelid droop)? \_\_\_\_ (7-11).

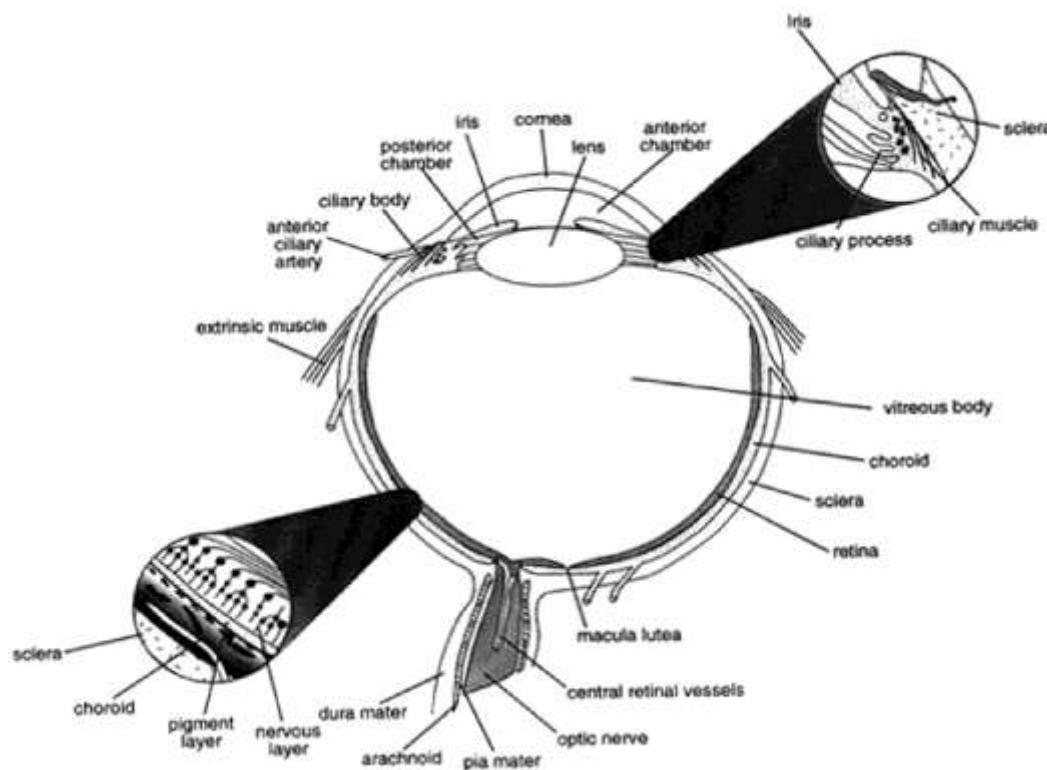


FIGURE 7-1: Horizontal section through the eye.

## Primary Visual Pathway

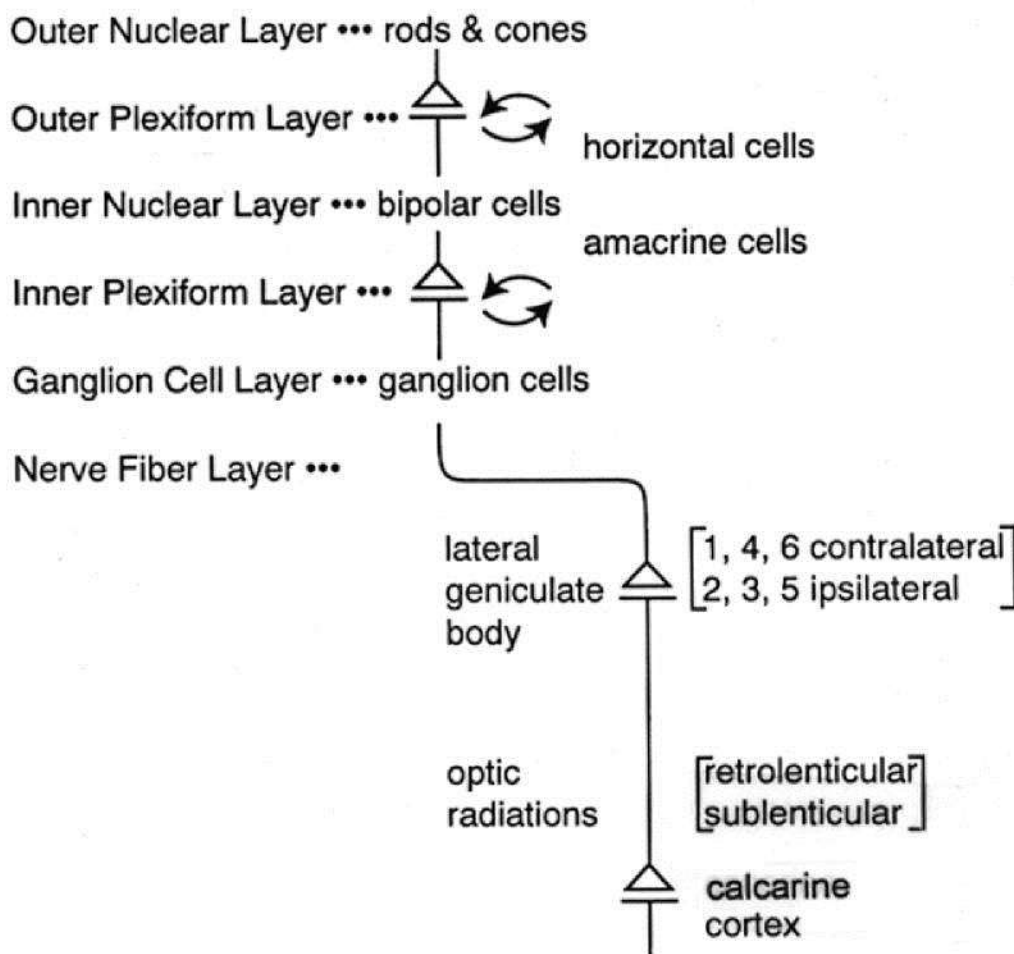


FIGURE 7-2. The Visual Sensory Pathway

## Review Of The Visual System

### The Visual Receptor Organ

#### A. The Gross Anatomy Of The Eye

The eye is spherical in shape and located within the bony orbit surrounded by connective tissue and orbital fat. The wall of the eye is composed of three concentric coats or layers, which enclose the transparent media of the eye (Nolte, Figure 17-2, p. 417).

**THE OUTER LAYER:** The outermost coat or fibrous coat consists of the sclera and the cornea. The sclera is a fine fibrous, elastic tissue, white in color, which forms the posterior seventy percent of the outer wall. The sclera helps maintain the shape of the globe, serves to protect the structures within, and serves as a place of attachment for the extraocular muscles. At the posterior pole of the globe, the sclera is perforated at the optic disc to permit the passage of nerve bundles and blood vessels.

The cornea, the avascular and transparent portion of the outer coat, forms the anterior thirty percent of the outermost layer. The cornea is the first refractive medium interposed between an external light source and the internally located photoreceptors and is of critical importance in the image forming process. A branch of the trigeminal nerve provides afferent (somatosensory) innervation to the cornea. The cornea is extremely sensitive to tactile and chemical stimuli. It is also sensitive to intraocular pressure and turns opaque with a rise in pressure, such as in the case of glaucoma.

**THE MIDDLE LAYER:** The middle or vascular coat consists of the choroid, the ciliary body, the ciliary muscles, and the iris (Nolte, Figure 17-2 & 17-3, p. 413, 418). The choroid is the largest segment of the vascular layer and covers most of the inner surface of the sclera. It is a thin, soft and richly vascularized membrane that is darkly pigmented. Through its rich vascular supply it provides nutrients to the inner ocular tissue. Its pigmentation allows it to serve as a dark, light absorbing lining.

Anteriorly the choroid merges with the ciliary body, a thickening of the vascular layer surrounding the outer perimeter of the lens. The ciliary muscles are located in the base of the ciliary body. Attached to the ciliary body are the suspensory ligaments, which connect the ciliary body to the lens. The ciliary body, through the action of the ciliary muscles and suspensory ligaments, controls the position and shape of the lens. The iris, the most anterior segment of the vascular layer, extends over the anterior surface of the lens.

The iris is a thin, pigmented, annular-shaped structure with an opening in its center, the pupil. The iris contains two sets of smooth muscles (the sphincter and dilator) that control the size of the pupil aperture. The iris functions as a diaphragm to control the amount of light entering the eye and to control the depth of field.

**THE INNER LAYER:** The third or innermost coat of the eye is the nervous tunic or retina. The retina covers the choroid and extends anteriorly to just behind the ciliary body, where it ends abruptly at the ora serrata. The outermost layer of the retina, which lines the choroid, consists of a layer of pigment epithelium.

**THE LENS:** The lens is a transparent biconvex structure located behind the iris. It has a spherical inner nucleus, an outer laminar cortex and a highly elastic lens capsule. It is suspended in the eye by the suspensory ligaments of the ciliary body, which are attached to the lens capsule. It is part of the refractive system of the eye and functions with the ciliary body during accommodation, i.e., near vision.

**THE CHAMBERS OF THE EYE:** There are three chambers in the eye. The anterior chamber is located between the cornea and the anterior surfaces of the iris and lens. It contains the fluid aqueous humor. The posterior chamber is located behind the iris and extends around the lens posterior surface. The posterior chamber also contains the fluid aqueous humor. This fluid is a major nutritive source to the avascular tissue of the eye. The aqueous is formed by the epithelia of the ciliary body (Nolte, Figure 17-3, p. 418). Abnormal accumulation of this fluid results in the condition called glaucoma. The vitreous chamber occupies eighty percent of the eye volume and is filled with the vitreous humor. It is located behind the lens and ciliary body. The vitreous humor is a permanent transparent gelatinous mass that contains soluble proteins, collagen, and hyaluric acid.

## B. Microscopic Anatomy Of The Eye

**THE PHOTORECEPTORS:** The photoreceptors are specialized neurons that function as receptor cells responsive to light stimuli (Nolte, Figure 17-4, p. 420). The two types of receptors, the rods and cones, share certain features. The outer segment of the receptor is laminated, located in close association with the retinal pigment epithelium, and contains light sensitive photopigments. Breakdown of these photopigments represents the initial stage of the receptor transducer function. The ciliary stalk connects the receptor cell outer segment to its inner segment. The inner segment, which contains many mitochondria, is continuous with the cell body of the receptor cell. The cell bodies of photoreceptors are located in the outer nuclear layer of the retina and their axons project into and terminate in the outer plexiform layer.

**THE ROD RECEPTORS:** The rods are flask or rod shaped and contain the photopigment rhodopsin, which breaks down on exposure to white light. The disks forming the outer segment lamina undergo constant renewal at the most apical end of the rod. The normal turnover may be impaired in retinitis pigmentosa and other retinal diseases. There are approximately 120 million rods in the human eye. The vast majority is located in the peripheral regions of the retina.

**THE CONE RECEPTORS:** There are three types of cones, each containing photopigments that are selectively sensitive to red, blue or green light. The cone outer segment differs from those of rods in that its lamination is formed by the infolding of the cell membrane and does not consist of layers of disks (Nolte, Figure 17-7, p. 422). There are approximately 6 million cones in the human eye. The majority are concentrated in the fovea and macula of the retina (Nolte, Figure 17-8, p. 423), the region where the visual image is normally focused.

**OTHER RETINAL NEURONS:** The rod and cone axon terminals synapse with the dendrites of horizontal cells and bipolar cells in the retina outer plexiform layer (Nolte, Figure 17 4, p. 420). The horizontal cell is a “local--circuit” neuron that is characterized by processes that do not leave their immediate area, i.e., the outer plexiform layer. The processes of the horizontal cell synapse with those of receptor cells and other horizontal cells. The bipolar cell axons travel to and synapse in the retina inner plexiform layer with two other types of retinal neurons, the ganglion cell and the amacrine cell. The ganglion cell dendrites synapse with the axon terminals of bipolar cells and with processes of amacrine cells. The ganglion cell axons pass out the eye at the optic disc and form the optic (first cranial) nerve. The amacrine cell is another “local circuit” cell with processes that remain within the inner plexiform layer. The receptor cells are considered the first-order afferents of the visual pathway with the bipolar cells and ganglion cells constituting the second and third order afferents, respectively.

**RETINAL LAYERS.** The retinal pigment epithelium lies next to the choroid coat and contains black pigment to absorb stray light (Nolte, Figure 17-5, pp. 421). The next layer, the receptor layer, contains the outer segment, ciliary stalk, and the inner segment of the rods and cones. The outer nuclear layer contains the receptor cell bodies. The outer plexiform layer contains the region of synapse between the receptor cells, the bipolar cells and the horizontal cells. The inner nuclear layer contains the cell bodies of the horizontal, bipolar and amacrine neurons. The inner plexiform layer is the region of synapse between the bipolar, amacrine and ganglion cells. The ganglion cell layer contains the cell bodies of the ganglion cells. The optic nerve fiber layer contains the axons of the ganglion cells on their course to the area of their exit, the optic disc. It is important to remember that light must travel through many layers of the retina, i.e., from the optic nerve layer through the outer nuclear layer, before reaching the

photopigments in the outer segment of the receptor cell.

**REGIONAL VARIATIONS:** The fovea is an avascular area that appears as a depression in the retina - as only the receptor cells and their axons are present (Nolte, Fig. 17-11, p. 425). The fovea contains cones exclusively in the human retina and is the point of sharpest visual acuity and most acute color discrimination. The macula surrounds the fovea and along with the fovea represents the retinal area responsible for central vision. The optic disc is situated nasally and is composed of the optic nerve fiber layer and the inner limiting membrane only (Nolte, Figure 17-9, pp. 424). Retinal vessels and optic nerve fibers pass through the retina at this point. As there are no receptor cells in this region, it produces a blind spot in the monocular visual field (Nolte, Figure 17-10, pp. 424).

## Central Visual Pathways

### A. Visual Sensory Pathway

The 1° afferents of the visual system are the rods and cones of the retina (i.e., the photoreceptors) and the 2° afferents are the bipolar cells of the retina. The axons of the retinal ganglion cells (3° afferents) emerge from the eye to form the optic nerve. This “nerve”, which in humans contains approximately 1 million fibers, is actually a fiber tract of the CNS as embryologically the retina derives from the brain. Within the cranial cavity, before entering the brain, the fibers from the nasal regions of the two retinas decussate to form the optic chiasm (Nolte, Figures 17-26, p. 440 & 17-27, p. 441). Beyond the optic chiasm, the fibers from the temporal area of the ipsilateral retina join with the fibers from the nasal area of the contralateral retina to form the optic tract. The fibers of the optic tract enter the brain at the level of the posterior diencephalon and may: 1) terminate in the lateral geniculate nucleus (LGN) of the thalamus or 2) pass on to the midbrain in the brachium of the superior colliculus to terminate in the superior colliculus (tectal area) and in pretectal areas (Nolte, Figure 17-39, p. 453). The human LGN consists of six distinct layers: the cells in layers 1, 4 and 6 synapse with fibers from the contralateral eye (nasal retina) and cells in layers 2,3 and 5 synapse with fibers from the ipsilateral eye (temporal retina). Thus, each cell in the LGN receives information from only one eye (monocular input). The axons of the LGN (4° afferent) travel in the optic radiations of the internal capsule to the primary cortical receiving area for the visual system, the calcarine cortex (also called the striate cortex) of the occipital lobe. The axons of the superior colliculus and pretectal area travel to a number of structures and are believed to play a role in reflex visual responses.

### B. Retinotopic Representation Of The Visual Field

Recall that light falling on the photoreceptors in the retina must first pass through the cornea and lens of the eye. Because of the physical properties of lenses, the resulting image which impinges on the retina is upside down and left right reversed, i.e., it is a virtual image (Nolte, Figure 17-26, p. 440). Thus, light reflected from an object in the upper half of the visual field falls on the lower half of the retina and light from the temporal half of the visual field falls on the nasal half of the retina. Moreover, light from an object seen by both eyes (i.e., in binocular vision) will fall on different sides of the retina in each eye. For example, light from the left part of the visual field will fall on the nasal retina of the left eye and on the temporal retina of the right eye (Nolte, Fig. 17-26 and 17-27, p. 440-441). Be sure you understand these relationships. Corresponding regions of the visual field seen by both eyes (the pink area in Nolte, Figure 17-32, p. 445) are in the binocular visual field.

The result of the partial decussation in the optic chiasm is the representation of homonymous (overlapping) vertical halves of the visual fields of the two eyes at post chiasmic levels (Nolte, Fig. 17-



33D, p. 446). That is, the right halves of the visual fields of both eyes (temporal hemifield of the right eye and the nasal hemifield of the left eye) are represented by the left optic tract fibers, left lateral geniculate body and left visual cortex.

As a consequence, damage to any one of these structures in the left half of the brain results in blindness of the right halves of the visual fields of both eyes, a right (or contralateral) homonymous hemianopia. Homonymous defects involve the right or left fields of the two eyes and result in complete blindness in the affected portion of the binocular field. A small portion of the temporal visual field called the temporal crescent projects onto the periphery of the nasal retina but not onto any corresponding part of the temporal retina in the other eye. The two temporal crescents are thus monocular fields. Each projects contralaterally to form a monocular periphery to the binocular representation of the rest of the visual field (the blue and green areas in Nolte, Fig. 17-32-C, p. 445). The optic tract fibers terminate in selected layers of the lateral geniculate body. Recall that the LGN consists of 6 layers numbered 1 to 6 from the inferior surface. The crossed optic tract fibers terminate in layers 1, 4 and 6 and the uncrossed fibers in layers 2, 3, and 5 (Nolte, Fig. 17-27-C, p. 441). Within the six LGN layers the representations of homotopic parts of the nasal and temporal hemiretinae are in register.

The primary visual cortical receiving area is located in the occipital lobe calcarine cortex which surrounds the calcarine sulcus (Nolte, Figure 17-28, p. 442). The superior lip of the calcarine sulcus is formed by part of the cuneus gyrus and the inferior lip by part of the lingual gyrus. Fibers representing the superior half of the retina travel in the retrolenticular optic radiation, course superiorly and caudally to terminate in the superior lip of the calcarine fissure (Nolte, Figure 17-28-A, pp. 442). Those fibers representing the inferior half of the retina arch caudally in the sublenticular optic radiation about the anterior portion of the temporal horn of the lateral ventricle in Meyer's loop and terminate in the inferior lip of the calcarine fissure (Nolte, Figure 17-28, pp. 442). Consequently, the superior lip of the calcarine fissure contains cells representing the inferior visual field and the inferior lip, the superior visual field. (Nolte, Figure 17-28, pp. 442) (READ CAREFULLY, especially exam questions!!! Do not confuse retinal areas with visual fields. Note that a given retinal area receives an image that is inverted and right left reversed with respect to the visual field. For example, the inferior nasal retinal area has projected on it the superior temporal quadrant of the visual field.) The caudal third of the calcarine cortex, starting from the occipital pole, contains cells representing the macular area of the retina and the center of the visual field (Nolte, Figure 17-27, pp. 441). The cells in more rostral areas of the calcarine cortex represent the paracentral and peripheral retinal areas. The monocular temporal crescent is represented at the extreme rostral aspect of the calcarine cortex.

### C. Ocular Motor Pathways

The perception of a well-focused visual image requires the interaction of various visual motor responses. For example, the eyes move conjugately (together and in the same direction) to focus the images of the visual target on the foveas of the two eyes. The size of the pupil is also adjusted to decrease or increase the amount of light entering the eye (i.e., the pupillary light reflex). In adapting for near vision, the pupil size is altered to adjust the depth of focus (pupillary accommodation reflex), the curvature of the lens is altered (lens accommodation), and the eyes converge (move nasally) to execute a change in fixation point.

### 1. *Infranuclear Control of Eye Movements*

**EXTRAOCULAR MUSCLES:** The individual movements of a single eye are known as ductions (Nolte, Figure 21-2, p. 526 & 21-7, p. 528); For example, infraduction (looking down), abduction (looking laterally or outward), adduction (looking medially or inward toward the nose), and supraduction (looking up). Each eye is moved by six extraocular muscles: the medial and lateral rectus, the superior and inferior rectus, and the inferior and superior oblique muscles. Horizontal movements involve the coordinated actions of the lateral and medial rectus (Nolte, Figure 21-3, pp. 527). For example, the lateral rectus contracts and the medial rectus relaxes to abduct the eye. The opposite actions must occur to adduct the eye. Vertical movements involve the coordinated actions of the superior and inferior rectus muscles (Nolte, Figure 21-7-Left, pp. 528). In a supraduction, the superior rectus contracts and inferior rectus relaxes. Oblique and torsional movements of an individual eye are produced by particular patterns of excitation and inhibition involving all the muscles (Nolte, Figure 21-7-Right, pp., 528).

**CRANIAL MOTOR NUCLEI:** Three cranial nerves innervate the extraocular muscles (Nolte, pp. 295 - 302) of a single eye - as follows:

- a. Abducens (VI): lateral rectus (nerve fibers are ipsilateral to their cells of origin in the abducens nucleus)
- b. Oculomotor (III): the inferior rectus, medial rectus, & inferior oblique (nerve fibers are all ipsilateral to their cells of origin in the oculomotor nucleus) and the superior rectus (nerve fibers are contralateral to their cells of origin in the oculomotor nucleus)
- c. Trochlear(IV): the superior oblique (nerve fibers are contralateral to their cells of origin in the trochlear nucleus)

The three cranial nuclei supplying the muscles of each eye constitute the infranuclear (direct motor) innervation of the extraocular musculature. The responses of the motor neurons supplying the extraocular muscles are controlled by various supranuclear structures located in the brain stem, cerebellum, and cerebral cortex. Supranuclear control of the precise coordinated actions of the extraocular muscles permits conjugate and vergence movements of both eyes.

The medial longitudinal fasciculus (MLF) contains ascending and descending fibers of the abducens nucleus, trochlear nucleus and oculomotor nucleus (Nolte, Figure 12-9, pp. 304) that are involved in coordinating the activity of antagonist muscles (e.g., the medial and lateral rectus muscles) for conjugate lateral and vertical gaze. The MLF also contains vestibular nuclear fibers (Nolte, Figure 21-13, pp. 532) that control eye movements that compensate for changes in head position (vestibulo ocular reflexes).

### 2. *Supranuclear Control of Eye Movements*

The supranuclear pathways controlling extraocular movements are not fully understood. The following is an operational outline of the pathways involved in the control of guided and reflex saccades and smooth pursuit, based on animal experimentation and clinicopathologic correlations in patients with eye movement disorders. In the following discussion, keep in mind that the entire visual pathway, the retina, lateral geniculate body and visual cortex, is involved in determining whether the image is in focus on the fovea.

#### a. Saccades

Saccades are rapid (ballistic) conjugate eye movements that are under both voluntary and reflex control.



The eyes execute a series of very rapid movements from one point to another, stopping briefly at each point, the fixation point, to check the visual image (Nolte, Figure 21-11, pp. 531). Normally we are unaware of these sudden stops as the visual association cortex provides visual constancy and blends each brief image into a smoothly changing view of the visual world. During a saccade, the control signal is retinal position error. Examples of voluntary saccades are self-directed eye movements and those in response to command (e.g., “look to the right”). The sudden appearance of a peripheral object or an eccentric sound may evoke a reflex saccade in the direction of the stimulus.

**VOLUNTARY SACCADDES:** The neural commands generating voluntary saccades appear to originate mainly in a region of the frontal lobe referred to as the frontal eye field (area 8 of Brodmann) in conjunction with input from the supplementary eye field (also in frontal cortex) and from the parietal cortex. The frontal eye field is located in the caudal portion of the middle frontal gyrus and extends into contiguous areas of the inferior frontal gyrus (Nolte, Fig. 21-13, pp. 532). The frontal eye field of one hemisphere controls voluntary saccadic eye movements that are directed toward the contralateral visual hemifield, i.e., the right frontal eye field directs the eyes to the left. Thus, a lesion of the frontal eye field in the right hemisphere could produce an abnormality in the generation of leftward moving saccades that involves both eyes. The corticofugal projections from the frontal eye fields travel in the internal capsule and decussate near their site of termination. Some terminate in the superior colliculus, which sends its axons to the midbrain vertical gaze center and the pons horizontal gaze center. Many corticofugal projections travel directly to and end in the pons horizontal gaze center. The direct cortical projections to the horizontal gaze centers control voluntary lateral (horizontal) saccades. There appears to be no direct frontal eye field projection to the vertical gaze centers.

**GAZE CENTERS:** The midbrain vertical gaze center sends its axons bilaterally to the trochlear nuclei, which control the superior obliques, and to the oculomotor neurons controlling the inferior obliques and the inferior and superior rectus muscles. During vertical saccades, the midbrain vertical gaze centers insure that the superior and inferior recti act in synergy to produce conjugate movements of the eyes. The pons horizontal gaze center sends its axons to the ipsilateral abducens nucleus, which contains interneurons that send their axons in the contralateral medial longitudinal fasciculus back up to oculomotor neurons controlling the medial rectus muscle. During horizontal saccades, the pons horizontal gaze centers insure that the medial and lateral recti act in concert to produce conjugate horizontal eye movements.

**REFLEX SACCADDES:** Reflex saccadic eye movements appear to be initiated in the superior colliculus, which receives direct input from the retina, inferior colliculus, and cortex. From the superior colliculus, the control of reflex saccades is identical to that described for the voluntary saccades. That is, the superior colliculus sends axons to the midbrain vertical gaze centers and the pontine horizontal gaze centers.

#### b. Smooth Pursuit

The major stimulus for a pursuit eye movement is a fixated target that moves; this evokes a following or tracking eye movement. Smooth pursuit eye movements are conjugate and under a control system capable of continuous modification of motor output in response to visual input (in contrast to discrete saccadic control). The movement is used to follow slow-moving, predictable targets. Damage to one-hemisphere results in a unidirectional pursuit abnormality toward the damaged hemisphere.

Smooth pursuit movements appear to be initiated by neurons in the ipsilateral parietal and temporal (predominantly) cortex. These cortical neurons are responsible for determining the speed and direction of pursuit movements (These cortical areas should have been interposed between the extrastriate cortex and dorsolateral pontine nuclei in Nolte, Fig. 21-16, pp. 535). The frontal eye field is also involved in smooth pursuit; its neurons help determine the degree and rate of eye movement. The axons of all these cortical neurons descend as corticopontine fibers and terminate on dorsolateral pontine nucleus neurons. These pontine neurons send their axons to the cerebellum, which, in turn, control vestibular nuclear complex neurons. Recall that the vestibular nucleus neurons control the position and velocity of the eye movements via their input to the cranial motor neurons innervating the extraocular muscles. Notice that smooth pursuit does not involve neurons in the gaze centers. The parieto-temporal eye fields are considered critical for smooth pursuit as they initiate and guide these types of eye movements. When there is damage to this area, eye movements tracking moving targets are not smooth and resemble saccades, i.e., they are “jerky.”

### c. Vergence

The supranuclear control of convergence (initiated for near vision) and divergence (initiated for distance vision) involves the supraoculomotor area (SOA) of the midbrain (Nolte, Fig. 17-41, pp. 454). When there is a binocular disparity (a marked difference between the images falling on the two foveas), control signals are sent from cortical neurons to the SOA. Neurons in the SOA project to motor neurons controlling the medial and lateral rectus muscles. During accommodation (the near response), the medial recti contract while the lateral recti relax, directing both eyes nasally. When shifting gaze from a closer object to one further away, the medial recti relax while the lateral recti contract.

This control pathway does not include the pons horizontal gaze centers or the medial longitudinal fasciculus and damage to either (the horizontal gaze center or MLF) will not affect vergence movements but will disrupt all types of lateral conjugate eye movements.

## 3. Control of Pupil Size & Lens Shape

### a. Infranuclear Control of Pupil Size & Lens Shape

The regulation of pupil size and lens curvature involves the autonomic nervous system. Stimulation of the cranial parasympathetic system results in the constriction of the pupil and increased lens curvature, while stimulation of the spinal sympathetic system results in the dilation of the pupil. The cranial or parasympathetic motor pathway involved in pupil constriction and in lens accommodation includes the Edinger Westphal nucleus of the oculomotor nuclear complex (the preganglionic parasympathetic neuron), the oculomotor nerve (in which the preganglionic parasympathetic fibers travel), and the ciliary ganglion (the postganglionic parasympathetic neuron). The postganglionic axons travel in the short ciliary nerve to the sphincter muscle of the iris and to the ciliary muscle of the ciliary body. (Recall that the ciliary muscles control lens position and curvature.) The spinal or sympathetic motor pathway involved in pupil dilation includes lateral horn cells of the upper thoracic segments (the preganglionic sympathetic neurons), the anterior root (in which the preganglionic sympathetic fibers leave the spinal cord), and the superior cervical ganglion (the postganglionic sympathetic neurons). The postganglionic sympathetic fibers terminate on the dilator muscle of the iris.

### b. Supranuclear Control of Pupil Size & Lens Shape

**PUPILLARY LIGHT REFLEX:** When light falls on the retina of one eye, the pupils of both eyes will

constrict in a consensual pupillary reaction. The afferent arm of the reflex pathway includes retinotectal fibers in the optic nerve and tract: that is, retinal ganglion cells' axons that travel in the brachium of the superior colliculus to terminate in the pretectal area (Nolte, Fig. 17-39, pp. 453). The axons of the pretectal neurons decussate partially in the posterior commissure and in the periaqueductal gray anterior to the aqueduct to terminate bilaterally in the Edinger Westphal nucleus. Recall the Edinger-Westphal (preganglionic) neurons send their axons in the oculomotor nerve to the ciliary ganglion and that it is the postganglionic fibers in the short ciliary nerve that innervate the iris sphincter muscle. Because the visual and pretectal inputs are bilateral to each Edinger-Westphal nucleus (i.e., in the optic tract and posterior commissure), the reflex is consensual (both pupils contract when light falls on one eye).

**PUPILLARY "DARK" REFLEX:** When the light falling on both retinas is removed, the pupils of both eyes will dilate to increase the total amount of light entering the eyes. Some optic nerve fibers travel to and terminate in the hypothalamus. Presumably, the hypothalamic neurons send their axons to structures that influence the activity of the lateral horn (preganglionic sympathetic) cells in upper thoracic spinal cord. The preganglionic sympathetic axons, in turn, travel to and end on sympathetic ganglion cells that control the dilator muscle of the iris.

**PUPILLARY ACCOMMODATION RESPONSE:** The third type of pupillary response is the accommodation or near point response (pupil constriction) that accompanies the convergence of the eyes and lens accommodation during near vision (Nolte, Figure 17-41, pp. 454). The near point reaction of the pupil involves (1) the visual pathway, (2) the parieto occipital visual association areas, and (3) the supraoculomotor area. The neurons in the supraoculomotor area project bilaterally to the Edinger Westphal nucleus. Because the supranuclear control of the two pupillary constrictor responses differ (i.e., pretectal area for light reflex and supraoculomotor for accommodation), it is possible to have a lesion that interferes with the pupillary light reflex but maintains the pupillary response in near vision (i.e., the Argyll Robertson pupil with bilateral damage to the pretectal area) or vice versa.

**LENS ACCOMMODATION RESPONSE:** The pathway involved is identical to that of the pupillary accommodation response: that is, visual association cortex to supraoculomotor area, to Edinger-Westphal nucleus, to ciliary ganglion, and to the ciliary muscles via the short ciliary nerve. During the near point response, the contraction of the ciliary muscles decreases the tension on the suspensory ligaments, which releases the tension on the lens capsule. The lens becomes more convex with its anterior pole shifted more anteriorly. The result is an increase in the refractive properties of the lens so that the image of the object of view is in focus on the fovea of the retina.

## Answers

---

- 7-1. The retinal bipolar cells
- 7-2. Anterior commissure
- 7-3. Internal carotid artery
- 7-4. Anterior & middle cerebral, ophthalmic, posterior communicating, & anterior choroidal
- 7-5. Optic nerve fibers from the nasal half of the retina
- 7-6. Optic nerve fibers from the temporal half of the ipsilateral retina & from the nasal half of the contralateral retina
- 7-7. The lateral geniculate nucleus (LGN) of the thalamus
- 7-8. medial rectus, superior rectus, inferior oblique, and inferior rectus
- 7-9. Ciliary ganglion

7-10. The sphincter of the iris & ciliary of the ciliary body

7-11. Yes, the left eyelid will droop because the oculomotor nerve fibers normally innervating it are destroyed. However, if the left oculomotor nuclei were destroyed, eyelid droop would not occur. However, eyelid opening may be less brisk and weaker because half of the innervation of the left superior palpebrae is destroyed.

## Structures You Need To Know For Laboratory 7: Visual System

---

### The Receptor Slides

- Sclera
- Cornea
- Optic nerve
- Iris
- Ciliary body
- Lens
- Ciliary muscles
- Suspensory ligaments
- Pupil
- Retina
- Optic disc or papilla
- Anterior chamber
- Posterior chamber
- Vitreous chamber
- Optic disc
- Optic papilla
- Choroid
- Retinal pigment epithelium
- Layers of Retina
  - Receptor layer
  - Outer nuclear layer
  - Inner nuclear layer
  - Ganglion cell layer
  - Outer plexiform layer
  - Inner plexiform layer
  - Optic nerve fiber layer
- Macula & Fovea
- Optic disc

### Gross - Inferior Brain

- Optic nerve
- Optic chiasm - note its proximity to the pituitary stalk
- Optic tract
- Oculomotor nerve - note its proximity to the posterior cerebral artery Abducens nerve

### Gross - Hemisected Brain

- Lateral geniculate body

- Occipital lobe - blood supply primarily from posterior cerebral artery Parieto-occipital sulcus
- Preoccipital notch
- Calcarine sulcus
- Calcarine or striate cortex
- Cuneate and lingual gyri
- Parieto-occipital visual association area
- Temporo-occipital visual association area
- Frontal eye field
- Middle frontal gyrus
- Inferior frontal gyrus
- Parietotemporal eye field
- Superior colliculus

#### **Visual System Structures in Photomicrograph Slides & DeArmond Atlas**

- Optic nerves
- Optic chiasm
- Optic tracts
- Lateral geniculate body & nucleus
- Layers of the lateral geniculate nucleus
- Optic radiations (Geniculocalcarine fibers)
- Sublenticular radiations of internal capsule
- Retrolenticular radiations of internal capsule
- Layers of the calcarine (striate) cortex

#### **Visual Motor Structures in Photomicrograph Slides & DeArmond Atlas**

- Pretectal area
- Superior colliculus
- Brachium of the superior colliculus
- Posterior commissure - note its proximity to the pineal gland
- Periaqueductal gray
- The vertical gaze center which includes the Interstitial nucleus of Cajal
- Medial longitudinal fasciculus
- Supraoculomotor area
- Oculomotor nuclei
- Edinger-Westphal nucleus
- Trochlear nuclei
- Abducens nucleus & nerve
- Tectospinal tract which includes tectopontine fibers
- Horizontal Gaze Center (Pontine paramedian reticular formation)
- Spinal trigeminal nucleus & tract
- Facial motor nucleus

# Laboratory Exercise #8: Higher Motor Function

Lecturer: Michael Beauchamp, Ph.D. and Nachum Dafny, Ph.D.

March 20, 2012 1:00 PM

## Required Reading

---

- Nolte, Chapter 18, Overview of motor systems
- Nolte, Chapter 19, Basal Ganglia.
- Nolte, Chapter 20, Cerebellum.

## Introduction

---

The purpose of this laboratory exercise is to study the anatomical organization of the motor structures involved in the planning, execution, and adaptation of skilled movements. Skeletal muscles are under direct neural control of motor neurons in the anterior horn of the spinal cord and in certain brainstem cranial nerve nuclei. The initiation and control of voluntary movement and the regulation of posture and muscle tone involve numerous neural centers at all levels of the neuraxis, from the spinal cord to the cerebral cortex. Planning and initiating movements are thought to be mediated by cerebral cortex, thalamus, basal ganglia, and the cerebellum. The descending pathways that are involved in the execution of these movements will be covered in Exercises 9 & 10. At the end of the present exercise you should be able to:

1. Identify motor areas within the cerebral cortex.
  2. Describe the interconnections of the cortex, thalamus, basal ganglia and related structures.
  3. Identify the cellular components of the cerebellum and its afferent and efferent connections.
- **Part A**  
**Examination Of Wet Human Brain Material**
    1. Your row's human specimens
    2. Demonstration material presented by teaching assistants
  - **Part B**  
**Complete Exercise Mode Of Laboratory #8 Of Neurolab**
    1. Each student should go through the NeuroLab Online computer program review mode prior to the laboratory.
  - **Part C**  
**An Exercise At The End Of The Laboratory (~3:30 P.M.) To Assess Your Learning Progress**
  - **Part D**  
**Post-Laboratory Review Using Clinical Cases**

## Materials

---

As in the other exercises, learn to identify the names, locations, connections, and functions of the structures in **bold** type and learn the information provided about the structures in *italics*. In addition, learn the major inputs, outputs and general functions listed in Tables 8-I and 8-II. You will be working with the whole brain specimen; removing the brain stem and cerebellum and slicing the brain either coronally or horizontally. You will examine these slices along with .

*Figures from DeArmond:* **1, 2, 3, 4, 5, 7, 10, 12, 13, 14, 15, 16, 17, 18, 19, 20, 21, 22, 23, 24, 25, 26, 27, 28, 29, 55, 62, 65, 67, 68, 71, 77, 80, 86, 99, 101, 103**

*Figures from Nolte:* **16-6, 18-10, 20-1, 20-2, 20-7, 20-10, 20-21, 21-13, 22-1 and table 20-2.**

*Brainiac:*

- **BRAINIAC: P-W** (P-W Sections)
- **BRAINIAC: GYRI AND SULCI** (Gyri and Sulci)
- **BRAINIAC: CORONAL SECTION** (Coronal sections)
- **BRAINIAC: HORIZONTAL SECTION** (Horizontal Sections)

Materials

- Aluminum pan or cookie sheet
- Squeeze bottles with water or bleach
- Cleanup towels for any dripping or spillage
- Cheese cloth (To wrap sectioned brain)
- Brain spatula knife
- Gallon sized sealable plastic bag

*You need to bring:*

- Brain specimen bucket containing:
  - Whole brain specimen
  - Hemisected brain specimen
- Gloves
- Dissection kit
- Permanent marker (Sharpie)
- You may want to bring an plastic apron to protect your clothes.

## Cerebellum and Brain Stem

---

Identify the main parts of the cerebellum (Nolte, Fig. 20-1, Table 20-1) including the: **vermis, cerebellar hemispheres, primary fissure, anterior lobe & posterior lobe**. Note the spatial relationships of these cerebellar structures to the underlying brain stem. While removing the cerebellum and brain stem, take care to keep intact the blood vessels and meninges on the anterior surface of the lower brain stem to secure the positions of the cranial nerves **PRIOR TO ANY CUTTING OF YOUR BRAIN, LABEL THE 1 GALLON PLASTIC BAG WITH THE INVENTORY NUMBER ON YOUR BRAIN.** After sectioning your brain specimen return all of the sectioned parts to this bag. Include the cerebellum,

brainstem and sectioned whole brain and do not mix them up with the other specimens in your specimen container.



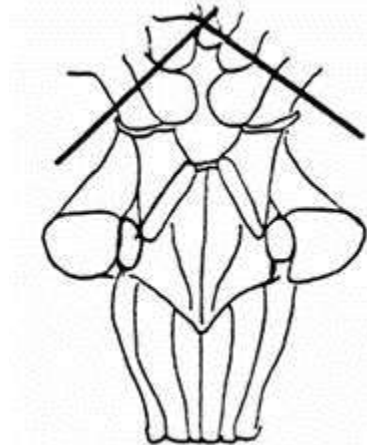
### A. Remove the Cerebellum

1. Place the brain in an inverted position with the cut end of the brain stem facing you.
2. Pull the brain stem upward and, using a pair of blunt forceps, carefully pull away the blood vessels and meninges that connect the brain stem to the cerebellum.
3. When you are able to see the **inferior & middle cerebellar peduncles** entering the cerebellum, use a scalpel or short knife to *carefully* cut through the inferior and middle cerebellar peduncles up to the *mid portion* of the middle cerebellar peduncle.
4. Cut as close as possible to the cerebellum without damaging it. *Cut* these peduncles on both the left and right sides. **NOTE:** If properly executed, these cuts will not sever the cerebellum from the brain stem: The more rostrally located superior cerebellar peduncles and the remaining halves of the middle cerebellar peduncles should continue to maintain the attachment of the cerebellum to the **pons**.
5. Hold the brain such that it is resting on the **frontal poles** of the cerebrum, with the anterior surface of the brain stem facing you. *Retract* the cerebellum and brain stem towards you and with the forceps pick away at the blood vessels and meninges attaching the cerebellum to the cerebrum and brain stem.
6. When the roof of the **midbrain** is exposed, look for the structures forming the **midbrain tectum**, i.e., the **inferior & superior colliculi** (Nolte, Fig. 11-3A, pg. 270). The **trochlear nerve** should be seen emerging caudal to the inferior colliculi near the pons-midbrain junction. The **pineal body** is attached to the posterior surface of the brain - at the junction of the midbrain to the **diencephalon**.
7. Place the brain on its side and continue to clear away blood vessels and meninges until the lateral aspect of the midbrain is exposed to view. Trace the middle cerebellar peduncle upward into the cerebellum and the **superior cerebellar peduncles** passing from the midbrain upward into the cerebellum.
8. Retract the cerebellum backward, and carefully cut the superior cerebellar peduncles and the remaining portions of the middle cerebellar peduncle close to the cerebellum (DeArmond, Fig. 5, pg. 10).
9. Carefully remove the cerebellum, cutting or tearing away any tissues connecting it to the brain stem.
10. Notice that the **fourth ventricle**, a diamond-shaped cavity, is exposed by the removal of the cerebellum (DeArmond, Fig. 5, pg. 10). The fourth ventricle extends from the rostral border of the pons to the middle of the medulla. The floor of the ventricle is formed by the posterior surfaces of the pons and medulla and its roof by the cerebellum and the superior & inferior medullary velli.
11. The **choroid plexus**, which projects along the midline and laterally in the caudal part of the fourth ventricle, appears as a *tufted, vascular fold of pia mater*. If any of the choroid plexus remains, examine it before removing it to expose the posterior surface of the lower brain stem.
12. Notice the angle of entry of the brain stem into the core of the cerebrum. The 90° angle of entry is unique to humans, a normally upright, bipedal mammal.

### B. Transect the Brain Stem

1. Working on the anterior surface of the brain stem, *carefully* remove the meninges and blood vessels of the **circle of Willis** until the **cerebral peduncles** or **crus cerebri** of the midbrain and the **mammillary bodies** of the diencephalon are in clear view (DeArmond, Fig. 3, pg. 6; Fig. 99, pg. 187).

2. Notice the large **oculomotor nerves** emerging from the **interpeduncular fossa**. More rostrally, notice that the **optic nerves** course caudally along the orbital surface of the frontal lobes and join at the **optic chiasm**, rostral to the **infundibulum**. The **olfactory bulbs & tracts** can be seen between the **orbital gyrus** and **gyrus rectus** of the frontal lobe. The medullary **pyramids** can be seen near the midline caudal to the pons.
3. Place the brain on its side with the brain stem facing you and clear away the meninges and blood vessels on the lateral surface of the midbrain.
4. Gently pry the cerebrum and brain stem apart to expose the course of the **cerebral peduncles** into the core of the cerebrum. Notice the **medial geniculate body** of the thalamus located posterior to the cerebral peduncle (DeArmond, Fig. 5, pg. 10).
5. Figure 8-1 of this Exercise (below) illustrates the cuts to be made to sever the brain stem from the diencephalon. With the brain still on its side, place the knife blade against the cerebral peduncle, with the blade angled rostrally. Before cutting, make certain the knife will cut caudal to the mammillary bodies and through the boundary between the inferior and superior colliculi.
6. Turn the brain over so that its posterior surface faces you and sever the other half of the brain stem from the diencephalon as in Step 5.



*FIGURE 8-1: Diagram of cuts to separate the brain stem from the diencephalon.  
Be certain to cut from the lateral edge towards the midline.*

7. Examine the cut edge of the midbrain and look for the black band formed by the **substantia nigra**. It is located just posterior to the **crus cerebri** (a.k.a. cerebral peduncles). Locate the two large reddish-gray structures, the **red nuclei**, situated along the midline just posterior to the substantia nigra.
8. Observe the small channel formed by the **cerebral aqueduct**, just anterior to the midbrain tectum. Recall that the cerebral aqueduct connects the third ventricle to the fourth ventricle.

## Motor Areas of Cerebral Cortex

---

A number of cerebral cortical areas are closely involved with the initiation and descending control of voluntary movement. Some cortical areas influence brainstem or spinal cord motor neurons directly or indirectly through interneurons. Other cortical areas influence the activity of "motor cortical areas" or the activity of nuclei which send their axons to motor neurons (e.g., the red nucleus). *As a general rule*, cortical areas represent the contralateral side of the body or face. Consequently, electrical stimulation of the *left* motor cortex will produce movement on the *right* side of the body, and vice versa.

### A. Review the Cerebral Cortex

#### Brainiac: Gyri and Sulci

1. Clear away the meninges and blood vessels from the lateral and inferior surfaces of the cerebrum and diencephalon.
2. Look for the **longitudinal fissure, lateral fissure, & central sulcus**.

### B. Frontal Cortical Areas

1. The **primary motor cortex** (Nolte, Fig. 18-1- & Fig. 22-1) is located within the **precentral gyrus**.
2. The **premotor area** is also within the precentral gyrus rostral to the primary motor cortex and extends rostrally to include the caudal half of the frontal lobe (Nolte, Fig. 22-1). The premotor area is thought to be involved with preparation for movement and developing appropriate motor strategies.
3. The **supplementary motor** area occupies the medial aspect of the **superior frontal gyrus** rostral to the **precentral sulcus**. This area appears to be important for *programming motor sequences* involved in complex motor tasks.
4. The **frontal eye-field** is located within the caudal part of the **middle frontal gyrus and the precentral sulcus** (Nolte, Fig. 21-12). Electrical stimulation of this region elicits *conjugate movement of the eyes to the contralateral side*. Lesions of this area result in deviation of the eyes towards the side of the lesion and inability to voluntarily, but not reflexively, move the eyes contralaterally.
5. **Broca's speech area** is located within the caudal part of the **inferior frontal gyrus**, i.e., in the **pars triangularis & opercularis** of the dominant hemisphere (DeArmond, Fig. 2, pg. 4). The *dominant hemisphere* is the hemisphere that is important for the comprehension and production of speech/language. Normally, it is the left hemisphere of right-handed people. Broca's speech area is important for the production (expression) of speech/language. What is the clinical term for language disorders that accompany lesions of this area? (8-1).

### C. Parietal Cortical Areas

#### Brainiac: Gyri and Sulci

1. In addition to these motor cortical areas in the frontal lobe, cortical areas within the parietal lobe also are important for the control of voluntary movement. Parietal regions, along with frontal cortex, contribute axons to the pyramidal tract-the direct pathway linking the cerebral cortex and spinal cord. The primary somatosensory cortex in the **postcentral gyrus** is also substantially interconnected with the primary motor cortex in the precentral gyrus. The **superior parietal lobule** and the **precuneus** (DeArmond, Fig. 1, pg. 2; Fig. 4, pg. 8) are interconnected with premotor and supplementary motor cortex.

## Cortical Projections

---

Descending axons from motor areas of the cerebral cortex travel through the posterior limb of the internal capsule. You will be slicing the whole brain specimen and tracing the course of the motor corticofugal fibers from the cerebral cortex to the midbrain within these slices.

### A. Slicing the Whole Brain

Now that you have removed the cerebellum and the brain stem at the midbrain, you will be making slices through the whole brain specimen. Make your cuts with a single smooth drawing stroke with a *wet* brain knife (do not saw through the tissue). Remember, you will be examining these slices in several exercises, so cut them carefully, handle them gently, and store them in the cheese cloth aprovided you. As you slice the brain, place the slices on the cheese cloth *in sequence* with the side facing the knife facing up.

You will be slicing the whole brain either in the horizontal (Brainiac: Horizontal Section) or coronal plane (Brainiac: Coronal Section) - but *only after* you have arranged with another student group to slice and share sections in a plane different from the sections you prepare. *Before* slicing, be certain to clear off as much of the blood vessels and meninges as is possible. The slices will be ruined if the knife blade catches on a blood vessel and drags it through the brain.

**Coronal Sections** Place the brain on its superior surface so that the mammillary bodies are facing you. Note: This is the brain position used by the Woolsey Brain atlas, so what you see may differ from the pictures in the De Aramond atlas plates. After making your observations, place each section on your pan or cookie sheet in order and in normal anatomical relationship to organize your study [it can be very challenging to reconstruct a scrambled brain]. Make your first section about 2 cm in front of of the optic chiasm (made perpendicular to the interhemispheric (syn. Longitudinal) fissure) and you should be able to see the head of the **caudate nucleus**, **frontal horn of the lateral ventricle**, and perhaps the **nucleus accumbens**. The second section should be 1 cm in front of the optic chiasm should expose the **head of the caudate**, the **nucleus accumbens**, the **putamen and anterior limb of the internal capsule**. The third section should be through the **optic chiasm** will reveal the **caudae**, **putamen**, **anterior commissure**, other structures and you may see the **amygdala** in the temporal lobe. A section between the optic chiasm and the mamillary bodies (near infundibulum) can show the **caudate**, **putamen and globus pallidus and insula**. Try to make a section through the **mammillary bodies** parallel to the first cut which may reveal the **VL thalamus**. Next section on this plane, cutting through the approximate position of the red nuclei can show the continuous tract from the **corona radiata**, **posterior limb of the internal capsule**, and **cerebral peduncle**.

After making each cut, look for the various segments of the **lateral ventricles** in the remaining portion of the brain. For some examples of brain slices, see Brainiac: Coronal Section and DeArmond, Figs. 20 - 30, pp. 40 - 60.

**Horizontal Sections:** Place the brain on its side with the frontal pole facing away from you. Starting superiorly at a level parallel to line #17 in DeArmond, Fig. 7 (pg. 15), cut a series of horizontal sections approximately 1 to 2 cm thick. After making each slice, examine the remaining portion of the brain to see if you can identify the various segments of the **lateral ventricles** (e.g., Brainiac: horizontal section, DeArmond, Figs. 11 through 17, pp. 22 - 34).

### B. Corticofugal Projections

The corticofugal fibers originate from layer V, the **internal pyramidal layer** of the cerebral cortex (DeArmond, Fig. 86, Area 4, pg. 171). They form a continuous pathway from the cortex, traveling between the basal ganglia and diencephalon (identifiable as the internal

capsule), through the brain stem (identifiable as the **crus cerebri of the midbrain and the pyramids of the medulla**) and down into the spinal cord (Nolte, Fig. 18-8).

### Horizontal Sections:

1. Starting with the most superior slice, note how the axons of the cortex are collecting to form the **corona radiata**. Find a horizontal section similar to DeArmond, Fig. 16 (pg. 32).
2. Notice the **optic radiations** passing through the retrolenticular segment of the internal capsule in this and subsequent sections.
3. On a horizontal section similar to that pictured in Figs. 13 - 14 of DeArmond (pp. 26 - 28), note that the **anterior limb of the internal capsule** divides the **caudate head** from the **lenticular nucleus (putamen + globus pallidus)**, and the **posterior limb** divides the **thalamus** from the **lenticular nucleus**. (The lenticular nucleus is sometimes called the lentiform nucleus).
4. Note the compact fiber density in the **posterior limb of the internal capsule**. From a clinical perspective, what might be the functional significance of a relatively small lesion in the posterior limb? \_\_\_\_ (8-2). What is the arterial supply to this part of the internal capsule? \_\_\_\_ (8-3).
5. Trace the course of the corticofugal axons as they travel through the internal capsule to emerge at the diencephalic/mesencephalic junction as the **crus cerebri** in sections similar to those pictured in DeArmond Fig. 11 & 12 (pp. 22 - 24).
6. Make one horizontal cut near the middle of the temporal lobe for use in later labs.

### Coronal Sections:

1. Using De Armond (Figs. 20 through 25 on pages 40 through 50), examine the course of the corticofugal fibers in the coronal slices. Notice how the cortical axons enter the white matter in radially arranged bundles that converge towards the **internal capsule**. These radiating fibers form the **corona radiata**.
2. In a slice similar to Fig. 21 of De Armond, notice the **anterior limb of the internal capsule** separating the **caudate head** from the **putamen**.
3. In a more caudal slice (e.g., like Figs. 24 - 26 in De Armond), notice how the **posterior limb of the internal capsule** separates the **caudate body & thalamus** from the **globus pallidus & putamen**.
4. In a slice similar to that pictured in Fig. 24 of De Armond, follow the fibers of the internal capsule into the **crus cerebri** (labeled cerebral peduncle in DeArmond) of the midbrain.

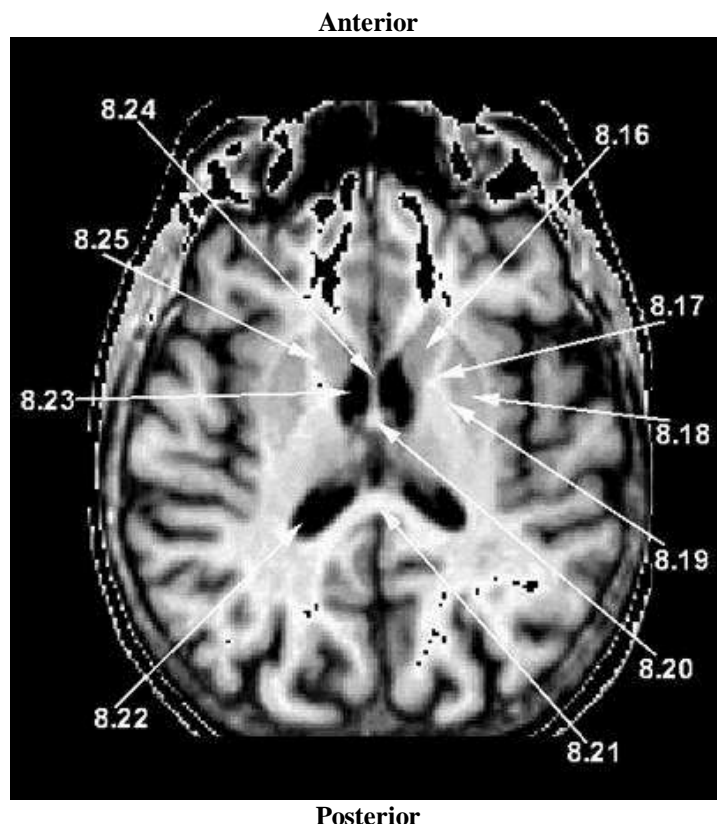
## Thalamic Nuclei

---

In the following sections, note the relationship of the thalamus to the basal ganglia on the horizontal and coronal slices. Be certain you can identify the various components of the basal ganglia and internal capsule on a series of horizontal and coronal slices. The caudate, putamen, globus pallidus and substantia nigra are extremely important physiologically in motor control. Huntington's chorea and Wilson's disease are examples of diseases that affect these structures. You will be unable to identify most of the thalamic nuclei in the brain slices. The thalamic nuclei considered to play a major role in motor function include the ventral anterior (VA) and ventral lateral (VL) nuclei. Part of the centromedian nuclei (CM) also appears to have motor functions.

### Thalamic Nuclei Visible in Brain Slices

1. In a horizontal slice similar to Fig. 15 of DeArmond (pg. 30), see if you can locate the **anterior (A) thalamic nuclei**. They should appear as small knobs at the anterior- medial margin of the thalami.
2. In a coronal slice similar to Fig. 25 of DeArmond (pg. 50), notice that the **internal medullary lamina** divides the thalamus into three groups; the **anterior**, medial (i.e., DM), and lateral (i.e., VL) nuclear groups
3. In a coronal slice similar to Fig. 24 of DeArmond (pg. 48), you should be able to locate the **anterior thalamic nucleus**. The other thalamic nuclei are not as easily identified in gross, unstained slices of the brain.



**FIGURE 8-3** MRI horizontal section at the level comparable to that of DeArmond Fig. 16, pg. 28.(left) Can you identify the structures at the end of the pointers? Remember that on this MRI image, the lighter areas represent white matter; the gray areas represent subcortical nuclei or surrounding cortical areas; and the black areas represent ventricles.

## The Basal Ganglia

The basal ganglia include the *caudate*, *putamen* & *globus pallidus* (which is part of the telencephalon), the *subthalamic nucleus* (which is part of the diencephalon) and the *substantia nigra* (which is part of the midbrain). The major input to the basal ganglia is from the cerebral cortex and terminates in the *neostriatum* (i.e., the caudate and putamen). Other inputs to the neostriatum arise from the substantia nigra and intralaminar nuclei (CM) of the thalamus. In turn, the neostriatum sends its axons to the globus pallidus and substantia nigra.<sup>[2]</sup>

The globus pallidus receives its major input from the neostriatum and sends its axons to the VA, VL & CM thalamic nuclei. The VA and VL thalamic nuclei, in turn, send their axons to the frontal cortical areas controlling motor function. The globus pallidus also sends axons to and receives axons from the *subthalamic nucleus*. Lesions of the subthalamic nucleus produce a distinctive movement disorder called *hemiballismus* that is characterized by flailing movements of the contralateral limbs.

The substantia nigra, which also receives its major input from the neostriatum, sends axons back to the neostriatum, and to the VL & VA thalamic nuclei, superior colliculus and reticular formation. The substantia nigra also receives a smaller input from the globus pallidus and subthalamic nucleus. The nigral projection back to the neostriatum is via a *dopaminergic pathway*. Damage to this pathway produces the symptoms of *Parkinson's disease*.

## Basal Ganglia in Brain Slices

### A. HORIZONTAL SLICES

1. In a horizontal slice similar to Fig. 10 of DeArmond (pg. 20), notice that, in the right hemisphere, the **caudate head** and **putamen** are continuous and form the **neostriatum**.
2. In a horizontal slice similar to Fig. 11 of DeArmond (pg. 22), the **caudate head** and **putamen** continue to form the **neostriatum**. The midbrain component of the basal ganglia (the **substantia nigra**) can be identified as a dark band of cells lateral to the **red nucleus**.
3. In a horizontal slice similar to Fig. 13 of DeArmond (pg. 26), notice that the **anterior limb of the internal capsule** separates the **caudate head** from the **putamen** and that the **posterior limb of the internal capsule** separates the **thalamus** from the **lenticular nucleus (globus pallidus & putamen)**. A thin, slightly sinuous strip of gray matter, the **claustrum**, lies between the lateral boundary of the putamen and the **insula**, the strip of cortex that lies deep within the **lateral fissure**. The claustrum is of obscure significance. The thin strip of white matter between the putamen and claustrum is called the **external capsule**, and the white matter separating the claustrum from the insular cortex is the **extreme capsule**. The external and extreme capsules contain *association (cortico-cortical) fibers*, as compared to the projection (corticofugal) fibers within the internal capsule.

### B. CORONAL SLICES

1. In a coronal slice similar to DeArmond Fig. 22 (pg. 44), identify the **caudate head**, which is separated from the **lentiform nucleus (putamen & globus pallidus)** by the **anterior limb of the internal capsule**. Note that none of the thalamic nuclei are present at this level.
2. In a slice similar to DeArmond Fig. 24 (pg. 48), notice that the **posterior limb of the internal capsule** now separates the **caudate body** and **thalamus** from the **lentiform nucleus**. Note also the fibers of the internal capsule sweeping inferior to the **subthalamic nucleus** and **substantia nigra** to form the **crus cerebri** (called *cerebral peduncles* by DeArmond). All components of the basal ganglia (caudate, putamen, globus pallidus, subthalamus, and substantia nigra) are present in the slice pictured in DeArmond Fig. 24.

## Gross Specimen

1. The cerebellum comprises the cortex, which is visible in gross inspection, and the underlying cerebellar nuclei. The cerebellar cortex consists of a midline band, the **vermis**, and two expanded lateral lobes or hemispheres. By looking at the inferior surface of the cerebellum, the sharpest differentiation between the vermis and **cerebellar hemispheres** may be made (DeArmond, Fig. 3, pg. 6).
2. On the superior surface (Nolte, 20-1), find the **primary fissure** separating the **anterior lobe** from the **posterior lobe**.
3. Inferiorly, find the **posterolateral fissure**, which separates the **flocculonodular lobe** from the **posterior lobe** (Nolte, Figs. 20-4).
4. Locate the three pairs of cerebellar peduncles. Note that the **superior cerebellar peduncle** is the *major efferent tract* out of the cerebellum. The fibers of the **middle cerebellar peduncle** arise from which brainstem nuclei? (8-12). The **inferior cerebellar peduncle** connects the cerebellum with the medulla and spinal cord.



5. With a *wet* brain knife, bisect the cerebellum in the midsagittal plane (i.e., with the knife on the vermis, split the left cerebellar hemisphere from the right). Notice on the cut surface that the posterolateral fissure separates the vermal lobes labeled h and i in Fig. 4 of DeArmond (pg. 8).
6. Find the **nodulus** on the midline of the vermis and the **flocculus**, which is located more laterally on the inferior surface. Which peduncles carry the major source of input to the cerebellum? (8-13).
7. Take one half of the bisected cerebellum and cut it in the horizontal plane, through the **horizontal fissure** (De Armond, Fig. 9, pg. 18. see the inset).
8. Examine the cut surface of the horizontal slices and see if the **dentate nuclei** (which resemble the inferior olivary complex) are visible. If they are not, try cutting another horizontal slice 1 cm from the cut surface. The dentate nucleus is the largest and most laterally located of the cerebellar nuclei (Nolte, Fig. 20-7). It is the only cerebellar nucleus that can be visualized in the unstained specimen. (See DeArmond, Fig. 29)
9. Two small nuclei, the *emboliform* & *globose nuclei*, are located medial to the **dentate nucleus**. They collectively are called the *interposed nucleus* because they are located between the dentate nucleus and the most medially located *fastigial nucleus* (Nolte, 20-7).
10. Take the other half of the bisected cerebellum and cut it in the sagittal plane approximately 1 to 2 cm from the midsagittal surface. Examine the cut edges of the sections to see if you can find the **dentate nucleus**.

### Histology of the Cerebellar Cortex

1. Examine DeArmond Fig. 62a & 62b (pg. 125), which are Nissl-stained sections of the cerebellar cortex. Notice that the cerebellar cortex is comprised of three layers that surround the inner core of white matter.
2. The innermost layer is composed of *granule cells* and is called the **granule cell layer**. A middle layer (which is one cell in thickness) contains *Purkinje cells* and is called the **Purkinje cell layer**. Purkinje cell axons are the sole output of the cerebellar cortex. The outermost layer is called the **molecular layer**. The molecular layer contains three types of interneurons, named Golgi, basket and stellate cells. It also contains fan-like dendritic arbors of the Purkinje cells (all arranged in parallel in a rostral-caudal orientation) and the axons of the granule cells.
3. The granule cell axons are called *parallel fibers*. In the molecular layer, they run parallel to one another and perpendicular to the plane of the Purkinje cell dendrites. The parallel fibers synapse on the dendritic spines of the Purkinje cells. Why is the axon rich molecular layer not stained in DeArmond Fig. 80 (pg. 160) ? (8-14).
4. The **Purkinje cell** is easily identified by its large dendritic tree in tissue prepared by the Golgi method (Nolte, Fig. 20-10). Recall that the Golgi method colors only a few selected neurons in a given section and colors those neurons in their entirety, i.e., the cell body, axon and dendritic processes.
5. Although the cerebellar cortex receives highly varied inputs from diverse sources and has both ascending and descending projections, the cellular organization of the cerebellar cortex is remarkably uniform. Throughout the cerebellar cortex, two fiber types provide input: *mossy fibers* (of widely varied origin) synapse with cerebellar granule cells and Golgi cell interneurons; *climbing fibers* (which originate in the contralateral inferior olive) synapse directly on Purkinje cells. What is the origin of the parallel fibers? (8-15).

6. Whereas mossy fibers convey sensory and motor command information to the cerebellum, the climbing fibers are believed to be important in conveying movement errors and in inducing long lasting changes in cerebellar synapses, resulting in motor learning.

## Blood Supply to the Central Core

---

Now that you are familiar with functions of the major structures within the core of the cerebrum, it is a good time to review the vascular supply of these areas. With the aid of DeArmond (Fig. 99, pg. 187, Fig. 101, pg. 189, and Fig. 103, pg. 190) recall that:

1. The **medial striate artery** is a very small artery that branches off the *anterior cerebral artery* just rostral to the formation of the anterior communicating artery (unfortunately it is not labeled in DeArmond or Nolte - but can be seen in Nolte, Fig. 6-6, just rostral to the ACoA). Branches of the medial striate artery supply the rostromedial aspects of the *caudate*, *lenticular nucleus*, & *anterior limb of the internal capsule*. Recall that the *corpus striatum* consists of the caudate and lenticular nuclei: hence the name *striate* artery.
2. The **lateral striate arteries** (called the lenticulostriate arteries in DeArmond, Fig. 103 and LsA in Nolte, Fig. 6-6) are derived from the *middle cerebral artery* and supply much of the *caudate*, *lenticular nucleus* & *internal capsule*.
3. The **anterior choroidal arteries** (AchA in Nolte, Fig. 6-6) are derived from the *internal carotid arteries* and supply the *posterior limb of the internal capsule*, *part of the amygdala*, *core of the parahippocampal gyrus*, & *tail of the caudate* as well as the *choroid plexus of the temporal horn of the lateral ventricle*.
4. The **posterior communicating arteries** (DeArmond, Fig. 99, pg. 187) also are derived from the *internal carotid arteries* and supplies small branches to the *diencephalon*.
5. The **posterior choroidal arteries** (DeArmond, Fig. 101, pg. 189) branch off from the posterior cerebral arteries. Recall that the posterior cerebral arteries are usually derived from the *basilar artery*. The posterior choroidal artery supplies the *diencephalon* & *midbrain tectum* as well as the *choroid plexus of the lateral & third ventricles*.

**TABLE 8-I. MAJOR CONNECTIONS OF THE MAIN THALAMIC NUCLEI**

NOTE: In addition to the major inputs to thalamic nuclei listed in the following table, as a general rule, thalamic nuclei receive inputs from the cortical areas to which they project (reciprocal connections).

Nucleus	Major Input	Major Output	General Function
Major Sensory			
Ventral Posterolateral	Medial lemniscus Spinothalamic tract	Postcentral Gyrus (Somatosensory cortex)	Somatosensory (bodyneck)
Ventral Posteromedial	Trigeminothalamic tracts Solitary nucleus	Postcentral Gyrus (Somatosensory cortex)	Somatosensory (dura-face) Gustatory
Medial Geniculate Body	Brachium of the inferior colliculus	Superior temporal gyrus (Auditory cortex)	Audition
Lateral Geniculate Body	Optic tract	Calcarine cortex of Occipital lobe (Visual cortex)	Vision
Ventral Posterior Inferior	Lateral lemniscus MLF	Parietal lobe Temporal lobe	Balance Equilibrium
Major Motor			
Ventral anterior	Substantia nigra Globus pallidus	Premotor cortex Supplementary motor area Primary motor cortex	Motor
Ventral lateral	Substantia nigra Globus pallidus Deep nuclei of cerebellum	Premotor cortex Supplementary motor area Primary motor cortex	Motor
Association			
Lateral Posterior	Superior colliculus Thalamic nuclei	Parietal lobe	Sensory integration
Pulvinar	Retina Superior colliculus	Parietal lobe Post. temporal cortex Occipital lobe	Sensory integration (speech, vision)
Lateral Dorsal	Cingulate gyrus	Cingulate gyrus	Emotion
Dorsomedial	Amygdala Olfactory cortex Hypothalamus	Prefrontal cortex	Limbic
Non-Specific and Other Relay			
Centromedian	Reticular formation Spinal cord Globus pallidus (internal)	Caudate Putamen Diffuse cortical areas	Motor
Thalamic Reticular	Cerebral cortex	Thalamus Midbrain tegmentum	Integrate intrathalamic activity
Anterior	Mammillothalamic tract Fornix	Cingulate gyrus	Recent memory Emotion

**TABLE 8-II. MAJOR CONNECTIONS OF THE BASAL GANGLIA**

<b>Nucleus</b>	<b>Major Input</b>	<b>Major Output</b>
Caudate	Cerebral Cortex (Assoc. areas) CM Thalamus Substantia nigra	Globus Pallidus Substantia Nigra
Putamen	Cerebral Cortex (Sens. & Motor) CM Thalamus Substantia Nigra	Globus Pallidus Substantia Nigra
Globus Pallidus	Caudate Putamen Subthalamic Nucleus	VA, VL, CM Thalamus Subthalamic Nucleus
Subthalamic Nucleus	Globus Pallidus	Globus Pallidus
Substantia Nigra	Putamen Caudate Globus Pallidus Subthalamic Nucleus	Putamen Caudate VA VL Thalamus Reticular Formation Superior Colliculus

## Answers

---

- 8-1. Nonfluent, productive, motor, or expressive aphasia
- 8-2. Small lesions can affect motor and/or sensory functions on the entire contralateral body & face
- 8-3. Lateral striate (also called lenticulostriate) branches of the middle cerebral artery
- 8-4. Olfactory
- 8-5. Somatosensory
- 8-6. Visual
- 8-7. VA, VL, CM
- 8-8. VA
- 8-9. Globus pallidus
- 8-10. Caudate & putamen
- 8-11. VA, VL
- 8-12. Pontine
- 8-13. The inferior & middle cerebellar peduncles
- 8-14. Axons of the granular cells, i.e., the parallel fibers, are unmyelinated
- 8-15. The granule cells of the cerebellar cortex
- 8-16. Head of caudate
- 8-17. Genu limb of internal capsule
- 8-18. Putamen
- 8-19. Posterior limb of the internal capsule
- 8-20. Column of fornix
- 8-21. Splenium of corpus callosum
- 8-22. Temporal horn of the lateral ventricle
- 8-23. Frontal horn of the lateral ventricle
- 8-24. Septum pellucidum
- 8-25. Anterior limb of the internal capsule

## Laboratory Exercise #9: Descending Pathways to the Spinal Cord

Lecturer: Michael Beauchamp, Ph.D. and Nachum Dafny, Ph.D..

March 27, 2012 1:00 PM

### Required Reading

---

- Nolte, Chapter 10, Spinal Cord
- Nolte, Chapter 18, Overview of motor systems (review)

### Introduction

---

As you learned in Exercise 8, the basal ganglia, cerebellum, and thalamus play a major role in motor function. However, of these motor structures, only the deep cerebellar nuclei (fastigial and interposed nuclei) send axons directly to spinal cord. The remainder of these motor structures exert their primary influence on the cerebral cortex and on certain brainstem nuclei which, in turn, send their axons to interneurons or to motor neurons in the spinal cord and brainstem. In this lab we will consider the descending pathways that exert a more direct influence on the activity of spinal cord motor neurons. At the end of this exercise, you should be able to:

1. Identify the major descending tracts of the spinal cord.
2. Identify the locations of the cells of origin (cortical or brainstem nuclei) of the descending tracts.
3. Describe the important connections of the cells of origin of these descending tracts.
4. Describe the influence of these descending tracts on motor activity.

- **Part A**

#### **Examination Of Wet Human Brain Material**

1. Your row's human specimens
2. Demonstration material presented by teaching assistants

- **Part B**

#### **Complete Exercise Mode Of Laboratory #9 Of Neurolab**

1. Each student should go through the NeuroLab computer program review mode prior to the laboratory.

- **Part C**

#### **An Exercise At The End Of The Laboratory (~3:30 P.M.) To Assess Your Learning Progress**

- **Part D**

#### **Post-Laboratory Review Using Clinical Cases**

## Materials

---

You will be attempting to trace fiber tracts in brain and spinal cord sections stained for myelin. Often the tracts travel in close proximity and cannot be distinguished from one another or from other nearby tracts. DO NOT PANIC if you cannot find the EXACT location of the tract in question. Learn its position relative to other more easily recognized structures. Use the outlines in the drawings of DeArmond to help you find the tracts.

Figures from DeArmond # 32, 34, 35, 36, 37, 40, 44, 47, 48, 52, 54, 55, 65, 68.

- Brain specimen bucket containing
  - Brain stem
  - Spinal Cord
- Aluminum pan
- Squeeze bottles with water or bleach
- Cleanup towels for any dripping or spillage

### *You need to bring:*

- Gloves
- Dissection kit
- You may want to bring an plastic apron to protect your clothes.

## Wet Specimens

---

Be able to identify the names, positions, connections, and functions of the indicated structures. While you should concentrate primarily on learning the location of the motor structures BE SURE to review other, non-motor structures. They will help orient you to the anterior-posterior (i.e., rostral-caudal) level of the section. As in other Laboratory Exercises the text in boxes is required review material that should be studied before or after this Exercise. You may find Table 9-1 helpful in learning the origins, terminations and functions of the descending tracts.

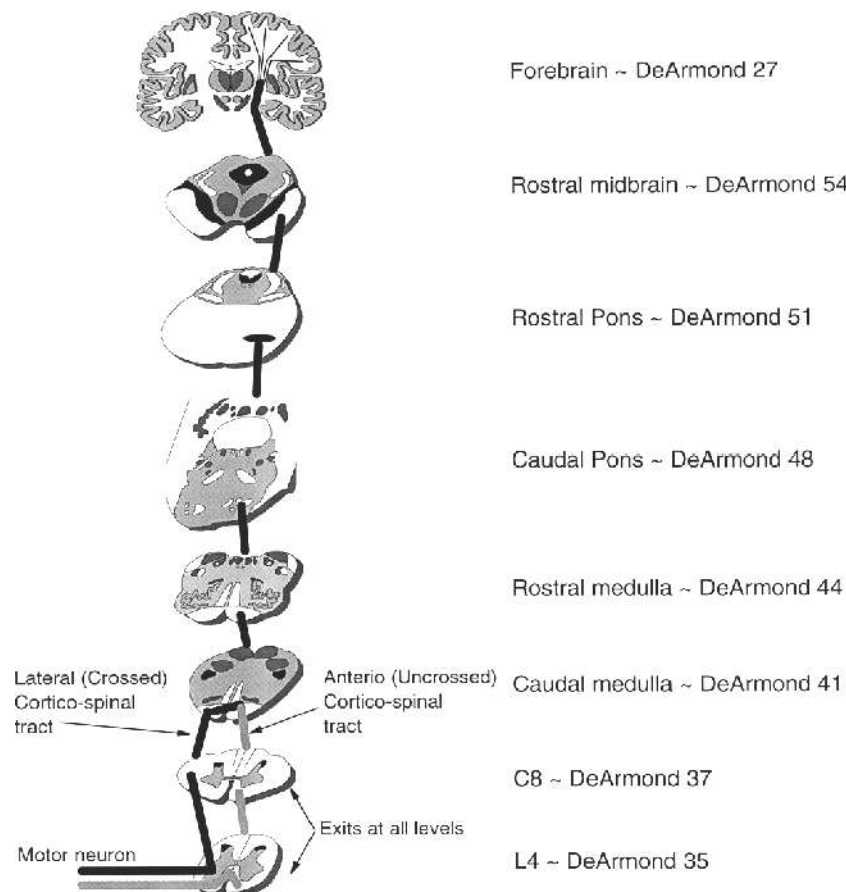
## Descending Pathways

---

- A. Using the SPINAL CORD SPECIMEN from your row's bucket:
  - i. Identify the anterior (ventral) root that contain the axons of alpha motor neurons
  - ii. Identify the posterolateral sulcus and the anterolateral sulcus.
  - iii. Identify the anterior funiculus. What descending pathways course through the anterior funiculus?
  - iv. Identify the lateral funiculus. What descending pathways course through the lateral funiculus?
- B. Using the BRAIN STEM specimen from your row's bucket:
  - i. Identify the pyramidal decussation. What descending tract crosses here? What level of the brain stem is this?
  - ii. Identify the pyramids. What descending tract courses through here? What level of the brain stem is this?
  - iii. Identify the crus cerebri (cerebral peduncles). What descending tract courses through

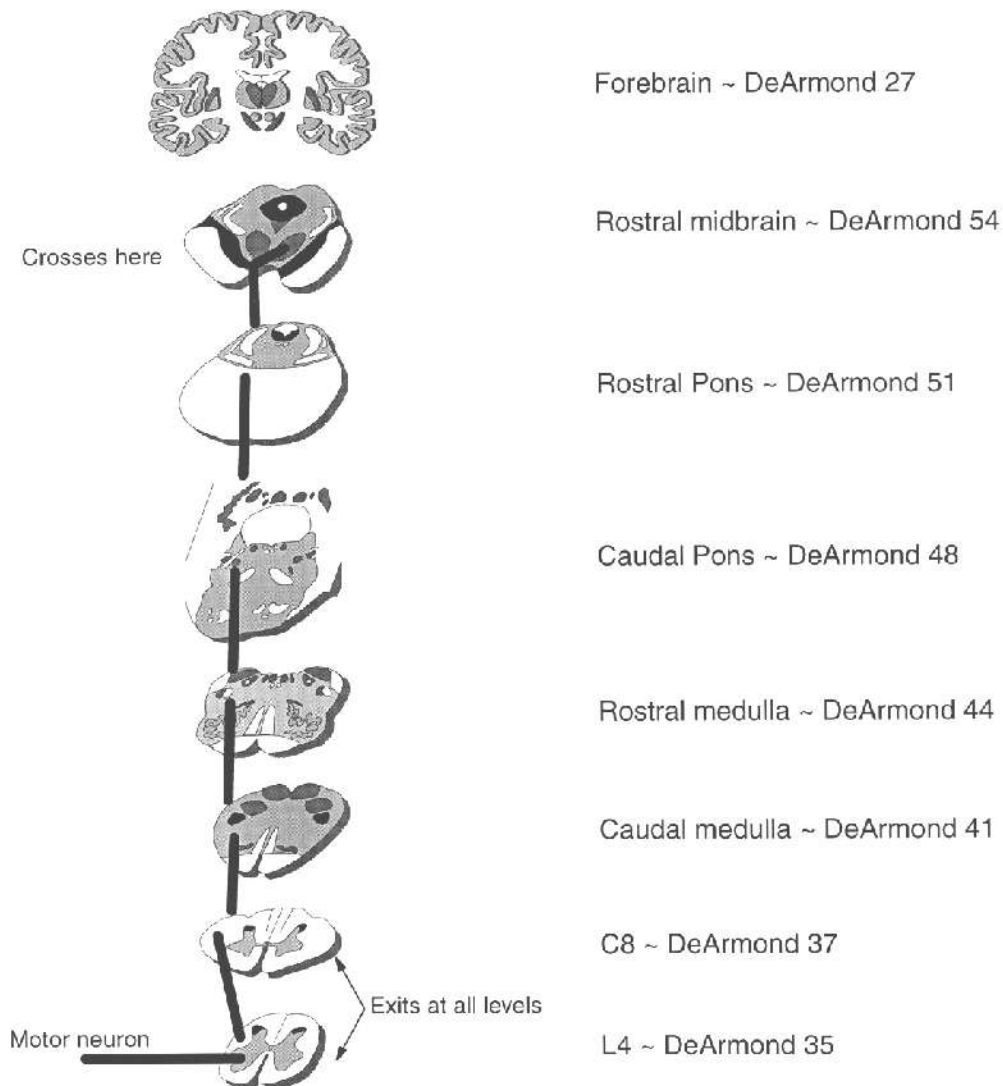
- here? What level of the brain stem is this?
- iv. Identify the red nucleus. What descending tract originates here? What level of the brain stem is this?
  - v. Identify the superior colliculi. What descending tract originates here? What level of the brain stem is this?

**CLINICAL DISORDERS OF THE DESCENDING SPINAL PATHWAYS:** In cerebral monoplegia, following recovery from lesions in the precentral gyrus, the patient suffers from a spastic monoplegia (a paresis of a limb or a part of it), with increased myotatic reflexes and appearance of pathological reflexes (e.g., the sign of Babinski, extensor response to plantar stimulus, if the motor cortex representing the leg region is damaged). The limb is kept in an extended position and some voluntary movement reappears. In lesions affecting the lower extremity, the patients are able to stand and walk, although their steps are small and hampered by the existing spasticity. In the case of damage to the precentral gyrus area representing the upper limb, the recovery of voluntary movement is often insufficient to allow the patient to grasp objects and use them properly.



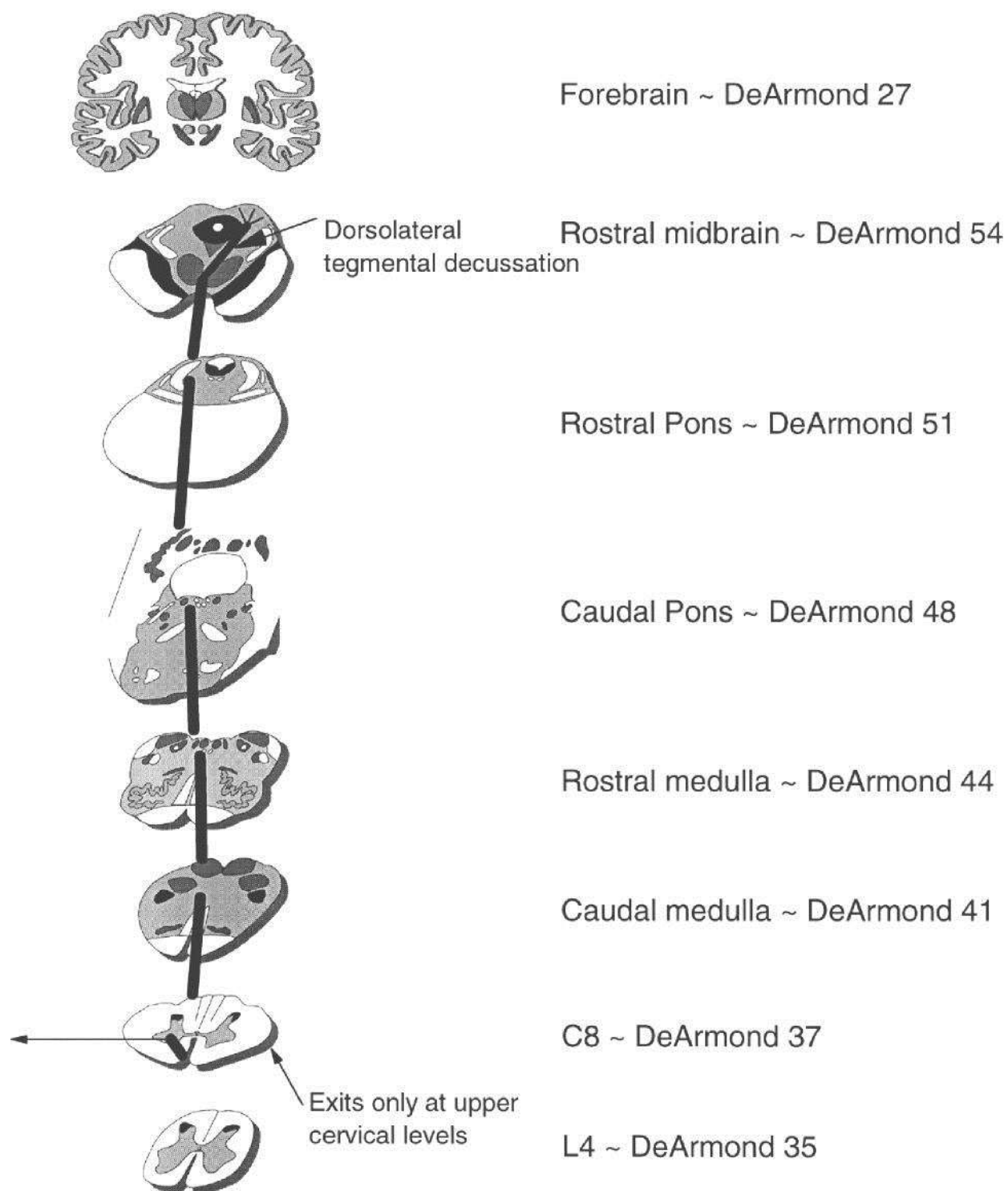
*Figure 9.1 Corticospinal Pathways The axons of cerebral cortex neurons descend to the spinal cord, where they synapse on anterior horn interneurons (predominantly) or motor neurons. It is the axons of the anterior horn motor neurons (the lower motor neuron) that leave the spinal cord to innervate skeletal muscles of the body.*

**CLINICAL DISORDERS OF DESCENDING SPINAL PATHWAYS:** Some cells of the red nucleus receive fibers from the precentral gyrus of the cerebral cortex and send fibers in the rubrospinal tract to the spinal cord. Thus, the corticorubral and rubrospinal tracts constitute a non-corticospinal pathway from the motor cortex to the spinal cord. It has been suggested that this path might be involved in coordinating discrete voluntary movement of the limbs and digits. There have been a few cases of circumscribed lesions in the red nucleus without involvement of surrounding midbrain structures. These patients were described to have some degree of contralateral hemiparesis, occasionally with somewhat exaggerated tendon reflexes and weakened abdominal reflexes.



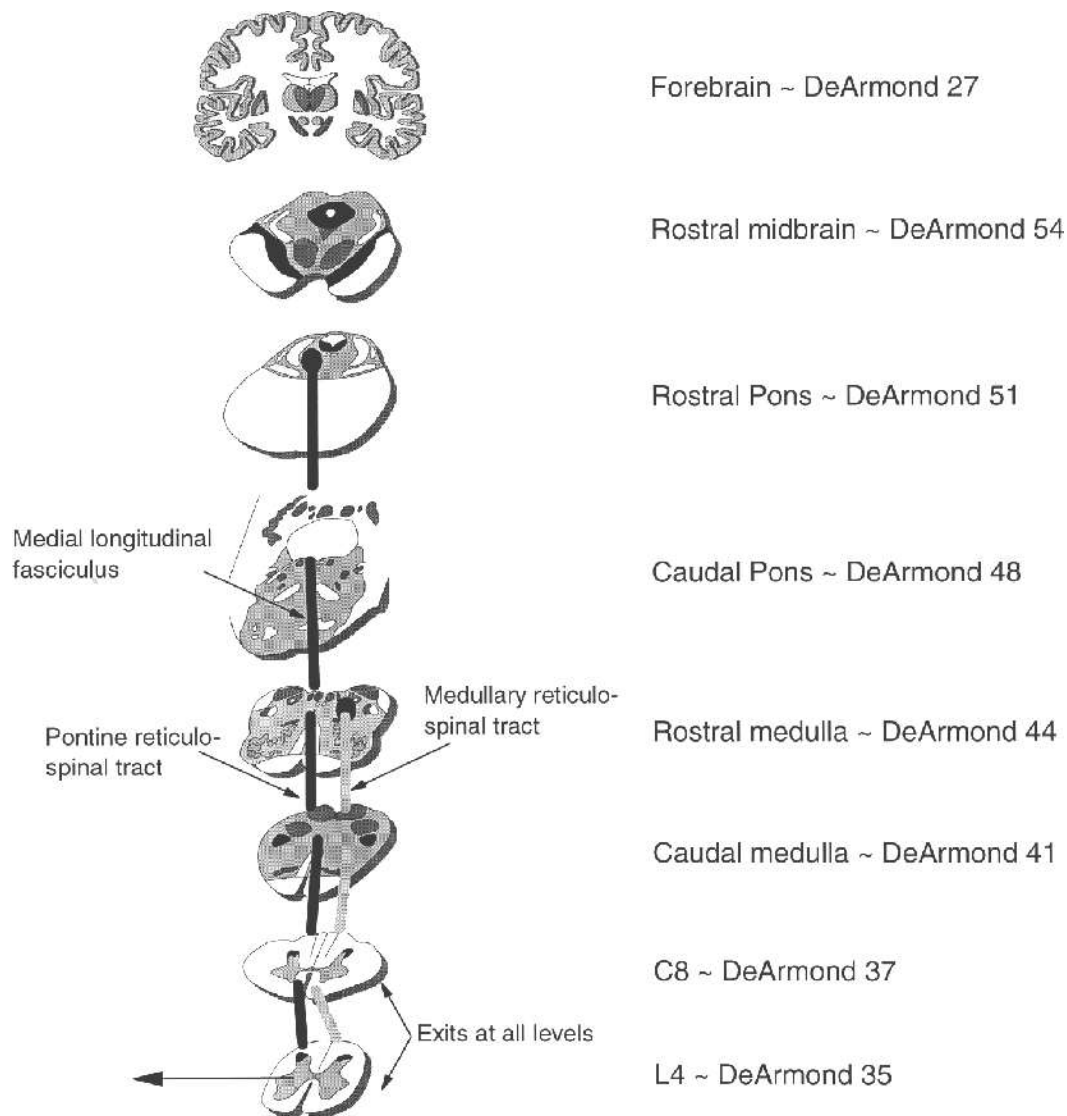
*Figure 9.2 Rubrospinal Pathway Many axons from the red nucleus descend to the spinal cord, where they terminate predominantly at cervical levels. The rubrospinal tract axons end in the lateral part of the anterior horn, where they influence motor neurons controlling the muscles of the arms and hands.*





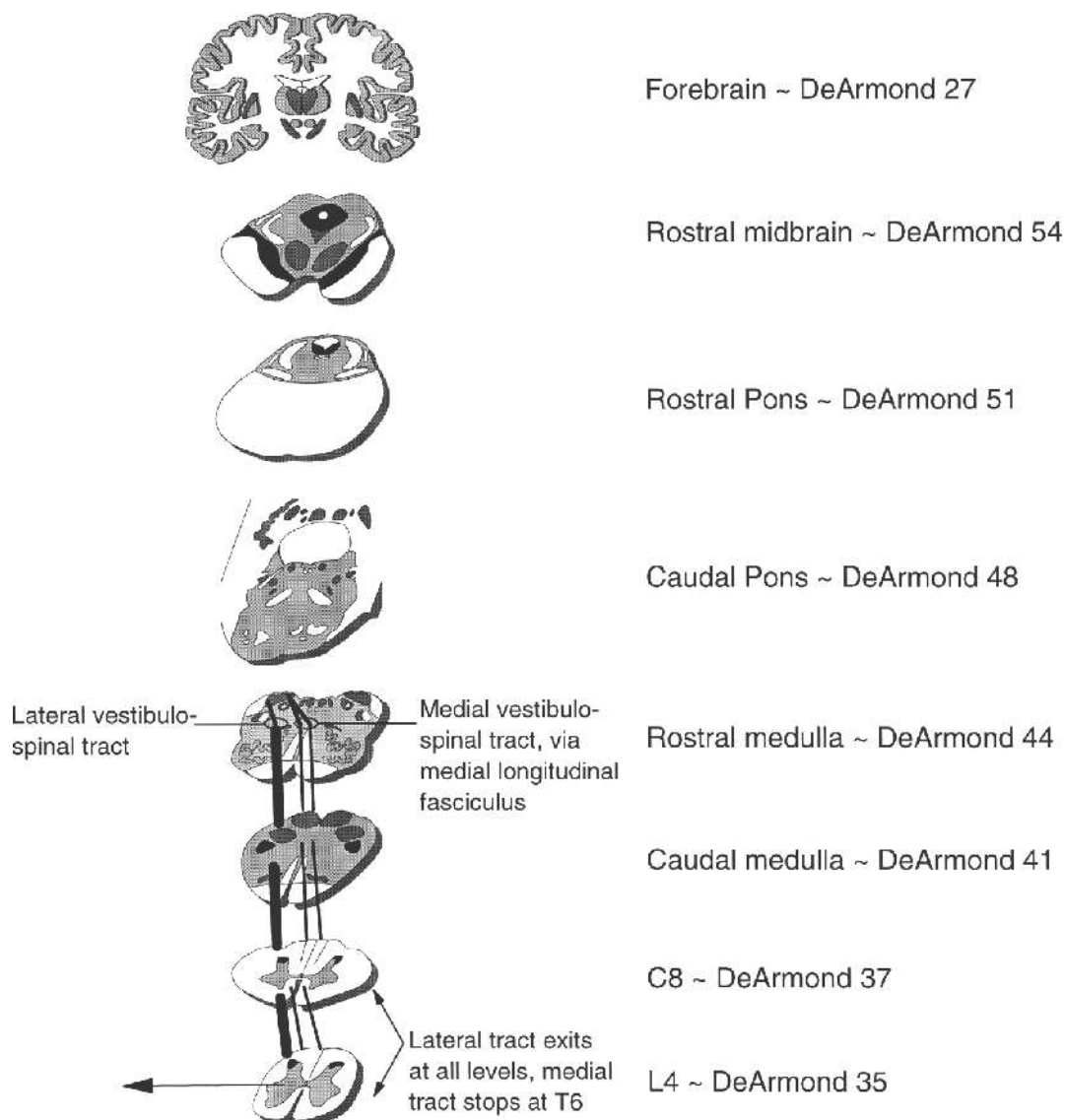
*Figure 9.3 Tectospinal Pathway*

**CLINICAL DISORDERS OF DESCENDING SPINAL PATHWAYS:** Bilateral destruction of the reticulospinal pathways results in autonomic as well as skeletal motor disorders. If the damage is above the level of spinal cord segments C3 C4, death will follow because of destruction of reticular fibers to the motor cells giving rise to the fibers of the phrenic nerve which normally control respiration. If the lesion is lower and the patient survives, other autonomic signs, involving sweating and vasomotor responses, will appear.



*Figure 9.4 Pontine and Medullary Reticulospinal Pathways*

**CLINICAL DISORDERS OF DESCENDING SPINAL PATHWAYS:** When the spinal cord is hemisected, the Brown Sequard syndrome results. Following recovery from a high cervical lesion (e.g., C4), this syndrome is characterized by a spastic hemiplegia of the ipsilateral arm, forearm and leg, with a Babinski sign (extensor response to plantar stimulus) and abolished abdominal reflexes, exaggerated patellar and Achilles reflexes (lateral corticospinal & non-corticospinal descending pathways), loss of discriminative touch and proprioception on the ipsilateral side (posterior funiculus), and loss of pain and temperature sensibility on approximately the same region of the contralateral side of the body (spinothalamic tract). The ipsilateral pupil is constricted and there is a bilateral diminution of sweating (descending reticulospinal tract to preganglionic sympathetics). The functions of the bladder, rectum, and genital organs are usually not interfered with because they are bilaterally innervated.



*Figure 9.5 Vestibulospinal Pathways*

**TABLE 9-I: Ascending & Descending Tracts in the Spinal Cord****SC = spinal cord; X = cross; UNX = uncross**

<b>Tracts</b>	<b>X/Unx</b>	<b>N 0</b>	<b>Cells Of Origin</b>	<b>Principal Termination</b>	<b>Functions</b>
Ascending Tracts					
<b>Posterior Funiculus</b>					
Fasciculus Gracilis	UNX	10	Post. Root Gang.: S5-T7	Nucleus Gracilis	Dis. Touch & Proprioception
Fasciculus Cuneatus	UNX	10	Post. Root Gang.: T6-C2	Nucleus Cuneatus	Dis. Touch & Proprioception
Cuneocerebellar	UNX	10	Post. Root Gang.: C8-C2	Lateral Cuneate Nucleus	Uncon. Proprioception - Ind. Muscle Gps.
Lateral Funiculus					
Posterior Spinocerebellar	UNX	20	Dorsal Nucleus Clarke: L3-C8	Cerebellum	Uncon. Proprioception - Ind. Muscle Gps.
Anterior Spinocerebellar	X in SC	20	Spinal Border Cells: L5-L1	Cerebellum	Uncon. Proprioception - Whole Limbs
Neospinothalamic	X in SC	20	Nucleus Postero-Marginalis	VPL Thalamus	Sharp Pain
Paleospinothalamic	UNX and-X in SC	30	Nucleus Proprius	Intralaminar Nuclei of Thalamus	Dull Pain Temperature Simple Touch Affective Touch
<b>Anterior Funiculus</b>					
Neospinothalamic	X in SC	20	Nucleus Postero-Marginalis	VPL Thalamus	Sharp Pain
Paleospinothalamic	UNX-X in SC	30	Nucleus Proprius	Intralaminar nuclei of thalamus	Dull Pain Temperature Simple Touch Affective Touch
Descending Tracts					
<b>Lateral Funiculus</b>					
Lateral Corticospinal	X in medulla	-	Cerebral Cortex	Spinal Cord: All	Volitional, Skilled Extremities
Rubrospinal	X in midbrain	-	Red Nucleus	Spinal cord: C-T & l-s	Volitional: Exite Flexors & Inhi. Extensors
<b>Anterior Funiculus</b>					
Medial Vestibulospinal	UNX-x in BS	-	Medial Vestibular Nucleus	Spinal cord: C1-T6	Excite Ipsi, Inhibit Contra Neck and Back Mn's
Lateral Vestibulospinal	UNX	-	Lateral Vestibular Nucleus	Spinal cord: All	Excite Limb Extensors; Inhibit Limb Flexors
Medullary Reticulospinal	UNX-x	-	Medullary Reticular Formation	Spinal Cord: All	Inhibit Vol. & Reflex; Muscle Tone
Pontine Reticulospinal	UNX	-	Pontine Reticular Formation	Spinal Cord: All	Facilitate Vol. & Reflexes; Muscle Tone
Tectospinal	X in BS	-	Superior Colliculus	Spinal Cord: C1-C4	Head Turning Reflex to Sound & Light
Anterior Corticospinal	UNX - X in SC	-	Cerebral Cortex	Spinal cord: C1-L3	Volitional: Skilled; Axial & extremities

# Laboratory Exercise #10:

## Cranial Nerve Nuclei and Brainstem Circulation

Lecturer: Terry Crow, Ph.D.

April 10, 2012 1:00 PM

### Required Reading

---

- Nolte, Chapter 12, The Cranial Nerves and Their Nuclei
- Nolte, Chapter 18, Overview of Motor Systems, pp. 466-472 for corticofugal inputs
- Nolte, Chapter 11, Organization of the Brainstem, pp. 289-292 for blood supply

### Introduction

---

In this lab exercise, you will study the brainstem cranial nerve nuclei and review the blood supply of the brainstem. By learning how to assess the function of the brainstem nuclei you will preview exercises that are essential to Physical Diagnosis. You will also review the blood supply to specific regions of the brain stem and learn of three syndromes that result from occlusion of these vessels. References are provided for related DeArmond figures and Brainiac P-W (PW) Sections.

By the end of the exercise, you should be able to:

1. Identify nuclei of cranial nerves XII, XI, X, IX, VIII, VII, VI, V, IV, and III
2. Describe the clinical testing of these nuclei
3. Describe whether the cortical influence on cranial motor nuclei is bilateral or crossed, and the clinical signs of upper versus lower motor neuron damage
4. Describe the blood supply to specific regions of the brain stem and the symptoms that result from occlusion of the blood vessels.

- **Part A**  
**Examination Of Wet Human Brain Material**
  1. Your row's human specimens
  2. Demonstration material presented by teaching assistants
- **Part B**  
**Complete Exercise Mode Of Laboratory #10 Of Neurolab**
  1. Each student should go through the NeuroLab computer program review mode prior to the laboratory.
- **Part C**  
**An Exercise At The End Of The Laboratory (~3:30 P.M.) To Assess Your Learning Progress**
- **Part D**  
**Post-Laboratory Review Using Clinical Cases**

## Materials

---

- Brain specimen bucket
- Aluminum pan
- Squeeze bottles with water or bleach
- Cleanup towels for any dripping or spillage

### *You need to bring:*

- Gloves
- Dissection kit
- You may want to bring an plastic apron to protect your clothes.

## Instructions

---

As in previous exercises, you should learn to identify the names, locations, connections, and functions of the structures. The material presented in boxes need not be covered during the laboratory period, but may be included in the laboratory exam.

Identify the following on the gross brain:

- Attachments of cranial nerves IX, X, XI, XII, VIII, VII, VI, V, IV, III
- Superior and Inferior Colliculi
- Vertebral Arteries
- Posterior Inferior Cerebellar Arteries
- Basilar Artery
- Pontine Paramedian Arteries
- Short and Long Circumferential Arteries
- Anterior Interior Cerebellar Arteries
- Superior Cerebellar Arteries
- Posterior Cerebral Arteries
- Anterior Spinal Artery
- Posterior Spinal Arteries

## Review Of Corticofugal Fibers

---

(Nolte, Fig. 18-18, pg. 471)

The corticofugal fibers projecting from the cerebral cortex to the brain stem are referred to as corticotectal (midbrain), corticopontine (pons) and corticobulbar (medulla) fibers. These fibers arise, primarily, from the precentral (motor) cortex of the frontal lobe and postcentral (somatosensory) gyri of the parietal lobe and are distributed to: sensory nuclei, parts of the reticular formation, and certain cranial motor nuclei. Corticofugal fibers control the responses of cranial sensory nuclei (e.g., the nucleus gracilis and cuneatus, the sensory trigeminal nuclei, and nucleus solitarius) as well as the responses of cranial motor nuclei. Reticular formation neurons receiving corticofugal fibers send their axons to cranial nerve nuclei, the cerebellum, and the spinal cord. The reticular formation neurons sending fibers to the cranial nerve nuclei may be considered analogous to the internuncials of the spinal cord that connect corticospinal fibers to anterior horn motor neurons.

Be aware that most cranial motor nucleus neurons are homologous to the alpha motor neurons of the spinal cord. That is, they are lower motor neurons that innervate the striated muscles of the face, eyes and ears. The exceptions are autonomic (preganglionic parasympathetic) neurons of the dorsal vagal motor nucleus and the inferior & superior salivatory nuclei. These preganglionic parasympathetic neurons terminate in autonomic ganglia located in or near the body viscera.

Cranial motor nuclei innervating striated muscles receive corticofugal input either directly or indirectly, by way of the reticular formation (See footnotes for Table 10-1). The cortical influence on oculomotor, trochlear and abducens nuclei is unique and was covered previously in the Vision laboratory exercise. Most other cranial motor neurons are influenced directly or indirectly (via the reticular formation) by the right and left cerebral cortex, unlike spinal cord motor neurons that are influenced predominantly by the contralateral cortex. The cranial motor neurons receiving a predominantly contralateral corticofugal input are those innervating the lower face (i.e., facial nucleus neurons, see Nolte, pg. 314), the jaw (trigeminal motor neurons) and the tongue (hypoglossal neurons). Note that these motor neurons are important in controlling the muscles involved in speech.

Remember that damage to the lower motor neuron (whether in the nerve or nucleus of origin) results in areflexia, flaccid paralysis, and ultimately in atrophy of the muscles normally innervated. Upper motor neuron lesions usually result in loss of volitional control of the muscle groups, as well as paresis and disorders of muscle tone and reflexes.



## Cranial Nerve XI - Spinal Accessory Nerve

Components of the Spinal Accessory Nerve: Axons from the spinal accessory nucleus travel in the spinal accessory nerve to end in part of the trapezius and sternocleidomastoid muscles. Fibers from the nucleus ambiguus (see below) travel in the spinal accessory nerve within the skull, join the vagus nerve outside the skull, and end in the intrinsic muscles of the larynx.

The axons of the spinal accessory nucleus exit the brain stem laterally and pass with the glossopharyngeal and vagal cranial nerves through the jugular foramen of the skull. Their axons end in the trapezius and sternocleidomastoid muscles. What kinds of movements do these muscles generate? (10-1).

Destruction of the spinal accessory nerve produces weakness in rotating the head against resistance toward the side opposite the lesion and atrophy of the sternocleidomastoid. The patient cannot shrug the affected shoulder and exhibits a mild drooping of the affected shoulder with the scapula displaced downward.

The cortical input to the spinal accessory nucleus is bilateral and direct for volitional control of head rotation. Interruptions of the corticobulbar fibers (upper motor neuron lesions) produce very mild symptoms that are difficult to recognize unless the fibers are injured bilaterally. Diseases of the corpus striatum may result in torticollis, a repeated involuntary movement of the head toward the normal side.

### **Clinical Exam Of Cranial Nerve XI**

- Ask to shrug shoulders (trapezius): place both hands on patient's trapezius muscles above shoulders, and ask patient to shrug against resistance.
- Ask to turn head against force (sternocleidomastoid): place hands against patient's jaw and ask patient to turn head against resistance of hand. Perform procedure on both the right and left sides.

## Cranial Nerve XII - Hypoglossal Nerve

---

**Components of the Hypoglossal Nerve:** This nerve is considered to contain only motor fibers innervating the muscles of the tongue.

The hypoglossal nucleus contains the cell bodies of the axons that innervate the tongue musculature. Damage to the hypoglossal motor neurons results in a flaccid paralysis and atrophy of the ipsilateral tongue and in the deviation of the tongue towards the side of the lesion during protrusion of the tongue (paralysis of the genioglossus muscle).

The somatosensory systems of the face area (i.e., the trigeminal sensory nuclei) provide direct and indirect (via the reticular formation) input to the hypoglossal nucleus which mediate reflex tongue movements in response to stimuli from lingual, oral and pharyngeal mucous membranes.

The cortical input to the hypoglossal nucleus is bilateral with a slight contralateral dominance and both direct and indirect. Bilateral damage to the corticobulbar tracts results in motor defects called the pseudobulbar palsy syndrome. Voluntary movements of the tongue are greatly impaired and speech is quite dysarthric. Muscle atrophy does not usually occur and this serves to differentiate the type of paralysis and aids in localizing the lesion. Other types of cranial motor disorders that appear in the pseudobulbar palsy syndrome depend upon the level of involvement of the corticofugal fibers. Damage to the basal ganglia may cause involuntary, irregular movements of the tongue.

### **Clinical Exam Of Cranial Nerve XII**

- Stick out tongue
- Move tongue side to side

## Cranial Nerve X - Vagal Nerve - Dorsal Vagal - Motor Nucleus Component

Components of the Vagus Nerve: (1) The parasympathetic (preganglionic) fibers from the dorsal vagal motor nucleus terminate in parasympathetic ganglia located near the thoracic and abdominal viscera. (2) Motor fibers of the nucleus ambiguus (see below) travel in the vagus nerve to innervate the muscles of the palate, pharynx & larynx. (3) Viscerosensory fibers innervate the pharynx, larynx, trachea, esophagus, and thoracic & abdominal viscera and end in the nucleus solitarius.

(4) Somatosensory fibers innervate the outer ear canal, part of the ear (pinna), and dura and end in the spinal trigeminal nucleus. (5) Chemosensory fibers innervate taste buds in the epiglottis and end in the rostral (gustatory) component of the nucleus solitarius.

The dorsal vagal motor neurons are visceral efferents and their axons are distributed (as preganglionic parasympathetic fibers) to autonomic ganglion cells located in or near the viscera of the thorax and abdomen. (The descending colon and pelvic viscera receive comparable innervation from the sacral parasympathetic fibers). The autonomic ganglia of the thorax and abdomen innervate involuntary musculature, the pancreas, liver, and glands. Activation of the dorsal vagal nucleus inhibits heart rate and suprarenal secretion and stimulates gastrointestinal peristalsis, gastric & hepatic glands and the pancreas.

Bilateral destruction of the dorsal vagal motor neurons will produce paralysis and atonia (loss of muscle tone) of the esophagus and stomach which result in pain and vomiting. The loss of inhibitory influences, which results from destruction of these neurons, will cause the heart rate to become rapid and irregular. The dorsal vagal motor nucleus receives short connecting fibers from the nucleus solitarius and from interneurons. These provide input from afferents innervating the cardiovascular, pulmonary and digestive systems which initiate automatic responses affecting blood pressure, blood gas levels, etc.

The cortical input to the dorsal vagal motor nucleus is bilateral and indirect. Bilateral damage to corticobulbar fibers result in vasomotor changes and may produce changes in secretory and motor functions of the stomach.

What three sensory pathways are associated with the vagus nerve? \_\_\_\_\_, \_\_\_\_\_, & \_\_\_\_\_ (10-2). Why would section of the vagus nerve result in the loss of the cough reflex? \_\_\_\_\_ (10-3). Why would section of the vagus nerve result in the loss of the carotid sinus reflex which normally regulates arterial blood pressure? \_\_\_\_\_ (10-4).

### **Clinical Exam Of Dorsal Vagal Component Of Cranial Nerve X**

- Oculocardiac Reflex: Press over orbit to produce cardiac slowing
- Carotid Sinus Reflex: Press on carotid sinus to produce cardiac slowing

## Cranial Nerves XI, X & IX - Nucleus Ambiguus Fibers

---

**Distribution of Nucleus Ambiguus Fibers:** The axons of the nucleus ambiguus innervate the muscles of the palate, larynx and pharynx via three cranial nerves: (1) Axons from the caudal pole of the nucleus ambiguus emerge from the lateral surface of the medulla caudal to the lowest filaments of the vagus nerve to join the accessory (XI) nerve. These cranial accessory fibers later join the vagus nerve and innervate the intrinsic muscles of the larynx. (2) The axons of the mid-portion of the nucleus ambiguus join the vagus (X) nerve. (3) The axons of the most rostral portion of the nucleus ambiguus contribute fibers to the glossopharyngeal (IX) nerve.

Unilateral damage to the lower motor (nucleus ambiguus) neurons produces an ipsilateral paralysis of the palate, pharynx and larynx. Speech disorders, hoarseness, dyspnea (shortness of breath) and dysphagia (difficulty in swallowing) occur. Bilateral lesions may result in death due to the complete paralysis of the larynx (i.e., inability to abduct the vocal cords during inspiration).

The nucleus ambiguus receives short connecting fibers from the neighboring cranial sensory nuclei, i.e., the spinal trigeminal nucleus and nucleus solitarius. These fibers complete reflex arcs controlling swallowing, coughing, vomiting and control laryngeal motor output.

The cortical input to the nucleus ambiguus is bilateral and indirect. Unilateral damage of the corticobulbar tract produces mild forms of weakness. Bilateral lesions produce a weakness or absence of the ability to speak, swallow and breathe. What three cranial nerves carry the fibers of the nucleus ambiguus?\_\_\_\_\_, \_\_\_\_\_, & \_\_\_\_\_ (10-5). The vagus nerve contains motor (efferent) fibers that are involved in what types of motor function? \_\_\_\_\_ & \_\_\_\_\_ (10-6).

## Glossopharyngeal Nerve: Parasympathetic Efferents

Components of the Glossopharyngeal Nerve: (1) The parasympathetic (preganglionic) fibers from the inferior salivatory nucleus terminate in a parasympathetic (otic) ganglion located near the parotid gland. (2) Motor fibers of the nucleus ambiguus (see above box) travel in the glossopharyngeal nerve to innervate the stylopharyngeus muscle. (3) Viscerosensory fibers innervate the carotid sinus & body, pharynx, soft palate, tonsils, and Eustachian tube and end in the nucleus solitarius. (4) Somatosensory fibers innervate the outer ear canal, eardrum, and middle ear and end in the spinal trigeminal nucleus. (5) Chemosensory fibers innervate taste buds in the posterior third of the tongue and the pharynx and end in the rostral (gustatory) component of the nucleus solitaries.

The axons of the inferior salivatory nucleus travel in the glossopharyngeal (IX) nerve as parasympathetic efferents and synapse in the otic ganglion. The postganglionic axons of the otic ganglion innervate the parotid gland. Damage to the lower motor neurons results in the impairment of salivary production. These autonomic efferents receive inputs from the solitary nucleus and from the spinal trigeminal nucleus for completion of cranial reflex arcs underlying salivary secretion, and from the hypothalamus (“the diencephalic visceral center”) and cerebral cortex for effecting salivation in response to emotional and cognitive stimuli.

Why would lesions of the glossopharyngeal nerve result in loss of the pharyngeal (gag) reflex? \_\_\_\_\_ (10-7). And the carotid sinus reflex? \_\_\_\_\_ (10-8). Would any sensory losses occur? \_\_\_\_\_ & \_\_\_\_\_ (10-9).

### **Clinical Exam Of Cranial Nerves IX & X**

- Ask to say “ahhh” to check uvula elevation - Cranial nerve X (motor)
- Ask to say “ahhh” to check constriction of posterior pharyngeal wall - Cranial nerve IX (motor)
- Stroke left or right pharynx to elicit “gag” reflex - Cranial nerve IX (viscerosensory) & Cranial X (motor)
- Check for taste on posterior tongue - Cranial nerve IX (chemosensory)
- Press over carotid sinus to elicit reflex slowing of heart and drop in blood pressure - Cranial nerve IX (viscerosensory) & Cranial X (motor)

## Cranial Nerves VII, IX & X – Gustatory Component

The rostral portion of the nucleus solitarius receives the terminals of gustatory afferent fibers of the vagus, glossopharyngeal and facial nerves. The gustatory fibers of the vagus (X) nerve innervate taste buds in the epiglottis and ascend in the solitary tract to end in the rostral (gustatory) portion of nucleus solitarius. The gustatory fibers of the glossopharyngeal (IX) nerve innervate taste buds in the posterior third of the tongue and the pharynx and ascend in the solitary tract to end in the gustatory portion of nucleus solitarius. The gustatory fibers of the facial (VII) nerve innervate taste buds in the anterior two-thirds of the tongue and the palate and end in the gustatory portion of nucleus solitarius.

### **Clinical Exam Of Gustatory Sensations In Cranial Nerve VII & IX**

- Rarely tested: Test anterior tongue for sweet with sugar water, sour with citric acid, and salty with saline. Test posterior tongue for bitter with a quinine solution.

## Cranial Nerve VIII - Vestibulocochlear Nerve

The auditory (cochlear) nerve fibers of the vestibulocochlear (VIII) nerve end in the cochlear nuclear complex. The auditory nerve fibers innervate the receptor cells in the cochlea. Damage to the auditory nerve results in deafness in the normally innervated ear.

The vestibular nerve fibers of the vestibulocochlear (VIII) nerve end in the vestibular nuclear complex. The vestibular nerve fibers innervate the receptor cells in the semicircular canal cristae and the maculae of the utricle and saccule. Unilateral damage of a vestibular nerve results in severe symptoms of vertigo, nystagmus, and visceromotor responses such as nausea, vomiting, and tachycardia - all of which diminish with time.

### **Clinical Exam Of Cranial Nerve VIII**

- Test gross hearing: Speak softly into one ear canal while blocking the other by pressing inward on the tragus. Hide mouth to prevent lip reading, and whisper words like "park, or dark" in the unblocked ear, and ask patient to repeat word. Repeat procedure in opposite ear.
- Caloric test: Irrigate ear with cold or warm water and observe eye movements. Not done routinely in conscious patients because of severe visceromotor responses

## Cranial Nerve VII - Facial Nerve

Components of the Facial (Cranial VII) Nerve: (1) The fibers of the facial motor nucleus form the large facial motor root and innervate the facial muscles. (2) The somatosensory afferent fibers innervating the pinna (that end in trigeminal nuclei), (3) the gustatory afferent fibers innervating the tongue and palate (that end in solitary nucleus) and (4) the visceral efferent fibers from the superior salivatory nucleus (that end in autonomic ganglia) constitute the smaller nervus intermedius root of the facial nerve.

The facial motor nucleus consists of the cells of origin for the brachial motor component of the facial nerve. The fibers innervate the superficial skeletal muscles of the face and scalp (mimetic musculature), the platysma, the stylohyoid, the posterior belly of the digastric muscle and the stapedius muscle of the middle ear. Lesion of the facial motor neurons will result in a complete facial paralysis of the muscles normally innervated. Ipsilateral to the site of lesion, the mouth droops and the patient cannot whistle, wink or close the eye or wrinkle the forehead.

The facial motor nucleus receives inputs from the spinal trigeminal nucleus, which mediate the corneal blink and other trigeminofacial reflexes. A branch of the facial nerve innervates the stapedius muscle of the middle ear that controls middle ear sound transmission. The facial motor neurons innervating the stapedius receive auditory information from the superior olivary complex. Corticofugal fibers exert direct and indirect influence bilaterally on cell groups innervating upper facial muscles and predominantly contralaterally on cell groups innervating the lower face. Unilateral lesions of corticofugal fibers produce a marked weakness of muscles in the lower half of the face contralaterally (especially in the mouth region) while muscles of the upper facial region concerned with wrinkling the forehead, frowning and closing the eyes are not affected. Even in the presence of this type of voluntary facial paralysis, the muscles in the lower face will contract symmetrically while smiling or laughing in response to a genuine emotional stimulus.

Since there are two different types of supranuclear facial paresis, one concerned with voluntary facial movement and another involving involuntary, emotional facial expression, there are at least two different pathways involved in controlling the facial muscles. Portions of the basal ganglia and the thalamus may be involved in the supranuclear control of emotional facial expression, but the actual pathways mediating these emotional influences are unknown.

Parasympathetic fibers of the superior salivatory nucleus travel in the nervus intermedius of the facial (VII) nerve and end in autonomic ganglia. In turn, these ganglia innervate the lachrymal glands, and the submandibular and submaxillary salivary glands. Damage to these autonomic efferents impairs salivary and lachrymal (tear) secretions. Inputs from the trigeminal sensory nuclei initiate reflex tearing in response to irritation of the eye. Inputs from the solitary nucleus and spinal trigeminal nucleus cause increased salivation from stimulation of the oral cavity. Bilateral corticofugal and hypothalamic inputs cause lacrimation and salivation in response to emotional and cognitive stimuli.

### **Clinical Exam Of Cranial Nerve VII**

- Ask patient to raise eyebrows and wrinkle forehead. Test eye opening strength: Ask patient to close eyes as tight as they can and you try to open them.
- Ask patient to show teeth, smile or frown, or puff out cheeks against resistance while observing for symmetry.
- Test for gustatory sensation

See section above on the gustatory afferents of the solitary nucleus.



## Cranial Nerve VI - Abducens Nerve

**Components of the Abducens Nerve:** The abducens (VI) nerve is motor in function and innervates the lateral rectus muscle of the eye.

The abducens nucleus lies within the caudal third of the pons in the facial colliculus. It contains both motor neurons and interneurons. The axons of its motor neurons form the abducens nerve and innervate the lateral rectus muscle of the eye. When the eye is directed straight ahead, contraction of the lateral rectus results in the external rotation or abduction of the eye. When the eye is elevated or depressed above or below the horizon, contraction of the lateral rectus will further elevate or depress the globe. The abducens interneurons send control signals to contralateral oculomotor neurons (via the medial longitudinal fasciculus) which control the medial rectus.

Lesions of the abducens nerve result in a paralysis of the ipsilateral lateral rectus muscle and double vision (diplopia). The affected eye is strongly adducted by the unopposed medial rectus muscle resulting in an internal strabismus. Recall that the abducens nucleus interneurons receive input from the pontine paramedian reticular formation (PPRF) and relay cortical influences that control conjugate horizontal eye movements. Consequently, damage to the abducens nucleus results in an inability to direct either eye towards the side of the lesion (lateral gaze paralysis).

The abducens nucleus receives inputs from vestibular nuclei via the medial longitudinal fasciculus and from the midbrain via the reticular formation, as well as internuclear inputs from the trochlear and oculomotor nuclei. The vestibular inputs are concerned with vestibular control of horizontal eye movements (i.e., vestibulo-ocular and smooth pursuit). Midbrain supranuclear inputs are involved in the control of voluntary and reflex lateral eye movements. The internuclear fibers from the other extraocular motor nuclei are involved in coordinating eye muscle action that enable conjugate and converging eye movements.

Cortical influences on abducens neurons are indirect and mediated by midbrain and pontine structures. Following a vascular accident, which damages the corticofugal fibers in the internal capsule, there may be a transient inability to look toward the side opposite the lesion on command (voluntary saccades), although reflex movements are well preserved.

### **Clinical Exam Of Cranial Nerve (III, IV, VI): Extraocular Movements**

- Ask to look horizontally to right
- Ask to look horizontally to left
- Ask to look vertically up and down
- Assess tracking response: Hold patient's chin steady and ask patient to follow finger with their eyes, as examiner traces an "H" pattern about one meter from the patient's eye. From the middle, move finger about a foot to the right and pause; up and pause; down and pause; back to the midline; then cross midline and repeat sequence on the opposite side.
- Assess convergence response: Ask patient to look first at a distant point ahead, then at a target about five inches in front of the patient's nose.

## Cranial Nerve V - Trigeminal Nerve

Components of the Trigeminal Nerve: (1) The trigeminal nerve fibers carrying crude touch, pain and temperature information from the face form the spinal trigeminal tract and terminate in the spinal trigeminal nucleus. The spinal trigeminal nucleus is replaced at this level of the pons by the main sensory trigeminal nucleus. (2) Trigeminal nerve fibers that carry information about discriminative touch and proprioception from the face end on the cells in the main sensory trigeminal nucleus. (3) The neurons of the mesencephalic trigeminal nucleus are the cells of origin (first-order) of trigeminal nerve afferents innervating the jaw muscles and joints. They are concerned with proprioceptive sensibility of the jaw only and are involved in the controlling the force of bite. (4) The axons of the trigeminal motor nucleus exit at the lateral margin of the pons. The axons form the bulk of the mandibular division of the trigeminal nerve.

The trigeminal motor nucleus provides motor innervation to the muscles of mastication, the tensor tympani and the tensor veli palatini. Damage to the trigeminal motor neurons results in paralysis of the masticatory muscles. The force of bite is reduced in power, and the jaw deviates toward the injured side on opening the mouth. With bilateral damage, the lower jaw droops, but the mouth can be closed by means of the facial muscles. However, chewing is impossible and swallowing is difficult.

Among the inputs to the trigeminal motor nucleus are the collaterals from the mesencephalic trigeminal nucleus for reflex control of jaw muscles. Additional inputs from the other sensory trigeminal nuclei provide reflex control of jaw muscles to superficial stimuli, especially from the lingual and oral mucus membranes.

The corticofugal input to the trigeminal motor nucleus is both direct and indirect via the reticular formation and bilateral with a slight contralateral dominance. Central or upper motor neuron lesions lead to little disturbances unless they are bilateral, as in pseudobulbar palsy. In this disease, cerebral vascular disorders produce areas of necrosis, which interrupt the corticobulbar fibers. Volitional movements of the jaw are impaired and the jaw jerk reflex is usually increased.

The somatosensory components of the trigeminal nerve (facial skin, eyes, oral & nasal cavities & dura) and those of the vagus (outer ear canal, pinna, & dura), glossopharyngeal (outer ear canal, ear drum, & middle ear cavity) and facial (pinna) nerves end in the spinal trigeminal nucleus (crude touch, pain and temperature) and main sensory trigeminal nucleus (discriminative touch). The axons of the mesencephalic trigeminal nucleus travel in the trigeminal nerve to innervate and provide proprioceptive information from the jaw muscles and joints.

### **Clinical Exam Of Cranial Nerve (V)**

- Assess light touch sensitivity: Ask patient to respond when the examiner touches their skin with a piece of cotton/gauze on both sides of the forehead, followed by both sides of the cheeks, followed by both sides of the jaw. Ask patient if the sensation is the same on each side.
- Test muscles of mastication (temporal/masseter): Ask patient to bite down or clench teeth while the masseter or temporalis muscles are felt bilaterally.

## Cranial Nerve IV - Trochlear Nerve

---

**Components of the Trochlear Nerve:** The trochlear (IV) nerve is entirely motor and innervates the superior oblique muscle of the eye.

The trochlear nucleus axons pass posteriorly, decussate and exit the brain stem just caudal to the inferior colliculus. This is the only cranial nerve to leave the posterior aspect of the brain. They innervate the superior oblique muscle of the eye. Contraction of this muscle serves to intort the eye (roll the eye nasally) when abducted and depress the eye when adducted.

Damage to the trochlear motor neuron results in disorders that are difficult to detect. Patients may complain of vertical diplopia (double image) when walking down stairs or reading (attempted downward gaze) and may exhibit a slight convergent strabismus (abnormal position of the eye when attempting to gaze straight ahead).

The trochlear nucleus, like the other extraocular motor nuclei, receives inputs from a number of sources. Conjugate movements of the eye may be induced volitionally or reflexively in response to visual, vestibular or auditory stimuli. The extraocular motor nuclei receive (1) input from the other extraocular motor nuclei to coordinate muscle action; (2) indirect, supranuclear input from the frontal lobe for volitional saccades and from the parieto-temporal cortical areas for smooth pursuit; (3) input from vestibular centers for movement in response to alterations in head posture; and (4) input from midbrain centers for movement in response to sudden lights and sounds.

Disturbances in voluntary conjugate eye movements result from lesions interrupting the internal capsule. Impairment of voluntary eye movements may be accompanied by exaggerated fixation reflex. The patient may have difficulty in diverting his gaze from the object on which he is focusing. See section on Abducens Nerve for clinical tests.

## Cranial Nerve III - Oculomotor Nerve

Components of the Oculomotor Nerve: (1) The somatic motor component of the oculomotor nerve innervates the levator palpebrae, the superior, medial and inferior recti, and the inferior oblique muscle. (2) The parasympathetic component of the oculomotor nerve consists of preganglionic parasympathetic efferents (Edinger-Westphal fibers) which terminate within the ciliary ganglion. It is the postganglionic fibers of the ciliary ganglion that form the short ciliary nerve and innervate the sphincter muscle of the iris and the ciliary muscles of the eye.

The somatic motor component of the oculomotor nucleus is associated with the elevation of the eyelid (levator palpebrae), vertical eye movements, converging eye movements, and also participates in conjugate horizontal eye movements. The parasympathetic - Edinger-Westphal nucleus - component controls the constriction of the pupil by contraction of the sphincter muscle of the iris and the lens curvature by contraction of the ciliary muscles during accommodation.

Damage to the lower motor neurons will result in paralysis of the muscles involved. The eyelid droops (ptosis) and the eye is deviated laterally (external strabismus) following damage of the oculomotor somatic component. Following damage of the parasympathetic (Edinger-Westphal or ciliary ganglion) neurons: the pupil is fully dilated (mydriasis), the pupillary light reflex is abolished and lens accommodation (near vision) is lost.

The nuclei of the oculomotor complex receive fibers from the vestibular nuclei, reticular formation, and from other extraocular motor nuclei. To coordinate muscle action in horizontal gaze, the interneurons of the abducens nucleus send axons via the medial longitudinal fasciculus to the oculomotor neurons controlling the medial rectus muscle. The vestibular input also travels via the medial longitudinal fasciculus to the extraocular motor nuclei for reflex adjustments of eye position to accommodate for changes in head position. Intercalated neurons of the reticular formation relay corticofugal inputs for control of reflex and volitional eye movements and for adjustments of eye muscles to focus on objects. The superior colliculi, which are involved in controlling eye movements, appear to influence extraocular motor nuclei indirectly via cell groups located in the periaqueductal gray and reticular formation. The superior colliculus controls vertical tracking eye movements to visual and acoustic stimuli. Damage to corticofugal fibers in the internal capsule may result in impairments of conjugate eye movements. The impairment, however, is often temporary.

### **Clinical Exam Of Cranial Nerve (III)**

- See section on Abducens Nerve for extraocular muscle testing.
- Test pupillary (parasympathetic) response (direct): Ask patient to look in the distance while shining a bright light (usually from penlight) in patient's eye. The light should come in from the side, no more than six inches from the face, using the patient's nose as a barrier to light reaching the other eye. The examiner should observe the response of the pupil. Then repeat the test on the other eye.
- Test pupillary (parasympathetic) response (consensual): As above, but the examiner should observe the response of the pupil that does not have light shining on it.

## Clinical Symptoms Resulting From Damage To Blood Supply

---

Using Figure 10-1 and Nolte, Fig. 11-30 (pg. 292), review the following relationships between arteries and the regions supplied by the arteries that cause vascular syndromes of the brainstem. These are listed here in order of frequency and are described below. See also Nolte, page 320, for figures and descriptions of these syndromes.

### **Medial Medullary (Alternating Hypoglossal Hemiplegia) Syndrome**

Branches of the anterior spinal artery supply medial regions of the medulla. Occlusion of these branches or the anterior spinal artery produces the medial medullary or alternating hypoglossal hemiplegia syndrome. The deficits include a loss of discriminative touch and proprioception on the entire contralateral body area, a contralateral hemiplegia with positive Babinski sign, and paralysis of the ipsilateral half of the tongue. The structures involved include the medial lemniscus, the pyramids, and the hypoglossal nerve root. Notice that one symptom is on the side ipsilateral to the infarct (paralysis of the tongue with hypoglossal nerve loss) and that the other symptoms are on the contralateral side (corticospinal and medial lemniscus loss). The involvement of the hypoglossal nerve helps localize the site of damage.

### **Lateral Medullary Or Wallenberg's Syndrome**

Branches of the posterior inferior cerebellar artery (PICA) supply lateral regions of the medulla. Occlusion of the PICA produces the lateral medullary (or Wallenberg's) syndrome that is the most commonly occurring of the brainstem syndromes. Depending on the level of occlusion the deficits may include a loss of pain and temperature sensation on the entire contralateral body area; a loss of pain and temperature sensation on the ipsilateral face area; difficulty in swallowing and phonation; ipsilateral hearing deficit, nystagmus, nausea, ataxia toward the side of the lesion; and ipsilateral ptosis & miosis (Horner's syndrome) and decreased sweating. The structures involved include the spinothalamic tract, spinal trigeminal nucleus & tract, nucleus ambiguus, cochlear nuclei, vestibular nuclei, inferior cerebellar peduncle, & autonomic fibers descending through the area of the lesion. Horner's syndrome (ptosis, i.e., drooping of the upper eyelid; miosis, i.e., chronic pupil constriction; and decreased sweating) results from the interruption of fibers from the reticular formation or hypothalamus that normally descend to the thoracic spinal cord where they terminate on preganglionic sympathetic neurons in the lateral horn. The preganglionic axons exit the spinal cord and terminate in the superior cervical ganglion that sends its axons to the head. Depending on the speed and severity of the vascular insult, all or some of the symptoms may be transient or permanent.

### **Pontine Vascular Syndromes**

There are a series of syndromes that result from thrombosis of the small vessels that supply the pons. These syndromes occur in many different combinations. Interruption of the blood supply to the anteromedial region of the pons through the paramedian branches of the basilar artery causes ipsilateral flaccid paralysis of the lateral rectus muscle, internal strabismus and inability to deviate the eye laterally because of involvement of rootlets of the abducens nerve that are passing through medial areas of the basilar pons. There might also be a contralateral hemiplegia of the upper and lower extremities, hyper-reflexia, and Babinski sign from the involvement of the corticospinal fibers in the basilar pons. Notice that the one component of the paralysis is on the side ipsilateral to the infarct (abducens loss) and that the other component is on the contralateral side (corticospinal loss), which helps localize the lesion. If the medial lemniscus were involved, there would be loss of discriminative touch and proprioception from the contralateral body.

The short circumferential branches of the basilar artery supply the anterolateral regions of the pons, posterior to the distribution of the paramedian branches. The regions served by these short circumferential branches include the anterior edge of the pons tegmentum (i.e., the medial lemniscus, spinothalamic tract & facial nerve as it exits the brain stem). Interruption of this blood supply causes symptoms of flaccid paralysis and atrophy of the muscles of the ipsilateral face and loss of taste sensation from the anterior two thirds of the ipsilateral tongue from involvement of the facial nerve roots. The involvement of large parts of the middle cerebellar peduncle would result in some ataxia (loss of coordination occurring in the absence of paresis, rigidity, spasticity or involuntary movement) ipsilateral to the lesion.

The long circumferential branches of the basilar artery and superior cerebellar artery supply posterolateral regions of the pons, including the superior cerebellar peduncle, the entering trigeminal root fibers, the mesencephalic & main sensory trigeminal nuclei, the trigeminal motor nucleus, and the spinothalamic tract. Occlusion of these arteries would cause ipsilateral cerebellar signs (superior cerebellar peduncle); anesthesia of the ipsilateral face (entering trigeminal root fibers); paralysis and atrophy of the ipsilateral muscles of mastication (trigeminal motor nucleus & trigeminal root fibers); and loss of pain and temperature sensation from the contralateral body (spinothalamic tract). Injury to the trigeminal root would also interfere with the afferent limb of the corneal reflex. The cerebellar signs would include intentional tremor, ataxia, myoclonus (rapid contractions of a muscle or muscle group), decomposition of movement, hypotonia, hyporeflexia.

### **Midbrain Vascular Syndromes**

The paramedian branches of the basilar artery and proximal parts of the posterior cerebral artery supply the anteromedial regions of the midbrain base, including medial areas of the crus cerebri & substantia nigra; the exiting fibers of the oculomotor nerve and, in some cases, anterior areas of the red nucleus. The symptoms that result from occlusion of these vessels are often called Weber's syndrome and include a contralateral hemiplegia (or hemiparesis) of the extremities and Babinski's sign (corticospinal fibers in the crus cerebri); contralateral paresis (or paralysis) of facial expression on the contralateral lower face and deviation of the tongue to the contralateral side on protrusion (corticobulbar fibers to the facial motor nucleus and the hypoglossal nucleus); ipsilateral paralysis of most extraocular muscles, external strabismus, and ptosis of the eyelid, dilated pupil and absence of pupillary light reflex (oculomotor nerve roots). Why is the contralateral lower face affected and not the entire contralateral face? \_\_\_\_ (10-10). In which direction (ipsilateral or contralateral) with respect to a lesion of the hypoglossal nerve does the tongue deviate on protrusion? \_\_\_\_ (10-11). If there is involvement of the red nucleus and adjacent cerebellothalamic fibers of the superior cerebellar peduncle, there may also be contralateral cerebellar signs.

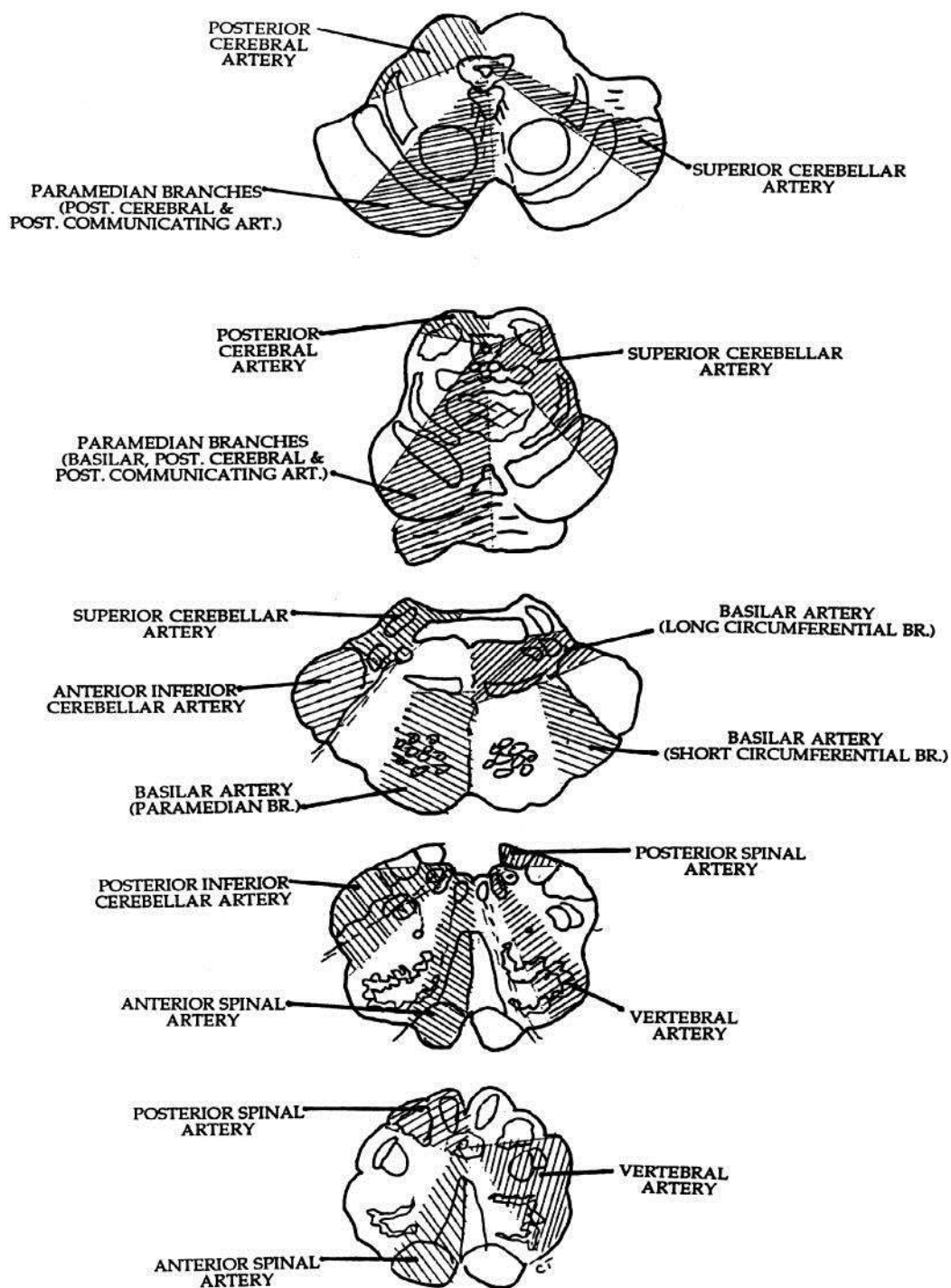


Figure 10-1. The arterial supply of the brain stem. Shaded areas show the approximate region supplied by the indicated vessels. (Adapted from M.B. Carpenter, "Core Text of Neuroanatomy", Williams & Wilkins, Baltimore).

**TABLE 10-I Level of Brain Stem Where Cranial Nerve Nuclei are Found**

<b>Level</b>	<b>Somatic Motor</b>	<b>Autonomic Parasympathetic</b>	<b>Somatosensory &amp; Viscerosensory</b>	<b>Special Senses</b>
Medulla	Hypoglossal* Nucleus Ambiguus	Dorsal Motor Of X Inferior Salivatory	Spinal Trigeminal Nucleus Solitarius	Nucleus Solitarius Vestibular (Inferior & Medial)
Pons	Facial Motor* Abducens Trigeminal Motor*	Superior Salivatory	Spinal Trigeminal Main Sensory Trigeminal	Vestibular (Lateral & Superior) Cochlear Nuclei
Midbrain	Trochlear Oculomotor	Edinger-Westphal	Mesencephalic Of V	

Corticofugal inputs\* to most Somatic Motor and Autonomic Cranial nerve nuclei are:

- bilateral
- indirect (e.g., They end in the reticular formation which, in turn, send axons to the cranial motor nuclei)

\* EXCEPT for corticofugal inputs to

- Hypoglossal nucleus (Tongue) Bilateral (slight contra dominance) & Direct + Indirect
- Facial motor nucleus for lower face Bilateral (contralateral dominance) & Direct + Indirect
- Trigeminal motor nucleus (Jaw) Bilateral (strong contra dominance) & Direct + Indirect

See Nolte, Fig. 18-18, pg. 471.



**TABLE 10-2 Functional Columns of Cranial Nerve Nuclei**  
*This is a brief summary of the general locations and functions of the cranial nerve nuclei.*

Nerve	Function	Structure Innervated	Cells Of Origin	Cns Termination	Normal Function	Clinical Tests	Abnormal Response
Olfactory (I)	Sensory: Smell	Olfactory Epithelium of The Nasal Cavity	Olfactory Receptor	Olfactory Bulb	Detect & Identify Odors	Apply Common Odors (Mint, Coffee) To One Nostril At A Time	Inability To Identify The Odors
Optic (II)	Sensory: Vision	Retina of Eye	Retinal Ganglion Cells	Lateral Geniculate Body Of Thalamus	Detect & Identify Light, Forms, Etc. Communication Via Written Language	Visual Acuity With Standard Eye Chart Visual Fields With A Confrontation Test Ophthalmoscopic Exam	Inability To Identify Letters Visual Field Deficits Abnormal Fundus
Oculomotor	Motor: Somatic Autonomic: Parasympath	Superior , Medial & Inferior Rectus: Inferior Oblique: & Levator Palpebrae Superior Muscles Ciliary Ganglion To Sphincter Pupillae & Ciliary Muscles	Oculomotor Nuclei Edinger-Westphal Nucleus		Eye Movements: Lateral, Downward, & Upward Gaze, Convergence Elevation Of Eyelid Pupillary Light Reflex & Accommodation	Have Patient Follow Your Finger With their Eyes While You Move It Ask Patient To Open Eye Flash Light In One Eye At A Time	Strabismus & Eyes Not Follow Finger, Diplopia (Double Vision) Ptosis (Eyelid Droops) Pupil Dilated. No Pupillary Reflex Or Accommodation
Trochlear	Motor: Somatic	Superior Oblique	Trochlear Nucleus		Downward & Lateral Gaze & Intort Eye	See Nerve III - Motor	Weakness Of Downward & Lateral Gaze
Trigeminal	Sensory: Somato-Sensory Sensory Afferent: Proprio Motor: Branchial	Skin & Mucous of Face & The Anterior Dura Jaw Joints & Jaw Muscles Muscles of Mastication, Tensors Tympani & Veli Palatini Mylohyoid, & Ant. Digastric Muscles	Semilunar Ganglion Mesencephalic Nucleus of V In Cns Motor Nucleus of V	Main Sensory Nucleus & Spinal Nucleus of V Main Sensory Nucleus of V?	Somatosensory of Face And Dura Position & Movement of Jaw Force of Bite, Jaw Movements, Middle Ear Reflex	Test Tactile & Pain Sensations of Face; Test Corneal Reflex Test Jaw Reflex Feel Masseter Muscles As Patient Bites Down Have Patient Open Mouth	Anesthesia In Area Normally Innervated No Eye Blink Reflex No Jaw Closure Unequal Contraction of The Masseters Jaw Deviates Towards The Damaged Side
Abducens	Motor: Somatic	Lateral Rectus Muscle	Abducens Nucleus		Lateral Gaze	See Nerve III - Motor	Eye Deviated Nasally Strabismus & Diplopia

TABLE 10-2 *Continued*

Nerve	Function	Structure Innervated	Cells Of Origin	Cns Termination	Normal Function	Clinical Tests	Abnormal Response
Facial (VII)	Sensory: Somato Sensory: Taste Motor: Branchial Autonomic: Parasymp.	External Ear Taste Buds of Anterior 2/3 of Tongue And Palate Facial Muscles, Stapedius, Stylohyoid & Posterior Digastric Muscles Pterygopalatine & Submandibular Ganglia To Lachrymal, Subling., Subman. & Other Minor Glands	Geniculate Ganglion Geniculate Ganglion Facial Motor Nucleus Superior Salivatory Nucleus	Main Sensory & Spinal Nucleus of V Solitary Nucleus, Rostral Part	Touch, Pain, Temp., Sense Taste On Anterior 2/3 of Tongue Facial Expression, Eye Closure; Middle Ear Reflex Lacrimation & Salivation	Test Tactile & Pain On External Ear Apply Sm. Amt. of Sugar or Salt on Ant. 2/3 of Tongue Ask Patient To Wrinkle Forehead, Close Eyes, & Open Mouth Touch Eye Citric Acid On Tongue	Decreased Sensitivity To Stimulation of Ear Unable To Identify The Substance Unable To Execute The Movements No Tearing Reflex Weak Salivatory Reflex
Vestibulo-Cochlear (VIII)	Sensory: Audition Sensory: Vestibular	Organ of Corti in Cochlea Cristae and Maculae	Spiral Ganglion Vestibular Ganglia	Cochlear Nuclear Complex Vestibular Nuclear Complex	Detect, Identify Sounds; Communicate Using Spoken Language Detect & Identify Head Movement & Tilt	Hearing Acuity in Audiometric Tests Bone Conduction Test Otoscope Exam Caloric Test	Elevated Air Threshold Elevated Bone Threshold Tympanic Membrane Discolored No Nystagmus to Warm & Cold Water
Glosso-pharyngeal (IX)	Sensory: Somato Sensory: Taste Sensory: Visceral Motor: Branchial Autonomic: Parasympath	External & Middle Ear Taste Buds of Posterior 1/3 of Tongue & Pharynx Pharynx. Tonsil, Carotid Body & Sinus Stylopharyngeus Muscle Otic Ganglion to Parotid Gland	Superior Ganglion of IX Petrosal Ganglion Petrosal Ganglion Nucleus Ambiguus Inferior Salivatory Nucleus	Main Sensory & Spinal Nuclei of V Solitary Nucleus Rostral Part Solitary Nucleus, Caudal Part	Cutaneous Sense From Ear Taste from Posterior 1/3 of Tongue Sensory: Pharynx Afferent: Carotid Sinus Voice & Swallowing Salivation	Test Tactile & Pain Sense from the Ear Apply Bitter-sour Stimuli to Posterior Tongue Touch Pharynx Test Carotid Sinus Reflex Ask Patients to Say "Ah" Usually Not Tested	Increased Threshold to Touch & Painful Stimuli Incorrect Identification of Bitter-sour Stimulus Absence of Gag Reflex No Cardiac Slowing Tachycardia in Some Cases Loss of Constriction of Posterior Pharyngeal Wall

**TABLE 10-2** *Continued*

<b>Nerve</b>	<b>Function</b>	<b>Structure Innervated</b>	<b>Cells Of Origin</b>	<b>Cns Termination</b>	<b>Normal Function</b>	<b>Clinical Tests</b>	<b>Abnormal Response</b>
Vagus (X)	Sensory: Somato Sensory: Taste Sensory: Visceral Motor: Branchial Autonomic: Parasympath	External Ear & Dura Taste Buds of Epiglottis Throat, Aortic Bodies & Thoracic & Abdominal Visceral Muscles of Soft Palate Pharynx & Larynx Parasympathetic Ganglia in Thorax & Abdomen	Superior Ganglion of X Inferior Ganglion of X Inferior Ganglion of X Nucleus Ambiguus Dorsal Vagal Motor Nucleus	Main Sensory & Spinal Nuclei of V Solitary Nucleus, Rostral Part Solitary Nucleus, Caudal Part	Cutaneous Sense to Ear Taste from Soft Palate, Pharynx, etc. Distention & Pain from Thoracic & Abdominal Viscera Voice, Swallowing, and Breathing Heart, Respiratory Passages & Upper GIT	Test Tactile or Pain Usually Not Tested Usually Not Tested Test Pharyngeal Reflex Laryngoscope Exam Check Voice & Swallowing Carotid Sinus Pressure	Elevated Threshold to Touch & Pain No Gag Reflex Paralysis of Soft Palate Dysphonia & Dysphasia Heart Rate Slows & Blood Pressure Drops
Accessory (XI)	Motor: Somatic Motor: Branchial	Sternocleidomastoid & Trapezius Muscles Larynx & Pharynx	Spinal Accessory Nucleus Nucleus Ambiguus		Elevate Shoulder & Rotate Head Voice & Swallowing (Minor Component)	Ask Patient to Shrug Shoulder & Turn Head Against Resistance Check Voice & Swallowing	Unable to Lift Shoulder Unable to Turn Head Dysphasia & Dysphasia (Minor)
Hypoglossal (XII)	Motor: Somatic	Extrinsic & Intrinsic Muscles of Tongue	Hypoglossal Nucleus		Tongue Movements	Ask Patient to Protrude Tongue Fully	Tongue Deviates Towards the Lesion

## Review Questions

---

- 10-12. The \_\_\_\_\_ carries the central processes of 1° vagal afferents to the solitary nucleus.
- 10-13. The central processes of the glossopharyngeal 1° taste afferents terminate in the \_\_\_\_\_ nucleus.
- 10-14. The medulla contains:
- A. vagal fibers
  - B. glossopharyngeal fibers
  - C. solitary nucleus
  - D. spinal trigeminal nucleus
  - E. main trigeminal sensory nucleus
- 10-15. Which cranial nerve exits the medulla at the preolivary sulcus?
- 10-16. The midbrain contains:
- A. the mesencephalic trigeminal nucleus & tract
  - B. the ventral trigeminal tract
  - C. spinal trigeminal tract
  - D. posterior spinocerebellar tract
  - E. main trigeminal sensory nucleus
- 10-17. Somatic afferent fibers descend in the spinal trigeminal tract from the:
- A. trochlear nerve
  - B. trigeminal, glossopharyngeal & hypoglossal nerves
  - C. hypoglossal, vagal, facial & trigeminal nerves
  - D. vagus, glossopharyngeal, & facial nerves
  - E. vagus, glossopharyngeal, facial & trigeminal nerves
- 10-18. Afferent axons are contained in which of the following nerves?
- A. facial (VII)
  - B. glossopharyngeal (IX)
  - C. vagus (X)
  - D. vestibulocochlear (VIII)
  - E. all of the above
- 10-19. The spinal trigeminal nucleus extends from the \_\_\_\_\_ to the \_\_\_\_\_.
- 10-20. The ventral trigeminal lemniscus contains axons arising from the \_\_\_\_\_ and terminating in the VPM (ventral posteromedial nuclei of the thalamus).
- 10-21. Name, in proper order, the major subdivisions of the midbrain from posterior to anterior and the most prominent components of each subdivision.
- 10-22. Are there comparable subdivisions of the pons in continuity with those of the midbrain?

10-23. The superior colliculi are part of:

- A. the auditory system
- B. the medulla
- C. the visual motor system
- D. the tectum

10-24. What is the facial colliculus?

## Answers

---

10-1. Head rotation, flexion & shoulder shrug

10-2. Viscerosensory (throat), gustatory (epiglottis) & somatosensory (external ear & dura)

10-3. Vagus somatic motor fibers innervate the pharynx and larynx which form the efferent limb of the cough reflex arch

10-4. It would destroy the vagal motor fibers that normally innervate the heart, thus removing the efferent limb of the reflex arch

10-5. Accessory (XI), vagal (X), & glossopharyngeal (IX)

10-6. Parasympathetic control of thoracic and abdominal viscera & somatic motor control of the muscles of the larynx & pharynx for swallowing & phonation

10-7. The glossopharyngeal nerve contains somatosensory afferents innervating the pharynx & section of the nerve would interfere with the afferent limb of the reflex arch

10-8. The glossopharyngeal nerve carries viscerosensory afferents innervating the carotid body and sinus

10-9. Gustatory from the posterior 1/3 of the tongue & pharynx and somatosensory from the outer ear, tympanic membrane & middle ear.

10-10. The corticobulbar input to the motor neurons innervating the lower face are predominantly contralateral while those to the motor neurons innervating the upper face are bilateral

10-11. Ipsilateral to the lesion 10-12. The solitary tract

10-13. The rostral part of the solitary nucleus

10-14. A, B, C, & D only

10-15. Hypoglossal (XII)

10-16. A & B

10-17. E

10-18. E

10-19. Upper cervical spinal cord to the trigeminal root entry at mid-pontine level.

10-20. Spinal & main trigeminal sensory nuclei

10-21. The tectum, consisting of the superior & inferior colliculi; the tegmentum, containing the red nucleus, midbrain reticular formation, substantia nigra; & the base, consisting of the crus cerebri

10-22. There is no real tectum; the tegmentum contains cranial nuclei and the pontine reticular formation; and the base consists of the corticofugal fibers, pontine nuclei and middle cerebellar peduncle

10-23. C & D

10-24. A bulge on the floor of the fourth ventricle in the pons formed by the abducens nucleus and facial nerve root passing rostral to this nucleus

## List Of Structures To Be Identified In This Exercise

---

### GROSS SPECIMEN

- Cranial Nerve attachments to the medulla
  - Glossopharyngeal (IX)
  - Vagus (X)
  - Spinal accessory (XI)
  - Hypoglossal (XII)
- Cranial Nerve attachments to the pons
  - Vestibulocochlear (VIII)
  - Facial (VII)
  - Abducens (VI)
  - Trigeminal (V)
- Cranial Nerve attachments to the midbrain
  - Trochlear (IV)
  - Oculomotor (III)

### IMPORTANT BLOOD VESSELS OF THE BRAINSTEM

- Anterior and posterior spinal arteries
- Vertebral arteries
- Posterior inferior cerebellar arteries
- Basilar artery
- Paramedian arteries
- Short and long circumferential arteries
- Anterior inferior cerebellar arteries
- Posterior cerebral arteries
- Superior cerebellar arteries

### REVIEW OF THE CORTICOFUGAL FIBERS

- Precentral (motor) cortex of the frontal lobe (source of fibers)
- Postcentral (somatosensory) gyri of the parietal lobe (source of fibers)
- Internal capsule (fibers from cortex to basal ganglia, diencephalon, brain stem & spinal cord)
- Cerebral peduncles (crus cerebri) of the midbrain
- Pyramids

### LOWER MEDULLA (DeArmond, Fig. 40, Pg. 80)

- Spinal trigeminal tract (Somatosensory axons of Cranial Nerves V, VII, IX & X)
- Spinal trigeminal nucleus (Somatosensory face)
- Spinal accessory nucleus (Cranial Nerve XI - cells of origin - motor)
- Corticobulbar tract (Motor control)

### MEDULLA AT SENSORY DECUSSATION (DeArmond, Fig. 41, Pg. 82)

- Spinal trigeminal tract (Somatosensory axons of Cranial Nerves V, VII, IX & X)
- Solitary tract (Viscero & chemosensory axons of Cranial Nerves IX and X)
- Solitary nucleus (Viscero-sensory & viscerosensory afferent at this level)

- Hypoglossal nucleus (Cranial Nerve XII - cells of origin - motor)
- Preolivary sulcus (landmark)
- Dorsal vagal motor nucleus (Cranial Nerve X - cells of origin - preganglionic parasympathetic)
- Postolivary sulcus (landmark)
- Corticobulbar tract (cortical control of medullary structures)

#### UPPER MEDULLA (DeArmond, Figs, 42-45, pp. 84-90)

- Hypoglossal nucleus (Cranial Nerve XII - cells of origin - motor)
- Hypoglossal trigone (landmark) the spinal trigeminal tract (Somatosensory axons of Cranial Nerves V, VII, IX & X)
- Solitary tract (Viscero & Chemosensory axons of Cranial Nerves IX and X)
- Solitary nucleus (Viscerosensory & viscerosensitive at this level)
- Hypoglossal nucleus (Cranial Nerve XII - cells of origin - motor)
- Preolivary sulcus (landmark)
- Dorsal vagal motor nucleus (Cranial Nerve X - cells of origin - preganglionic parasympathetic)
- Postolivary sulcus (landmark)
- Corticobulbar tract (Cortical control of medullary structures)
- Dorsal vagal motor nucleus (Cranial Nerve X - cells of origin - preganglionic parasympathetic)
- Vagal trigone (landmark)
- Medial & inferior vestibular nuclei (Cranial Nerve VIII enters near pons)
- Sulcus limitans (landmark)
- Lateral vestibulospinal tract (Motor control - body)
- Solitary tract (Viscero & Chemosensory axons of Cranial Nerves IX and X)
- Solitary nucleus (Viscerosensory & viscerosensitive at this level)
- Spinal trigeminal tract (Somatosensory axons of Cranial Nerves V, VII, IX & X)
- Spinal trigeminal nucleus (Somatosensory - face)
- Ventral trigeminal lemniscus (Somatosensory - face)
- Nucleus ambiguus (Cranial Nerves XI, X & IX - cells of origin - motor)
- Postolivary sulcus (landmark)
- Corticobulbar tract (Cortical control of medullary structures)
- RECALL: the branches of the posterior inferior cerebellar artery (PICA) supply lateral regions of the upper (open) medulla

#### MEDULLARY-PONTINE-JUNCTION (DeArmond, Fig. 45-47, Pp. 90-94)

- Medial longitudinal fasciculus (Motor control - body & extraocular muscles)
- Solitary tract (Viscero & Chemosensory axons of Cranial Nerves IX and X)
- Solitary nucleus (Viscero to Chemosensory area)
- Spinal trigeminal nucleus (Somatosensory - face)
- Spinal trigeminal tract (Somatosensory axons of Cranial Nerves V, VII, IX & X) Superior & lateral vestibular nuclei (Cranial Nerve VIII - vestibular branch ends here)
- Cochlear nuclear complex (Cranial Nerve VIII - cochlear branch ends here)
- Corticobulbar tract (Cortical control of medullary structures)
- Inferior salivatory nucleus (Cranial Nerve IX) preganglionic parasympathetics)
- Postolivary sulcus (landmark)

### CAUDAL PONS (DeArmond, Fig. 48, Pg. 96)

- Facial colliculus (landmark)
- Abducens nucleus (Cranial Nerve VI - cells of origin - motor)
- Facial motor nucleus (Cranial Nerve VII - cells of origin - motor)
- Facial nerve genu (Cranial Nerve VII - motor axons- face)
- Facial colliculus (landmark)
- Medial longitudinal fasciculus (Motor control - body & extraocular muscles)
- Lateral & superior vestibular nuclei (Vestibular branch of Nerve VIII ends here)
- Sulcus limitans (landmark)
- Spinal trigeminal tract (Somatosensory axons of Cranial Nerves V, VII, IX & X)
- Spinal trigeminal nucleus (Somatosensory - face)
- Facial nerve (Cranial Nerve VII)
- Pontine paramedian reticular formation (PPRF) - (Horizontal gaze center)
- Vestibulocochlear nerve (Cranial nerve VIII) root
- Corticobulbar fibers (Cortical control of pontine structures)
- Superior salivatory nucleus (Cranial Nerve VII - preganglionic parasympathetics)
- Solitary tract (Chemosensory axons of Cranial Nerves VII, IX & X)
- Nucleus solitarius (Gustatory - chemosensory - at this level)

### MID PONS (DeArmond, Fig. 49, Pg. 98)

- Trigeminal nerve root (Cranial Nerve V)
- Main sensory trigeminal nucleus (Somatosensory - Cranial Nerves V, VII, IX, & X)
- Mesencephalic trigeminal nucleus (Proprioception - jaw - Cranial Nerve V)
- Trigeminal motor nucleus (Cranial Nerve V - cells of origin - motor)
- Medial longitudinal fasciculus (Motor control - body & extraocular muscles)
- Corticobulbar tract (Cortical control of medullary structures)
- RECALL: the blood supply to the anteromedial region of the caudal pons is through the paramedian branches of the basilar artery
- RECALL: the short circumferential branches of the basilar artery supply the Anterolateral regions of the pons, posterior to the distribution of the paramedian branches
- RECALL: the long circumferential branches of the basilar and superior cerebellar arteries supply posterolateral regions of the pons, including the superior cerebellar peduncle, the entering trigeminal root fibers (rostral pons), the mesencephalic & main sensory trigeminal nuclei, the trigeminal motor nucleus (rostral pons), and spinothalamic tract

### CAUDAL MIDBRAIN (DeArmond, Fig. 52, Pp. 104)

- Trochlear nucleus (Cranial Nerve IV - motor)
- Medial longitudinal fasciculus (Motor control - body & extraocular muscles)
- Mesencephalic trigeminal nucleus (Cranial Nerve V - Proprioception - jaw)

### ROSTRAL MIDBRAIN (DeArmond, Fig. 54, Pg. 108)

- Oculomotor nucleus (Cranial Nerve III - motor - cells of origin)
- Edinger-Westphal nucleus (Cranial Nerve III - preganglionic parasympathetic)



- Medial longitudinal fasciculus (Motor control - body & extraocular muscles)
- Mesencephalic trigeminal nucleus (Cranial Nerve V - proprioception - jaw)
- RECALL: the penetrating branches of the basilar artery and the proximal parts of the posterior cerebral artery supply the anteromedial regions of the midbrain base, including the crus cerebri, medial areas of the substantia nigra, the exiting fibers of the oculomotor nerve and, in some cases, anterior areas of the red nucleus.



# Laboratory Exercise #11 Part A:

## The Limbic System

Lecturer: Terry Crow, Ph.D.

April 24, 2012 1:00 PM

### Required Reading

---

- Nolte, pp. 594-605, Limbic System
- Nolte, pp. 580-594, Hypothalamus

### Introduction

---

Before examining the general anatomy of the limbic system, it is important to note that the use of the term limbic system is a designation used for descriptive purposes only. It is difficult, if not impossible, to find anatomical or physiological justification for lumping a diverse, multifunctional collection of cortical areas and subcortical structures together as the limbic system. Historically, the term “limbic system” derives from the concept of a “limbic lobe” that was presented by the French anatomist Broca. The word limbic refers to a border or fringe. Thus, the term was used to designate neural tissue that surrounds the brain stem and also lies beneath the neocortex. Functionally, structures of the limbic system are important in mediating emotional expression and behavior, and have been implicated in learning and memory in many animals including human. One limbic structure, the hippocampus, is particularly important clinically because it can be the primary focus for the generation of abnormal electrical discharges associated with epilepsy. Since the intrinsic neural circuitry of the hippocampus is known in considerable detail, the structure has also been used as a general model to study synaptic plasticity.

At the end of today's exercise you should be able to:

1. Identify the major and related structures of the limbic system.
2. Describe the relationship between these structures.
3. Describe the general functions of these structures.

- **Part A**

#### **Examination Of Wet Human Brain Material**

1. Your human specimens
2. Demonstration material presented by teaching assistants

- **Part B**

#### **Complete Exercise Mode Of Laboratory #11 Of Neurolab**

1. Each student should go through the NeuroLab computer program review mode prior to the laboratory

- **Part C**

#### **An Exercise At The End Of The Laboratory (~3:30 P.M.) To Assess Your Learning Progress**

- **Part D**

#### **Post-Laboratory Review Using Clinical Cases**

## Materials

---

You will work with the hemisected brain in learning the cortical areas associated with the limbic system and in reviewing the external landmarks of the hypothalamus. You will also work with the horizontal brain slices in tracing the course of the major limbic fiber tracts. Arrange to share these with the student groups, which possess only the coronal brain slices. the DeArmond figures # 4, 6, 9, 12, 13, 14, 15, 16, 58, 64, 65, 67, 68, 70, 71, and the Nolte figures # 23-15, 23-16, 23-18, 23-20, 23-21, 23-22, 25-2 should be used in this exercise. As in all previous exercises, you are expected to be able to both identify the names and locations and know the connections and general functions of the structures.

- Brain specimen bucket containing
  - Brain sections
  - Hemisected brain specimen
- Aluminum pan
- Squeeze bottles with water or bleach
- Cleanup towels for any dripping or spillage

### *You need to bring:*

- Gloves
- Dissection kit
- You may want to bring an plastic apron to protect your clothes.

Identify the following on the hemisected brain, hippocampal dissection and brain sections:

- Subcallosal Gyrus
- Cingulate Gyrus
- Rostrum of the Corpus Callosum
- Splenium of the Corpus Callosum
- Parahippocampal Gyrus
- Hippocampal Formation
- Fornix, Fimbria
- Stria Terminalis
- Anterior Thalamic Nuclei
- Septum Pellucidum
- Alveus
- Stria Medullaris Thalami
- Habenula
- Anterior Commissure
- Mammillary Bodies
- Hypothalamic Sulcus

## The Components Of The Limbic System

---

The cortical areas of the limbic system include the subcallosal, cingulate, parahippocampal gyri, and the hippocampal formation. The major nuclei include the septal nuclei & amygdala,

parts of the hypothalamus (especially the mammillary bodies), thalamus (especially the anterior & dorsomedial nuclei), and parts of the brain stem reticular formation. The major fiber tracts include the fornix, mammillothalamic tract & stria terminalis. Other “tracts” which are more difficult to visualize include the mammillotegmental tract, median forebrain bundle & ventral amygdalofugal pathway. Related structures include those nearby, e.g., the nucleus accumbens septi & the substantia innominata, and those receiving output from the limbic system, e.g., the habenula via the stria medullaris thalami.

## The Major Subcortical Limbic Structures

---

The hippocampal formation is that part of the temporal cortex which lies deep on the medial surface of the temporal lobe. It forms the floor of the temporal horn and extends from the caudal border of the amygdala to the caudal end of the corpus callosum. The hippocampus got its name from its resemblance to a seahorse. (Gr. hippocampus, seahorse). The axons of the hippocampal formation collect along its superior surface to form the alveus. The fibers of the alveus converge on the medial edge of the hippocampal formation to form the fimbria of the fornix. The fimbria is the initial portion of the fornix. The fibers of the fornix take a looping course (Nolte, Fig. 23-20, pg.600) that is best visualized in the gross specimen that will be presented in the laboratory.

The hippocampal formation is considered to be important for the transfer of recently acquired information (memory) into a more enduring form (long-term memory). It receives input from the entorhinal cortex of the parahippocampal gyrus, septal nuclei, & hypothalamus (Figure 11-1 of this exercise). The input from the entorhinal cortex “relays” information from the olfactory system, cingulate gyrus, orbital cortex, amygdala & temporal cortex. The fornix is the major efferent tract of the hippocampal formation. It travels from the hippocampal formation to the septal nuclei, preoptic hypothalamic areas, anterior (A) thalamic nucleus & mammillary bodies. The pathway involving the hippocampal formation and septal nuclei is a cholinergic pathway.

It is important clinically because it has been suggested that alterations in this pathway may be associated with Alzheimer’s disease. The hippocampal pathway to the anterior thalamic nucleus and mammillary bodies involves the hippocampal formation in a neural “circuit” proposed by James Papez to be important in emotional feeling and expression (Figure 11-1). However, more recent anatomical evidence suggests that the original proposal is an oversimplification of limbic connections. The anterior thalamic nucleus gives off thalamocortical projection fibers, which pass via the anterior limb of the internal capsule to the cingulate gyrus. From the cingulate gyrus, axons pass into the cingulum. The fibers of the cingulum project into the temporal lobe and terminate mainly in the cortex of the parahippocampal gyrus. From the parahippocampal gyrus fibers make synaptic connections in the hippocampal formation. This circuit, fornix, mammillothalamic tract, cingulum is historically known as Papez’s circuit (pronounced papists).

The amygdala is one of the regions in the brain that is involved in emotional experiences, especially rage. Through poorly defined pathways the amygdala receives gustatory and viscerosensory information from diencephalic and brain stem structures (See Figure 11-2 of this exercise). It also receives olfactory tract fibers and fibers from frontal and temporal cortical areas. Its major efferent tracts are the stria terminalis and the diffuse ventral amygdalofugal pathway. Most of the fibers in the stria terminalis end in the septal nuclei & anterior hypothalamus. The fibers of the ventral amygdalofugal pathway are distributed to orbital & cingulate cortex, septal area, anterior olfactory nucleus, nucleus accumbens and to the dorsomedial (DM) thalamic nucleus (Nolte, Fig. 23-20, pg.600).

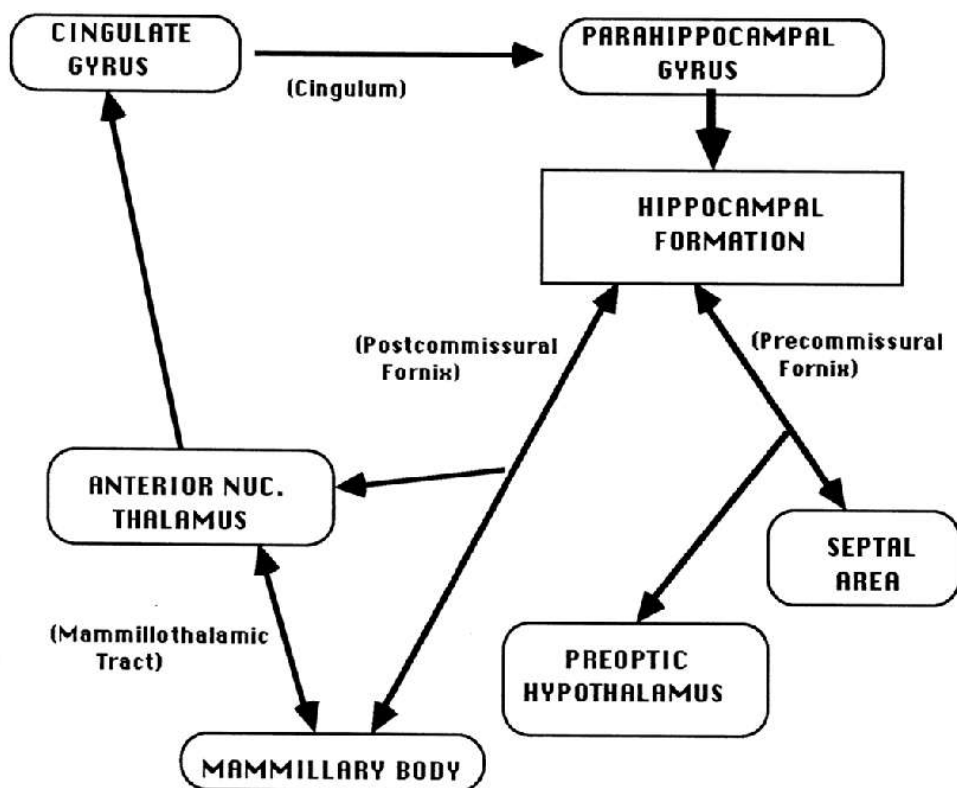


FIGURE 11-1. Connections of hippocampus with limbic structures

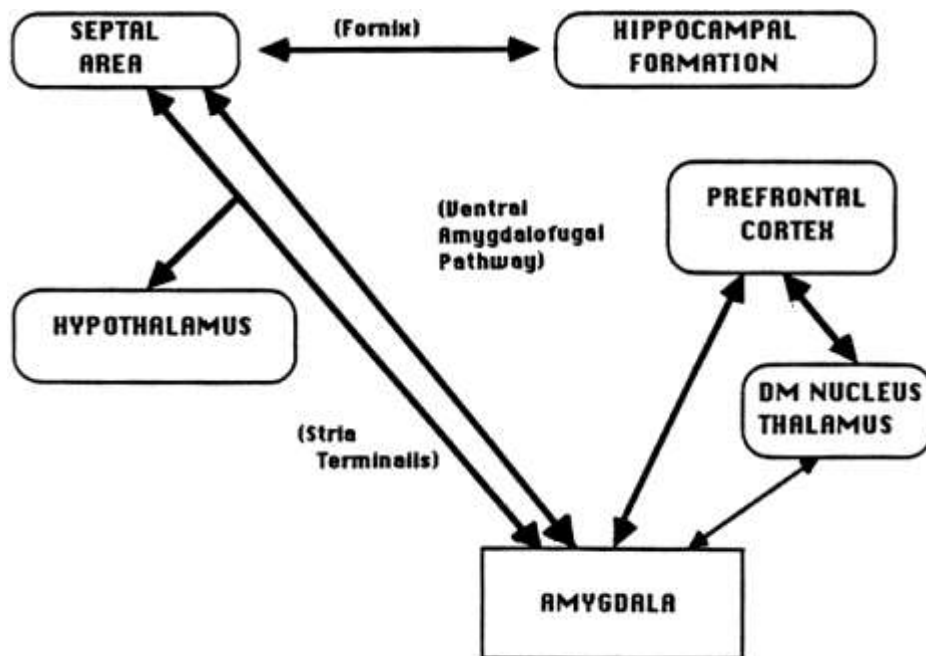


FIGURE 11-2. Some connections of the amygdala.

## Review Questions: Part A

11-A1. A single lesion that interrupts axons of the fornix, stria terminalis and stria medullaris Thalami would involve the

- A. roof of the third ventricle
- B. floor of the third ventricle
- C. genu of the corpus callosum
- D. midregion of the anterior commissure
- E. habenula

11-A2. See the caption below Figure 11-3.

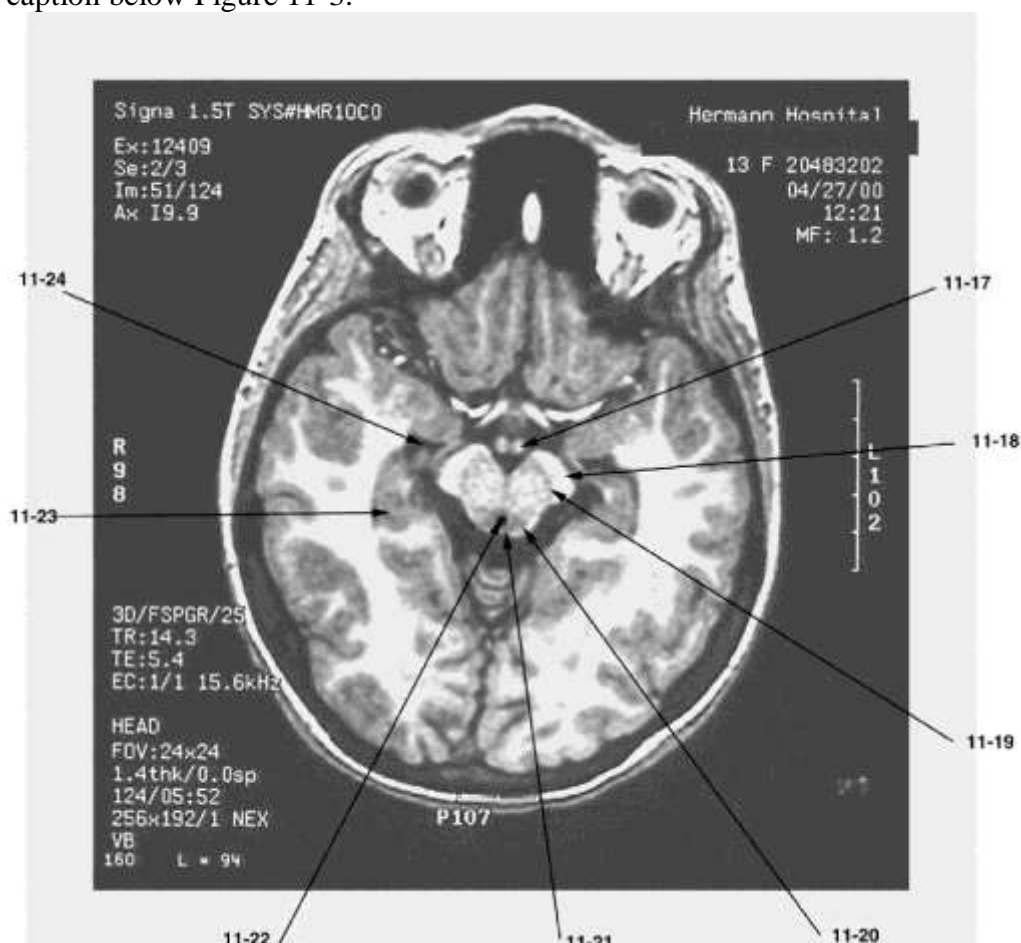


Figure 11-3: MRI horizontal section. Use the DeArmond Atlas Fig. 10 (pp. 20-21), and identify the structures at the tip of the pointers.

## Answers: Part A

11-A1. D

11-A2. For Figure 11-3 above, use DeArmond Atlas fig. 10 (pp. 20-21) to identify structures 11-17 through 11-24.

# Laboratory Exercise #11 Part B: The Hypothalamus

Lecturer: Patrick Dougherty, Ph.D.

April 24, 2012 1:00 PM

## Required Reading

---

- Nolte, pp. 580-607
- Labeled Slides on the Web, #22-26

## Introduction

---

The purpose of this exercise is to identify and learn the:

1. Regions of the hypothalamus.
2. Nuclei within regions of the hypothalamus.
3. Main pathways which interconnect the hypothalamus with other brain regions.

- **Part A**  
**Examination Of Wet Human Brain Material**
  1. Your human specimens
  2. Demonstration material presented by teaching assistants
- **Part B**  
**Complete Exercise Mode Of Laboratory #11 Of Neurolab**
  1. Each student should go through the NeuroLab computer program review mode prior to the laboratory.
- **Part C**  
**An Exercise At The End Of The Laboratory (~3:30 P.M.) To Assess Your Learning Progress**
- **Part D**  
**Post-Laboratory Review Using Clinical Cases**

## Materials

---

You will work with the whole brain, half brain and sectioned brain to review the external landmarks of the hypothalamus.

- Brain specimen bucket containing
  - Whole Brain
  - Hemisected brain specimen
  - Sectioned Brain
- Aluminum pan
- Squeeze bottles with water or bleach
- Cleanup towels for any dripping or spillage



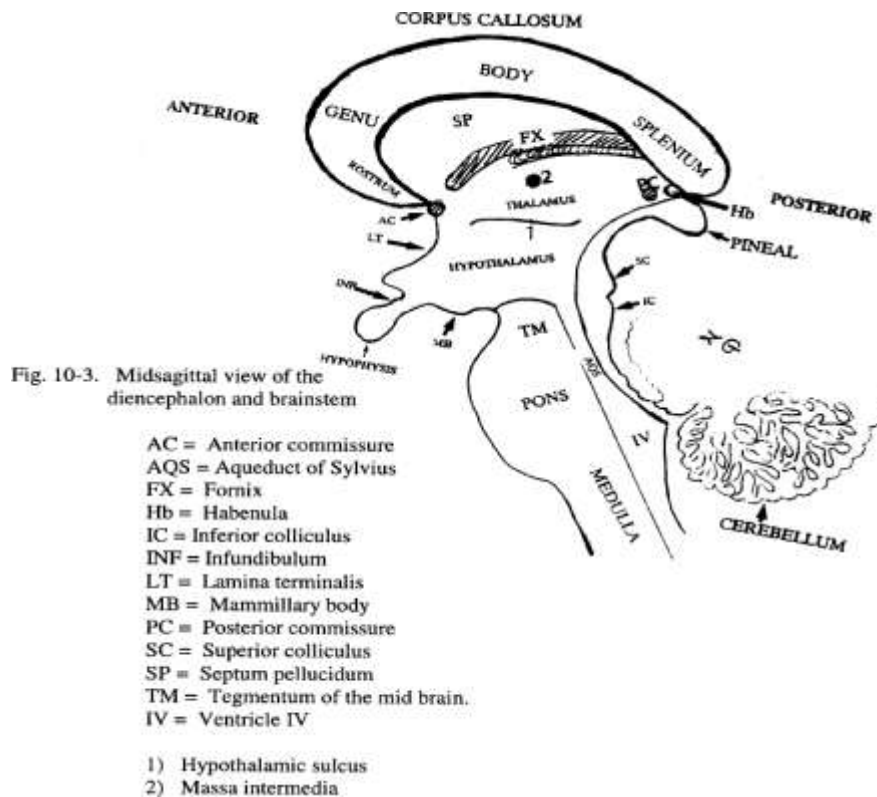
***You need to bring:***

- Gloves
- Dissection kit
- You may want to bring an plastic apron to protect your clothes.

**Wet Specimen Structure Identification**

---

- Whole Brain
  - Optic Chiasm
  - Median Eminence
  - Tuber Cinereum
  - Infundibulum
  - Mammillary Bodies
- Half-Brain
  - Hypothalamic Sulcus
  - Anterior Commissure
  - Lamina Terminalis
  - Optic Chiasm
  - Median Eminence
  - Tuber Cinereum
  - Mammillary Bodies
  - Fornix
- Sectioned Forebrain
  - Internal Capsule
  - Fornix
  - Optic Chiasm
  - Anterior Commissure
  - Mammillary Bodies



## The Hypothalamus

Identify the location of the following structures

- Anterior region
- Tuberal region/Medial basal region
- Posterior region
- Preoptic nucleus
- Suprachiasmatic nucleus
- Supraoptic nucleus
- Anterior nucleus
- Paraventricular nucleus
- Arcuate nucleus
- Dorsomedial nucleus
- Ventromedial nucleus
- Mammillary nucleus
- Mammillary body
- Mammillothalamic tract
- Lamina terminalis
- Hypothalamic sulcus
- Median eminence
- Infundibulum
- Anterior commissure
- Postcommissural fornix

## Review Questions: Part B

---

Give the best answer(s):

- 11-B1. The supraoptic nucleus is involved in
- A. thermoregulation
  - B. synthesizing vasopressin
  - C. controlling feeding "satiety center"
  - D. controlling generalized sympathetic responses
  - E. synthesizing oxytocin
- 11-B2. The ventromedial hypothalamic nucleus is involved in:
- A. thermoregulation
  - B. synthesizing vasopressin
  - C. controlling feeding behavior "satiety center"
  - D. controlling generalized sympathetic responses
  - E. synthesizing oxytocin
- 11-B3. The preoptic region is involved in:
- A. thermoregulation
  - B. synthesizing vasopressin
  - C. controlling feeding behavior "satiety center"
  - D. controlling generalized sympathetic responses
  - E. synthesizing oxytocin
- 11-B4. The paraventricular nucleus has been implicated in:
- A. thermoregulation
  - B. synthesizing vasopressin
  - C. controlling feeding behavior "satiety center"
  - D. controlling generalized sympathetic responses
  - E. synthesizing oxytocin
- 11-B5 A cystic enlargement pressing on the supraoptic nucleus might disrupt:
- A. water balance
  - B. heart rate
  - C. vision
  - D. food intake
  - E. all of the above
- 11-B6. The lateral area in the hypothalamus receives extra hypothalamic input primarily from:
- A. medial forebrain bundle
  - B. precommissural fornix
  - C. stria terminalis
  - D. stria medullaris thalami
  - E. cingulum

**Answers: Part B**

---

- 11-B1. B & E
- 11-B2. C
- 11-B3. A
- 11-B4. B, D & E
- 11-B5. A & C
- 11-B6. A